

RECOMMENDATIONS

Future studies should include histological studies for a better understanding of the maxillary sinus and anatomy. Evaluation of the advanced CBCT techniques such as computer assisted implant surgery studies should be done.

BIBLIOGRAPHY

Abrahams, J.J., Hayt, M.W., Rock, R., (2000). Sinus lift procedure of the maxilla in patients with inadequate bone for dental implants: radiographic appearance. *Am J Roentgenol*, May; 174(5):1289-92.

Ardekian, L., Mactei, E., (2006). The clinical significance of sinus membrane perforation during augmentation of the Maxillary Sinus. *J Oral Maxillofac Surg*; 64: 277-282

Arora, S., Kau, R., Lamba, A., Faraz, F., Tandon, A., Ahad, A., (2013). Role of Cone Beam Computed Tomography in Rehabilitation of a Traumatized Deficient Maxillary Alveolar Ridge Using Symphyseal Block Graft Placement. *Case Reports in Dentistry* Article ID 7488405

Beretta, M., Cicciu, M., Bramanti, E., Maiorana, C., (2012). Schneiderian Membrane Elevation in Presence of Sinus Septa: Anatomic Features and Surgical Management. *International Journal of Dentistry*; doi: 10.1155/ 261905

Elian, N., Wallace, S. (2005). Distribution of the maxillary artery in relation to sinus floor augmentation. *Int J Oral Maxillofac Imp*; 20: 784-787

Flanagan, D., (2005). Arterial supply of the maxillary sinus and potential bleeding. *Implant Dent*; 14(4): 336-8

Georgescu, C., Mihai, A., Didilescu, A., Moraru, R., Nimegean, V.R., Nimegean, V., Tanase, G., (2010). Cone beam computed tomography as a method of quantitative analysis of alveolar

crest in the frontal mandibular area. *Romanian Journal of Morphology & Embryology*; 51(4): 713-717

Gosau, M., Rink, D., Driemal, O, Draenert, F.G., (2009). Maxillary Sinus Anatomy: A Cadaveric Study with Clinical Implications. *The Anatomical Record*, 292:352-354

Guncu, G., Yildirim, Y., Wang, H., Tozum, T., (2011). Location of posterior superior alveolar artery and evaluation of maxillary sinus anatomy with computerized tomography: a clinical study. *Clin Oral Impl.Res*:22; 1164-1167

Hu, K., Choi, D., Lee, W., Kim, H., Jung, U., Kim, S., (2012). Reliability of two different presurgical preparation methods for implant dentistry based on panoramic radiography and cone-beam computed tomography in cadavers. *J Periodontal Implant Sci*; 42: 39-44

Janner, S., Caversaccio, M., Dubach, P., Sendi, P., Buser, D., Bornstein, M., (2011). Characteristics and dimensions of the Schneiderian membrane: a radiographic analysis using cone beam computed tomography in patients referred for dental implant surgery in the posterior maxilla. *Clin Oral Impl Res*; 22: 1446-1453

Kim, J.K., Cho, J.H., Lee, Y.J., (2010). Anatomical Variability of the Maxillary Artery. *Arch Otolaryngol Head Neck Surg*, 136(8):813-818

Krennmair, G., (1999). The incidence, location, and height of maxillary sinus septa in the edentulous and dentate maxilla. *J Oral Maxillofac Surg* ;57:667-7

Lana J., Rodrigues, P., Machodo, V., Souza, P., Manzi, F., (2011). Anatomic Variations and lesions of the maxillary sinus detected in cone beam computed tomography for dental implants. *Clin Oral Implants* (23):1398-140

Lawson, W., Patel, Z., Lin, F., (2008). The Development and Pathologic Processes that Influence Maxillary Sinus Pneumatization. *The Anatomical Record*; 291: 1554-1563

Lee, W., Lee, S., Kim, H., (2010). Analysis of location and prevalence of maxillary sinus septa. *J Periodontal Implant*; 40: 56-60

Mardinger, O., Abba, M., Hirshenberg, A., Schwartz-Arad, D., (2007). Prevalence, diameter and course of the maxillary intraosseous vascular canal with relation to sinus augmentation procedure: a radiographic study. *Int J Oral Maxillofac Surg*;36(8):735-8.

Meleo, D., Mangione, F., Corbi, S., Pacifico, L., (2012). Management of the Scheiderian membrane perforation during the maxillary sinus elevation procedure: a case report. *Annali di Stomatologia*; III (I):24- 30

Mohan, R., Singh, A., Gundappa, A., (2011). Three-dimensional Imaging in periodontal diagnosis-Utilization of cone-beam computed tomography. *J Indian Soc Periodontal*, Jan-Mar: 15 ;(1):11-17

Neugebauer, J., (2010). Evaluation of Maxillary Sinus Anatomy by Cone-beam CT prior to sinus floor elevation. *Int J Oral Maxillofac*; 25: 258-265

Nimegean, V., Maru, N., Badita, D., (2008). The maxillary sinus floor in the oral implantology. *Romania Journal of Morphology and Embryology*, 49(4)485-489.

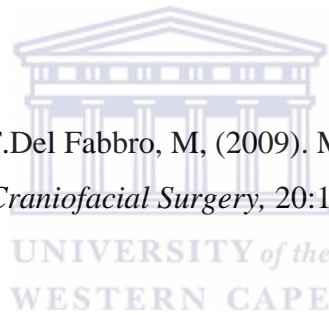
Otake, I., Kageyama, L., Mataga, L., (2010). Clinical Anatomy of the Maxillary Artery. *Okajimas Folia Anat Jpn*, 87(4): 155-164.

Park, W., Choi, S., Kim C., (2012). Study on the position of the posterior superior alveolar artery in relation to the performance of the maxillary sinus bone graft procedure in a Korean Population. *J Korean Assoc Oral Maxillofac Surg*; 38: 71-77

Pompa, V., Galasso, S., Cassetta, M., Pompa, G., De Angelis, F., Di Carlo, S., (2010). A Comparative study of the Magnetic Resonance and Computed Tomography in the pre-implant evaluation. *Annali di Stomatologia*; 3: 33-38

Rege, I., Sousa, T., Leles, C., Medonca, E., (2012). Occurrence of Maxillary sinus abnormalities detected by cone beam CT in asymptomatic patients. *BMC Oral Health*; 12:30

Rosano, G., Taschieir. Gaudy J, F.Del Fabbro, M, (2009). Maxillary Sinus Vascularization: A cadaveric Study. *The Journal of Craniofacial Surgery*, 20:1-4.



Rosano, G., Taschieir, S., Gaudy J, F.Del Fabbro, M, (2011).Maxillary sinus vascular anatomy and its relation to sinus lift surgery. *Clin Oral Impl Res*, 22; 711-715.

Sato, I., Kawai, T., Yoshida, S.I., Miwa, Y., Imura, K., Sunohara, M., Yosue, T., (2010). Observing the bony canal structure of the human maxillary sinus in Japanese cadavers using cone beam CT. *Okajimas Folia Anat Jpn*, Nov; 87(3):123-8.

Serkerçi, A., Sisman, Y., Etoz, M., Bulut , D., (2013). Aberrant Anatomical Variation of Maxillary sinus Mimicking Periapical Cyst: A report of two cases and Role of CBCT in diagnosis. *Case Reports in Dentistry*; doi: 10.1155/757645

Sekine, H., Taguchi, T., Seta, S., Takano, M., Takeda, T., Kakizawa, T., (2006). Dental Implant Treatment with Different Techniques for Sinus Floor Elevation- A Case Report. *Bull Tokyo Dent Coll*; 48(2): 87-91

Solar, P., Geyerhofer, U., Traxler, H., Windisch, A., Ulm, C., Watzek, G.,(1999). Blood Supply to the Maxillary Sinus relevant floor elevation. *Clinical Oral Implant Res*; 10(1): 34-44

Testori, T., (2013). Maxillary sinus surgery: Anatomy and advanced diagnostic imaging. *International Dentistry African Edition*; 2(5):6-15

Testori, T., (2012). Prevention and Treatment of Postoperative Infections after sinus elevation Surgery: Clinical Consensus and Recommendations. *International Journal of Dentistry*; doi: 10.1155/365809



Toffler, M., (2009). Short Implants: A Viable Treatment Option in the Anatomically Challenged” Patient. *Inside Dentistry* January

Ulm, C.W., Solar, P., Krennmair, G., Matejka, M., Watzek, G.,(1995). Incidence and suggested surgical management of septa in sinus-lift procedures. *Int J Oral Maxillofac Implants*; 10:462–465

Underwood, A.S., (1910). An inquiry into the anatomy and pathology of the maxillary sinus. *J Anat Physiol*; 44:354-369.

Woo, I., (2004). Maxillary Sinus Elevation: Review of Anatomy and two techniques. *Implant Dentistry*; 13(1): 28-32

Yoshida, S., Kawai, T., Asaumi, R., Miwa, Y., Imura, K., Koseki, H., Sunohara M., Yosue, T., Sato, I., (2010). Evaluation of the blood and nerve supply patterns in the molar region of the maxillary sinus in Japanese cadavers. *Okajimas Folia Anat Jpn*, 87(3); 129-33

