

**MALIGNANT TUMOURS OF THE
MAXILLOFACIAL AND ORAL REGION IN CHILDREN:
A CLINICOPATHOLOGIC STUDY**



UNIVERSITY of the
WESTERN CAPE
ASHRAF MOHAMED

047422 W



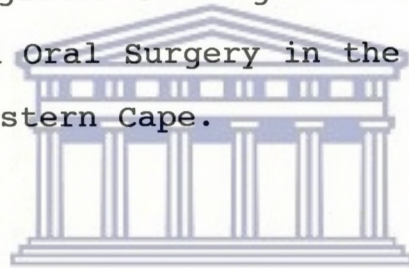THE
UNIVERSITEIT VAN WES-KAAPLAND
BIBLIOTEEK
617.5209687MOH
LIBRARY
UNIVERSITY OF THE WESTERN CAPE

MALIGNANT TUMOURS OF THE MAXILLOFACIAL
AND ORAL REGION IN CHILDREN:
A CLINICOPATHOLOGIC STUDY

by

ASHRAF MOHAMED

Dissertation submitted in partial fulfilment of the requirements
for the degree of Magister Chirurgiae Dentium in the discipline
of Maxillofacial and Oral Surgery in the Faculty of Dentistry,
University of the Western Cape.




UNIVERSITY *of the*
WESTERN CAPE

UNIVERSITY OF THE WESTERN CAPE

DATE OF SUBMISSION: April 1994

DECLARATION

I, declare that this dissertation entitled "Malignant tumours of the maxillofacial and oral region in children: A clinicopathologic study" is my own work and that all sources I have quoted have been indicated and acknowledged by means of references.



Signed:

UNIVERSITY *of the*
WESTERN CAPE

ACKNOWLEDGEMENTS

I wish to acknowledge my sincere gratitude to the following individuals for their assistance in this research project.

1. Miss Fionna Faroon for her kind assistance and proficiency with the word-processing and for her patience and forbearance.
2. Dr. Gilmie Kariem and Dr. Jos J. Hille, my promoters, for their guidance and assistance in making this study possible.
3. Dr. Patricia Hartley (Department of Heamatology, Red Cross War Memorial Children's Hospital) and Dr. Clare Stannard (Department of Oncology, Groote Schuur Hospital), for allowing me to make use of their clinical material.
4. Professor C.D. Karabus (Department of Pathology, Red Cross War Memorial Children's Hospital), for giving me access to the histopathologic material used in this study.
5. Special thanks to Professor Mervyn Shear, for his assistance in reviewing the histopathologic data.
6. Dr. Ruwaida Tootla, for her invaluable assistance with the presentation of the graphs.
7. Dr. Ratilal Lalloo, for his assistance with the processing of the data and the statistics.
8. I am indebted to the many patients who made this study possible.

DEDICATION

This dissertation is dedicated to my parents, whose sacrifices and love have made my education possible, and to my sister for her support and encouragement.



UNIVERSITY *of the*
WESTERN CAPE

ABSTRACT

This is a retrospective study of malignant tumours of the maxillofacial and oral region in children that presented over a 20 year period (1973 to 1993) at the Red Cross War Memorial Children's Hospital and Groote Schuur Hospital, Cape Town.

Of the 352 children that were treated for a malignant tumour arising from various anatomic sites in the head and neck region, 30 were found to have had maxillofacial and oral involvement. This represented an incidence of 8,5%. Histologically, the majority of the tumours were non-odontogenic and mesenchymal in origin. The rhabdomyosarcoma was found to be the most common neoplasm, followed by the Burkitt's lymphoma. The age range was 6 months to 13.8 years (mean age 5.7 years). Males were more commonly affected than females, with a ratio of 1.3:1. There were 26 (86,7%) black patients and 4 (13,3%) white patients, representing a ratio of 6.5:1. Fifty percent of the cases were from the Eastern Cape.

The mandible and the maxilla were the most common sites to be involved, followed by the soft tissues of the face. The most common presenting symptom was a painless swelling (73,3%) of the face. Twenty percent of the patients had "floating" or loose teeth. Radiographic features in the jaws were poorly circumscribed destructive lytic lesions with displacement of teeth. Histologic type was found to be the most significant variable affecting the outcome, with the Burkitt's lymphomas having the best prognosis and the rhabdomyosarcomas the worst. The

most common cause of death was metastases to the lungs.

It is concluded that although malignant tumours of the maxillofacial and oral region in children are rare, their prognosis is poor. Therefore, any child presenting with a facial swelling should be viewed with suspicion.



UNIVERSITY *of the*
WESTERN CAPE

ABSTRAK

Hierdie is 'n retrospektiewe studie van maligne tumore van die kaak-gesig en mondgebied in kinders, wat oor 'n periode van 20 jaar (1973-1993) by Rooikruis Kinderhospitaal en Groote Schuur Hospitaal presenteer het.

Van die 352 kinders wat behandel is vir 'n maligne tumor wat ontstaan het van verskeie anatomiese areas in die kop en nek gebied, was gevind dat 30 die kaak-gesig en mond area betrek het. Dit verteenwoordig 'n insidensie van 8,5%. Histologies was die meerderheid van die tumore non-odontogeen en mesengiemaal in oorsprong. Die rhabdomiosarkoom het die mees algemeen voorgekom, gevolg deur die Burkitts limfoom. Die ouderdom reeks het van 6 maande tot 13.8 jaar gestrek (gemiddeld 5.7 jaar). Die manlike geslag is meer algemeen aangetas in vergelyking met die vroulike geslag, met 'n verhouding van 1.3:1. Ses-en-twintig van die pasiënte was swart (86,7%) en 4 was blank (13,3%) wat 'n verhouding van 6.5:1 verteenwoordig. Vyftig persent van die gevalle was van die Oos-Kaap.

Die mandibel en maksilla was die areas wat mees algemeen aangetas was, gevolg deur die sagte weefsel van die gesig. Die mees algemene presenterende simptome was 'n pynlose geswel van die gesig (73,3%). Twintig persent van die pasiënte het los of "floating" tande gehad. Die radiologiese kenmerk in die kake was sleg omskryfde been vernietegende letsels met verplasing van tande. Die mees kenmerkende faktor wat die algehele uitslag affekteer het, was die histologiese tipe van die tumor, met die

beste prognosis in Burkitts limfoom, en die slegste in die rhabdomiosarkoom. Die mees algemene oorsaak van dood was uitsaaing na die longe.

Ten slotte, alhoewel maligne tumore van die kaak-gesig en mondgebied skaars is, is hul prognose sleg. Daarom moet elke kind wat met 'n swelsel van die gesig presenteer, met agterdog ondersoek word.



UNIVERSITY *of the*
WESTERN CAPE

TABLE OF CONTENTS

	PAGE NO.
Title	i
Declaration	ii
Acknowledgements	iii
Dedication	iv
Abstract	v
Abstrak	vii
Table of contents	ix
List of tables	xiv
List of figures	xv
1. INTRODUCTION	1
1.1 Background	2
1.2 Definition of terms	4
2. REVIEW OF LITERATURE	7
2.1 Malignant childhood tumours in general	8
2.2 Malignant tumours of the maxillofacial and oral region in children in general	9
2.3 Rhabdomyosarcomas of the maxillofacial and oral region in children	14
2.3.1 Definition	14
2.3.2 Historical background	15
2.3.3 Review of literature: Rhabdomyosarcomas	16
2.3.3.1 Aetiology	25
2.3.3.2 Pathogenesis	26
2.3.3.3 Histologic classification	27
2.3.3.4 Age and gender distribution	30
2.3.3.5 Anatomical site	31

2.4	Burkitt's lymphoma	32
2.4.1	Definition	32
2.4.2	Historical background	33
2.4.3	Review of literature: Burkitt's lymphoma	35
2.4.3.1	Burkitt's lymphoma in South Africa	37
2.4.3.2	Burkitt's lymphoma outside Africa	38
2.4.3.3	Pathogenesis of jaw lesions	40
2.4.3.4	Signs and symptoms	41
2.4.3.5	Radiographic features	42
2.5	Objectives of present study	43
3.	MATERIALS AND METHODS	44
3.1	Introduction	45
3.2	Identification of study sample	45
3.3	Collection of data	45
3.3.1	Clinical data	45
3.3.2	Radiographic data	46
3.3.3	Histopathologic data	46
3.4	Pilot study	47
3.5	Data analysis	47
4.	RESULTS	49
4.1	Analysis of entire series	51
4.1.1	Incidence	51
4.1.2	Histopathology	52
4.1.3	Age	52
4.1.4	Gender	54
4.1.5	Race	54
4.1.6	Geographic distribution	54
4.1.7	Anatomical site of lesion	56

4.1.8	Signs and Symptoms	58
4.1.9	Duration of symptoms	61
4.1.10	Radiographic features	61
4.1.11	Treatment	65
4.1.12	Survival	67
4.2	Analysis of rhabdomyosarcoma series	69
4.2.1	Distribution of head and neck cases	69
4.2.2	Age, Gender and race	70
4.2.3	Geographic distribution	71
4.2.4	Clinical stage	71
4.2.5	Anatomical site of lesion	71
4.2.6	Signs and Symptoms	72
4.2.7	Duration of symptoms	73
4.2.8	Cervical lymph node involvement and metastases	73
4.2.9	Histopathology	74
4.2.10	Radiographic features	75
4.2.11	Treatment	75
4.2.12	Survival	76
4.3	Analysis of Burkitt's lymphoma series	76
4.3.1	Incidence	76
4.3.2	Age, gender and race	76
4.3.3	Geographic distribution	78
4.3.4	Seasonal pattern	78
4.3.5	Anatomical site of lesion	78
4.3.6	Signs and Symptoms	78
4.3.7	Duration of symptoms	78
4.3.8	Histopathology	79

4.3.9	Immunocytochemistry	79
4.3.10	Radiographic features	79
4.3.11	Treatment	79
4.3.12	Survival	80
5.	DISCUSSION	81
5.1	Discussion on entire series	83
5.1.1	Incidence	83
5.1.2	Histopathology	83
5.1.3	Age, gender and race	84
5.1.4	Geographic distribution	87
5.1.5	Anatomical site of lesion	87
5.1.6	Signs and Symptoms	91
5.1.7	Duration of symptoms	94
5.1.8	Radiographic features	94
5.1.9	Treatment	98
5.1.10	Survival	98
5.2	Discussion: Rhabdomyosarcomas	99
5.2.1	Aetiology	99
5.2.2	Histopathologic features	100
5.2.3	Age	103
5.2.4	Gender	104
5.2.5	Race	104
5.2.6	Geographic distribution	105
5.2.7	Anatomical site of lesion	106
5.2.8	Signs and symptoms	108
5.2.9	Duration of symptoms	108
5.2.10	Clinical stage	109
5.2.11	Radiographic features	109

5.2.12	Treatment	110
5.2.13	Survival	110
5.3	Discussion: Burkitt's lymphoma	111
5.3.1	Age	111
5.3.2	Gender	111
5.3.3	Race	111
5.3.4	Geographic distribution	112
5.3.5	Anatomical site of lesion	112
5.3.6	Signs and symptoms	113
5.3.7	Duration of symptoms	113
5.3.8	Histopathologic features	113
5.3.9	Radiographic features	116
5.3.10	Treatment	116
5.3.11	Survival	118
6.	CONCLUSIONS	119
6.1	Maxillofacial and oral tumours in general	120
6.2	Rhabdomyosarcomas	122
6.3	Burkitt's lymphoma	123
6.4	Criticism of study	124
7.	RECOMMENDATIONS	125
8.	APPENDICES	126
	Appendix I - Proforma for the collection of clinical data	127
	Appendix II - Letter sent to institutions concerned	129
9.	REFERENCES	130

LIST OF TABLES

	PAGE NO.
Table 1: Summary of literature review	17
Table 2: Clinical grouping classification (IRS)	22
Table 3: Rhabdomyosarcoma special stains	47
Table 4: Histiologic types of paediatric malignancies	52
Table 5: Age distribution	53
Table 6: Gender distribution	54
Table 7: Racial distribution	55
Table 8: Site distribution	57
Table 9: Clinical presentation of malignant paediatric maxillofacial and oral tumours	60
Table 10: Duration of symptoms	61
Table 11: Radiographic findings	63
Table 12: Treatment	66
Table 13: Chemotherapeutic agents	66
Table 14: Result of treatment	68
Table 15: Geographic distribution	71
Table 16: Clinical stage - rhabdomyosarcoma	71
Table 17: Anatomical site - rhabdomyosarcoma	72
Table 18: Radiographic features of rhabdomyosarcoma	75

LIST OF FIGURES

	PAGE NO.
Figure 1: IRS treatment protocol	24
Figure 2: Cook's description of a "sarcoma of the jaw"	34
Figure 3: Incidence of maxillofacial and oral tumours (1973-1993)	51
Figure 4: Age distribution	53
Figure 5: Racial distribution	55
Figure 6: Geographic distribution	56
Figure 7: Clinical presentation (primary complaints)	59
Figure 8: Anatomic site (seen radiographically)	64
Figure 9: Result of treatment	68
Figure 10: Distribution of head and neck rhabdomyosarcomas	69
Figure 11: Age distribution (rhabdomyosarcomas)	70
Figure 12: Distribution by histologic type (rhabdomyosarcomas)	74
Figure 13: Age distribution (Burkitt's lymphoma)	77
Figure 14: Malignant fibrous histiocytoma	85
Figure 15: Low-grade mucoepidermoid carcinoma	85
Figure 16: Rhabdomyosarcoma of the maxillary sinus	92
Figure 17: Leiomyosarcoma of the tongue	92
Figure 18: Acute myeloid leukaemia of the mandible	95
Figure 19: Burkitt's lymphoma of the mandible (multiple radiolucent lesions)	96
Figure 20: Embryonal rhabdomyosarcoma	102
Figure 21: Burkitt's lymphoma ("starry-sky")	115
Figure 22: Burkitt's lymphoma of the mandible (teeth "floating" in space)	117

INTRODUCTION

- 1.1 Background**
- 1.2 Definition of terms**



UNIVERSITY *of the*
WESTERN CAPE

1.1 Background

Although cancer is a relatively rare disease in childhood, it kills more children than any other disease, and is second only to accidents as the commonest cause of death between one and fourteen years of age. Its lethal nature, insidious onset, emotional impact on the child and parents, and the increasing prospects of cure makes it one of the most challenging aspects of paediatric practice (Jones and Campbell, 1976).

Screening tests for childhood malignancies are not efficient, and the early warning signs of adult cancer have little relevance in childhood malignant disease. A high index of suspicion is therefore the only key to early diagnosis in the child (Karabus and Hartley, 1987). Delays in investigations and diagnosis makes the prognosis worse, and survival rates in most malignancies can be significantly improved by earlier diagnosis and prompt action.

No other kind of medical condition requires the participation of so many diverse specialities. This includes the family doctor or dentist, who is often the first to be involved, the paediatric oncologist, the histopathologist, and the radiotherapist. The maxillofacial and oral surgeon is included in the team when the tumour affects the oral cavity and surrounding anatomical regions. This surgeon plays his role not only in the surgical management and rehabilitation of these patients, but also and perhaps more important, in the early recognition and diagnosis of these tumours.

Malignant neoplasms of the maxillofacial and oral region in children occur infrequently (Dehner, 1973). Hence, the lack of experience amongst surgeons in dealing with these lesions (Chuong and Kaban, 1985). However, a number of malignant neoplasms have been found to have a special predilection for the maxillofacial and oral region of infants and children. These tumours represent a wide variety of clinical and pathologic entities (Greer and Mierau, 1980).

The successful management of these tumours therefore requires a thorough knowledge of their clinicopathologic features, as well as of the various treatment options available.

The English language literature supplies limited information on malignant tumours of the maxillofacial and oral region in children. Most of the available literature deals mainly with head and neck neoplasms in general, making only brief mention of specific maxillofacial involvement and without giving any details on their clinicopathologic features (Sutow, 1964; Jaffe, 1973; Raney and Handler, 1981). Of the literature dealing specifically with maxillofacial involvement, most authors have concentrated on benign odontogenic and non-odontogenic tumours, with very little attention being paid to the malignant tumours (Bhasker, 1963; Chuong and Kaban, 1985; Asamoia *et al.*, 1990).

Because little effort has been made to determine the clinicopathologic features and behaviour of malignant tumours of the maxillofacial and oral region in children, it is my belief

that a detailed study of these features is needed. The findings hopefully allow for earlier diagnosis and treatment, which ultimately should improve the prognosis. Furthermore, the presence of a maxillofacial malignancy might be the first sign or symptom of a primary malignancy occurring elsewhere in the body (Dehner, 1973).

The purpose of this study, therefore, is to review the clinicopathologic features of a collection of malignant neoplasms diagnosed in the maxillofacial and oral region in children presenting at the Groote Schuur Hospital and Red Cross War Memorial Children's Hospital in Cape Town over a 20 year period.

1.2 Definition of Terms

Some clarification of the use of words in this dissertation is necessary at this point:

"Children" in this study is considered to designate the human young from birth to fifteen years of age.

"Malignant Tumours": Tumours are divided into benign and malignant categories based on their potential clinical behaviour. "Malignant tumour" implies that the tumour can invade and destroy adjacent structures and has the ability to enter channels like the lymphatic and blood vessels and thus is able to spread to distant sites (metastasize) to cause death (Walter and Israel, 1987). Microscopically, malignant tumours tend to show less accurate reproduction of the parent tissue than do their benign

counterparts. Microscopic features of malignant tumours include a marked variation in cell size and shape (pleomorphism), nuclear hyperchromatism, increased nuclear to cytoplasmic ratio, numerous and atypical mitoses (tripolar or quadripolar), loss of polarity of cells, large nucleoli, loss of cellular adhesion, and giant cells (Robbins and Kumar, 1987).

"Maxillofacial and Oral Surgery" is that branch of surgery dealing with the diagnosis and the surgical and adjunctive treatment of diseases, injuries, and defects involving the face and structures of the mouth (Jablonski, 1981).

"Maxillofacial Region" refers to the maxillae (including the maxillary sinus), mandible, palate, zygomatic bones, dento-alveolar structures, temporomandibular joint, facial soft tissues and salivary glands.



"Neoplasm": Willis (1973) defines a neoplasm as "an abnormal mass of tissue, the growth of which exceeds and is uncoordinated with that of the normal tissues and persists in the same excessive manner after cessation of the stimuli which evoked the change."

"Oncology" is derived from the Greek, "oncos" meaning tumour, and "logos" meaning study of. The study and treatment of malignant tumours is therefore called oncology (Robbins and Kumar, 1987).

"Oral Region" refers to the area extending from the lips and cheeks externally, to the anterior pillars of the fauces internally (Berkovitz et al., 1978).

"Survival" is defined as the time lapse from initial diagnosis until death related to the disease.

"Tumour" is derived from the Greek word "Tumor" which means swelling. It may be used to describe any non-neoplastic swelling such as oedema or haemorrhage into a tissue (Robbins and Kumar, 1987). In common medical usage, a neoplasm is often referred to as a tumour. The term tumour in this dissertation is restricted solely to neoplastic masses.



REVIEW OF THE LITERATURE

- 2.1 Malignant childhood tumours in general**
- 2.2 Malignant tumours of the maxillofacial and oral region in children in general**
- 2.3 Rhabdomyosarcomas of the maxillofacial and oral region in children**
 - 2.3.1 Definition**
 - 2.3.2 Historical background**
 - 2.3.3 Review of literature: Rhabdomyosarcomas**
 - 2.3.3.1 Aetiology**
 - 2.3.3.2 Pathogenesis**
 - 2.3.3.3 Histologic classification**
 - 2.3.3.4 Age and gender**
 - 2.3.3.5 Anatomical site**
- 2.4 Burkitt's lymphoma**
 - 2.4.1 Definition**
 - 2.4.2 Historical background**
 - 2.4.3 Review of literature: Burkitt's lymphoma**
 - 2.4.3.1 Burkitt's lymphoma in South Africa**
 - 2.4.3.2 Burkitt's lymphoma outside South Africa**
 - 2.4.3.3 Pathogenesis of jaw lesions**
 - 2.4.3.4 Signs and symptoms**
 - 2.4.3.5 Radiographic features**
- 2.5 Objectives of present study**

2.1 Malignant childhood tumours in general

Historically, malignant tumours of childhood have generally been regarded as lethal. In most early paediatric tumour studies, rapid progression to death following diagnosis, was a frequent observation. It is now believed that the reason for this was that most of these patients had undetected metastatic disease at the time of diagnosis, and local therapy, therefore, was doomed to failure (Hays, 1986).

The spectrum of cancer in childhood is totally different from that seen in adults. Leukaemia is much more common and, histologically, the solid tumours consist of embryonal tumours and sarcomas, rather than carcinomas. Karabus and Hartley (1988) reviewed the diagnoses of 844 children of all races registered at the Red Cross War Memorial Children's Hospital Oncology Centre between 1970 and 1985. Leukaemia, brain tumours, lymphoma, neuroblastoma and Wilm's tumour accounted for over 80% of the total diagnosis. They found that the incidence of malignancy in the first five years of life was greater than in the subsequent ten years, suggesting that prenatal influences are more important in the genesis of paediatric cancer than environmental carcinogens.

Lanzkowsky (1983) found that the leukaemias, Wilm's tumour, neuroblastoma and retinoblastoma had a peak incidence in the first five years of life. Tumours of the central nervous system had a peak incidence in the 5-10 year age group, while the lymphomas and sarcomas of bone showed a peak incidence in the 10-

15 year age group. Similar information on malignant tumours of the maxillofacial and oral region in children is lacking.

2.2 Malignant tumours of the maxillofacial and oral region in children in general

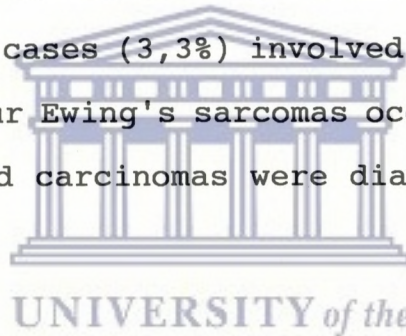
The established English language literature supplies limited information on malignant tumours of the maxillofacial and oral region in children. Most of the reported cases have been described as part of head and neck series. Therefore, in reviewing the literature, an attempt has been made to extract those cases involving the maxillofacial and oral region in children fifteen years and younger, and to analyse them independently of other head and neck tumours.

Tumours of the jaws in children came into prominence as a result of Dennis Burkitt's pioneering work on a tumour which was later to bear his name. Early African carvings suggest that people were aware of jaw involvement long before Burkitt's description in 1958 (Hutt, 1970). Indeed, Sir Albert Cook, on his arrival in Uganda in 1897, noted the high frequency of sarcoma of the jaws in children (Cook, 1901).

Bhasker (1963) reported on a series of 293 cases of oral tumours seen in patients from birth to fourteen years of age. Nine percent of these were found to be malignant neoplasms. These tumours included embryonal rhabdomyosarcomas, osteosarcomas, fibrosarcomas, adenocarcinomas of the salivary glands and primary malignant lymphomas. The most common site for the

rhabdomyosarcomas was the soft palate and cheek, while the lymphomas had a predilection for the gingiva. The most common presenting symptoms of the jaw tumours were loosening and migration of the teeth, dental pain, ulceration of the soft tissues and paraesthesia. The prognosis of these tumours was poor, but because of the small number of malignant cases, Bhasker (1963) was unable to make any definite conclusions.

Sutow (1964) reported on 210 malignant head and neck tumours in children diagnosed between 1946 and 1963. He found that many of the tumours that were common in adults, were rare amongst children. Only seven cases (3,3%) involved the maxillofacial and oral region, viz. four Ewing's sarcomas occurred in the jaws and three muco-epidermoid carcinomas were diagnosed in the parotid gland.



In 1973, Dehner reported on fourteen primary and secondary malignant tumours of the mandible and maxilla in children of age 15 years or less. Of these, five were primary neoplasms, while nine were secondary neoplasms. The primary tumours consisted of osteosarcoma, fibrosarcoma and Ewing's tumour. The secondary tumours included rhabdomyosarcomas, neuroblastomas, Wilm's tumour, retinoblastoma, lymphoblastic leukaemia and undifferentiated round cell sarcoma. Osteosarcoma was the most common primary tumour, while rhabdomyosarcoma was the most common secondary tumour. Children with primary malignant tumours were found to be older at the time of diagnosis when compared with those having secondary malignant tumours. The most common symptom

for the primary tumours was swelling, while pain as a symptom was virtually absent. Those with secondary neoplasms often had multiple quadrant involvement of the jaws. Symptoms were present for a longer period and were of less severity in the children with primary tumours. Children with metastatic tumours were generally more ill when first examined.

The appearance of a jaw tumour was the initial symptom of a general disease process in seven of the nine children. Radiographically, both primary and secondary tumours produced osteolytic lesions. Most cases were diagnosed following an intra-oral biopsy.

As expected survival in the two groups varied remarkably. Of those children with primary tumours, all were alive without recurrent disease for an average of 8 years, whereas there were only two short-term survivors in the group with secondary tumours, both with widespread disease (Dehner, 1973).

Jaffe and Jaffe (1978) analysed 178 paediatric head and neck malignancies over a ten year period from 1960-1969. Thirteen percent (23) of these tumours occurred in the maxillofacial and oral region. They found the cheek (including the maxilla and maxillary sinus) to be the most common site of involvement, followed by the mandible and the remaining sites in the oral cavity. The most common tumours were the fibrosarcomas, rhabdomyosarcomas, and lymphosarcomas (malignant lymphomas). An interesting feature of this article was the presence of a

squamous cell carcinoma of the maxillary sinus, a malignant haemangiopericytoma of the soft palate and a malignant haemangio-endothelioma of the cheek. No further details on clinical features were given. Treatment of these malignant tumours consisted of a combination of surgery, chemotherapy, radiotherapy and cryosurgery. They concluded that a good knowledge of the common malignant tumours is necessary if treatment is to be successful.

Jaffe (1978) noted the importance of cheek tumours, stating that cheek tumours could represent a primary lesion in the soft tissues of the cheek, but often may also represent lesions from a primary in the maxillary bone (including the antrum), infratemporal fossa or pterygoid fossa. He called these three areas the "silent areas", since tumours arising here remained silent for a long period of time and only became symptomatic at an advanced stage of the tumour. The extent of these tumours are often difficult to assess clinically because local spread is diffuse and the limits are difficult to define. Palpation of the gingivo-buccal sulcus, the retromolar trigone or soft palate may often reveal intra-oral extension. Trismus was also regarded as an important sign as it could indicate involvement of the pterygoid muscles or the temporomandibular joint. Radiographic examination of these spaces is essential according to Jaffe (1978).

In 1985, Chuong and Kaban analysed 48 children treated at the Children's Hospital in Boston for a primary tumour of the jaws

over a ten year period from 1973-1983. Only seven of the 48 patients had a malignant tumour. The malignant mesenchymal tumours included two cases of osteogenic sarcoma, and one case each of a chondrosarcoma, malignant mesenchymoma, Burkitt's lymphoma and a Ewing's sarcoma. All, except the Burkitt's lymphoma and Ewing's sarcoma involved the maxilla. There was only one case of a malignant epithelial tumour, viz. a central muco-epidermoid carcinoma of the anterior maxilla in a 16 year old girl. This tumour was diagnosed after an apicectomy was performed on an upper central incisor.

Pain and swelling were the dominant symptoms of this series of tumours. Paraesthesia was not encountered although it was stated that subtle degrees of sensory changes in young patients are often difficult to detect. Constitutional symptoms were common in the malignant mesenchymal group and consisted of malaise, anorexia, and weight loss. The average age of these patients at the time of diagnosis was 11,8 years. Treatment consisted of surgical resection and radiotherapy for the malignant mesenchymal tumours, surgical resection for the muco-epidermoid carcinoma and chemotherapy for the single case of Burkitt's lymphoma. Survival was good, with only one patient with an osteogenic sarcoma succumbing to the disease after a mean follow-up period of 23 months (Chuong and Kaban, 1985).

Asamoah *et al.* (1990) reviewed 134 cases of paediatric jaw tumours in Nigeria from 1973-1984, a period of eleven years. Of these, 79 (59%) represented malignant tumours. The most common

tumour was Burkitt's lymphoma, accounting for 76% of all the malignant tumours. This was followed in decreasing order of frequency by non-Burkitt's lymphoma, sarcoma (fibrosarcoma, rhabdomyosarcoma and osteosarcoma) and carcinoma (squamous cell carcinoma and anaplastic carcinoma). The average age of the patients at the time of diagnosis was 8,5 years and their ages ranged from 2-14 years. The mandible and the maxilla were equally involved. Males were more commonly affected than females. The most common presenting symptom was a rapidly enlarging swelling, except for the fibrosarcomas, where toothache was a common complaint. This often lead to tooth extraction, which was followed by a rapid growth of the lesion from the socket. Although survival rates were not given, the malignant lesions were found to have a poor prognosis. Late presentation due to ignorance on the part of the parents, poverty, lack of facilities, wrong diagnosis, and failure by the primary health worker to make early referrals were cited as reasons for the poor prognosis.

Because rhabdomyosarcomas and Burkitt's lymphomas were found to be the most common tumours in this study, they are reviewed and discussed separately.

2.3 Rhabdomyosarcomas of the maxillofacial and oral region in children

2.3.1 Definition

The WHO defines a rhabdomyosarcoma as a highly malignant tumour of rhabdomyoblasts in varying stages of differentiation or

without intracellular myofibrils, and with or without cross-striations (Enzinger *et al.*, 1969).

2.3.2 Historical background

The first description of a rhabdomyosarcoma can be traced as far back as 1854, when Weber described a localised enlargement of the tongue. The lesion was excised, only to reappear shortly thereafter. Although this was not called a tumour by Weber, his description of the lesion leaves no doubt that it was a rhabdomyosarcoma (cited by Stout, 1946).

In addition to Weber's report, early case reports of malignant tumours of skeletal muscle arising from the oral tissues were written by Ribbert in 1892, and Pendl in 1895. Ribbert described two cases of rhabdomyosarcoma, one of which occurred in the facial soft tissues of a boy. Pendl described a congenital rhabdomyosarcoma of the tongue (cited by Stout, 1946).

In 1923 Nicory reported on a malignant tumour of skeletal muscle arising from the uvula. He concluded that these tumours probably resulted from the inclusion of "sarco blasts" in unusual positions. Trauma as an induction agent was, however, not excluded. In the following year, Martin and Alexander (1924) reported on a rhabdomyosarcoma of the soft palate.

Most of these early cases were treated as curiosities or as striking examples of the close resemblance between sarcoma and developing normal tissue, often evoking lengthy debates as to

their histogenesis. In some of the earlier studies, Wilm's tumour and malignant mixed mesodermal tumours were included among the rhabdomyosarcomas (Enzinger and Weiss, 1988). In 1937, Rakov reported on the similarity of the rhabdomyosarcoma to embryonal skeletal muscle.

Apart from occurring in man, reports of rhabdomyosarcomas occurring in animals such as cows, birds, fish, rats and mice have also appeared in the literature of the early 1920's (Stout, 1946).

2.3.3 Review of the literature: Rhabdomyosarcomas

The English literature dealing with rhabdomyosarcomas of the maxillofacial and oral region in children is sparse. Most of the reported cases have been studied and described as part of large series on all sites or in head and neck series. Although this approach has led to a better understanding and significant increase in survival, it has obscured the clinicopathologic aspects of oral and maxillofacial involvement.

In reviewing the literature, an attempt has once again been made to extract those cases involving the maxillofacial and oral region in children 15 years and younger and to analyze them independently of the rhabdomyosarcomas involving the other sites. In many cases data was insufficient to make any conclusions or statements regarding maxillofacial and oral involvement in children, thus reinforcing the need for the present study. This information is shown in Table 1.

Table 1: SUMMARY OF LITERATURE REVIEW: RHABDOMYOSARCOMAS

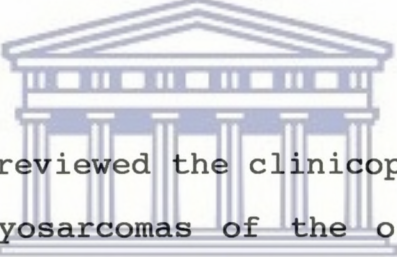
	Stout (1946)	Stobbe and Dargeon (1950)	Horn and Enterline (1957)	Dito and Batsakis (1963)
TOTAL NUMBER OF CASES	121	15	39	170
MAXILLOFACIAL AND ORAL INVOLVEMENT	6 (5%)	6 (40%)	4 (10,3%)	59 (35%)
AGE RANGE	0-12 years	1,4-14 years	9 months - 10 years	not specified
DURATION OF SYMPTOMS	2-12 months	0,5-3 months	not specified	not specified
SIGNS AND SYMPTOMS	not specified	not specified	not specified	non-tender mass
SITES	tongue face	soft palate parotid mandible zygoma	mandible face parotid maxillary sinus	face tongue palate others - mandible salivary glands floor of mouth maxillary sinus gingiva
TREATMENT	surgery	surgery & radiotherapy	surgery	surgery
SURVIVAL	not specified	21 months	18 months	22 months

The only reports in the literature dealing specifically with maxillofacial and oral involvement (apart from individual case reports) are those of Dito and Batsakis, 1963; O'Day *et al.*, 1965; Bras *et al.*, 1987; and of Peters *et al.*, 1989 and will therefore be presented in somewhat greater detail.

In 1963, Dito and Batsakis reviewed the biologic behaviour and response to treatment of 49 oral and pharyngeal rhabdomyosarcomas. Their anatomic distribution was as follows: palate and uvula 12 cases (24,5%); tongue 12 cases (24,5%); floor of mouth 2 cases (4%) and gingiva 1 case (2%). Seventy-nine percent of the patients were under 12 years of age, indicating that rhabdomyosarcoma of the mouth and pharynx is primarily a disease of childhood. The duration of symptoms ranged from 1-6 months. There was an inverse relationship between duration of symptoms and survival. The lungs and the bone marrow were the most common sites for metastatic deposits.

The embryonal rhabdomyosarcoma was the most common histological subtype. Tongue tumours were found to be almost exclusively pleomorphic in type. Dito and Batsakis (1963) stated that this was probably due to the fact that the tumours in the tongue arose from a "more differentiated tissue" compared to the embryonal tumours which arose in other sites. Survival was poor, with only 12,2% of the patients surviving for more than 5 years, irrespective of whether treatment consisted of surgery only or a combination of surgery and radiotherapy.

In addition, Dito and Batsakis (1963) found that the gross specimens had no characteristic features by which a diagnosis could be made. Histologically, cross-striations were more difficult to see in the embryonal rhabdomyosarcoma of young patients. They suggested guidelines for the diagnosis of these tumours by histopathologists who are not familiar with the cellular pattern. The presence of round or elongated malignant cells with bright, granular, eosinophilic cytoplasm should alert one to the myogenic nature of the tumour. Furthermore, they too stressed the fact that the presence of cross-striations should not be regarded as a sine qua non for the diagnosis of a rhabdomyosarcoma.



O'Day *et al.* (1965) reviewed the clinicopathologic features of 11 embryonal rhabdomyosarcomas of the oral soft tissues. Of these, 7 (63,6%) occurred in children. The age range was 3-15 years and the mean age was 8 years. There was a slight female predominance. The most common symptom was a painless swelling. Strabismus, dysphagia, dysphonia, deviation of the mandible and physical debilitation were regarded as late symptoms. The duration of symptoms ranged from one month to 2 years, with a mean duration of 7 months. The most common site to be involved was the soft palate, followed by the buccal mucosa and tongue. The principle mode of therapy in all 7 cases was radiotherapy. They emphasised the importance of radiotherapy as an adjunct to surgery. Of the 7 children, 5 had succumbed to the disease, the cause of death being either local recurrence or metastases. The bone marrow, lungs and brain were recorded as sites of

metastases.

In 1987, Bras *et al.*, reviewed 16 patients with rhabdomyosarcomas of the oral soft tissues treated at the M.D. Anderson Hospital in Texas between 1944 and 1984, a period of 40 years. This represented 12% of all head and neck rhabdomyosarcomas and 5% of all rhabdomyosarcomas. Eleven out of the 16 occurred in children with an age range of 3-15 years. The mean age was 7,4 years. There was a slight female predominance. The most common site of occurrence was the soft palate. Other sites of involvement included the gingiva, floor of mouth, retromolar trigone, tongue, cheek and mandible. The most common symptom was a rapidly growing painless mass. Pain, paraesthesia, loosening of teeth and trismus were regarded as symptoms of advanced disease. Symptoms, however, may be vague and may mimic other conditions. They make the point that many cases are mistaken for infection, and this tends to delay the diagnosis. The duration of symptoms ranged from 0-26 weeks with a mean duration of 7,4 weeks. Nineteen percent of the entire series had lymph node involvement at the time of diagnosis.

The embryonal rhabdomyosarcoma was the most common histologic type, followed by the alveolar and embryonal/pleomorphic types. Of the 5 children treated before mid-1968 when the principle mode of therapy was surgery, 4 died of disease. All of the 6 patients treated after mid-1968 when a multimodel approach was employed (surgery, chemotherapy and radiotherapy), were alive and free of disease for period ranging from 1-14 years. This study showed

that the multidisciplinary approach had led to a significant increase in survival, but not without the severe side effects that the patients had to endure (Bras *et al.*, 1987).

Peters *et al.* (1989) analysed 8 cases of rhabdomyosarcomas in the Witwatersrand that presented in the oral and para-oral region over a 25 year period. The rhabdomyosarcoma was found to be the fourth most common oral sarcoma after osteosarcoma, fibrosarcoma and chondrosarcoma. In patients younger than 20 years, rhabdomyosarcoma was found to be the second most common sarcoma after osteosarcoma.

Of the 8 cases, 4 occurred in children with an age range of 7-15 years and a mean age of 12,5 years. There was a male predominance of 3:4. In the entire series, only one patient was found to be caucasoid. The most common site of occurrence was the mandible, followed by the cheek and maxillary sinus. The pathogenesis of intrabony cases was explained by the fact that rhabdomyosarcomas arose primarily from malignant change of primitive mesenchymal cells rather than from differentiated muscle. Histologically, 3 cases were of the alveolar subtype, while one was of the embryonal subtype. Generally, most cases presented in Stage III of the Intergroup Rhabdomyosarcoma Study (IRS staging) (Table 2) (Mauerer *et al.*, 1977). Treatment consisted of a combination of surgery, chemotherapy and radiotherapy.

In addition to their reports of 8 original cases Peters *et al.* (1989) reviewed a further 113 cases of rhabdomyosarcomas of the

oral and para-oral region documented in the literature.

Table 2: CLINICAL GROUPING CLASSIFICATION (IRS)

GROUP	CLASSIFICATION
I	Localized disease, completely resected (regional nodes not involved). Confined to muscle or organ of origin. Contiguous involvement with infiltration outside the muscle or organ of origin, as through facial planes.
II	Grossly resected tumour with microscopic residual disease. No evidence of gross residual tumour; no evidence of regional node involvement. Regional disease, completely resected (regional nodes involved and/or expansion of tumour into an adjacent organ); all tumour completely resected with no microscopic residual tumour. Regional disease with involved nodes, grossly resected, but with evidence of microscopic residual.
III	Incomplete resection or biopsy with gross residual disease.
IV	Distant metastatic disease present at onset (lung, liver, bones, bone marrow, brain, and distant muscle and nodes).

Combined analysis of the 121 cases revealed that oral manifestations may occur in about one-fifth of head and neck cases. There was a predilection for rhabdomyosarcoma to occur in the soft palate, maxillary sinus, posterior mandible, cheek, lip and tongue. The gingiva and floor of the mouth were uncommon sites. Most of the cases were of the embryonal subtype followed by the alveolar sub-type. They stated that the large number of pleomorphic rhabdomyosarcomas reported in the literature is probably an overestimation since most of these were diagnosed before the malignant fibrous histiocytoma was recognised as an

entity.

The mean age was 14 years with a median of 12 years. Most of the cases occurred in the first two decades of life, with a decline in the third decade, suggesting that the predilection for head and neck rhabdomyosarcoma to involve children may not occur to the same degree in the oral region. This study supports the finding that combination therapy for oral and para-oral tumours produces an excellent prognosis. An exception were those lesions involving the posterior mandible. Three of the four patients with lesions manifesting in this site died after a mean survival of 1,1 years (Peters *et al.*, 1989).

In 1972 the multi-institutional *Intergroup Rhabdomyosarcoma Study* (IRS) was formed to attempt to integrate the diagnosis, staging and treatment of rhabdomyosarcomas (Maurer *et al.*, 1977). This approach has led to a better understanding and significant increase in survival. In the IRS data on head and neck rhabdomyosarcomas, a 75% overall 3-year disease-free survival period was noted for patients with stage I-III non-orbital, non-parameningeal rhabdomyosarcomas. No differences were found between the three stages. No survival rate has been given for patients with stage IV non-orbital, non-parameningeal rhabdomyosarcomas. The overall actuarial 5-year disease-free survival rate for patients with stage I-III non-orbital, non-parameningeal head and neck rhabdomyosarcomas was 78%. Survival rate for patients with involvement of the neck was significantly lower than for patients with oral, oropharyngeal and laryngeal

involvement. These data suggest an even better prognosis for patients with stage I-III oral rhabdomyosarcomas (Bras *et al.*, 1987).

The final report of the Intergroup Rhabdomyosarcoma Study was published in 1988 by Maurer *et al.* in which guidelines are set out for the management of patients based upon the clinical group of disease (Figure 1). Survival was found to be best in clinical group I and worst in clinical group IV. The estimated 5 year survival rate was given as 83%, 70%, 52% and 25% in clinical groups I-IV respectively. Once a patient relapsed, survival was found to be extremely poor. Thirty-two percent of those patients survived for one year and 17% survived for 2 years. The risk of distant metastases was found to be much greater than the risk of local recurrence within each clinical group.

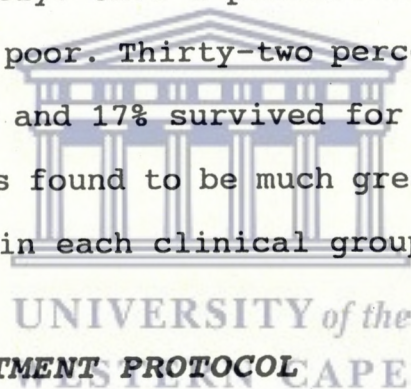
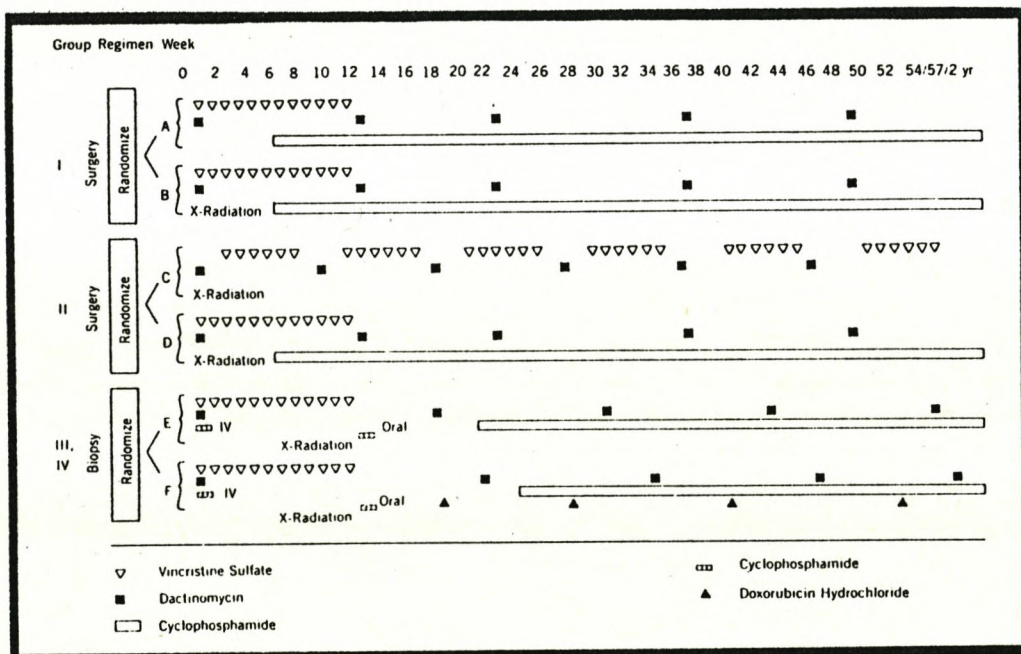


Figure 1: IRS TREATMENT PROTOCOL



2.3.3.1 Aetiology

Little is known about the underlying cause of neoplastic rhabdomyoblastic proliferations and the stimulus that may induce such growths.

Genetic factors have been implicated by the rare association of the disease with other neoplasms in the same patient. Rhabdomyosarcoma, for instance, has been described as a second malignant neoplasm in patients with bilateral retinoblastomas and unilateral familial retinoblastomas (Chemello *et al.*, 1988 and McGill, 1989). It has been shown that a deletion of the q14 band of chromosome number 13 may play a role in the development of second malignant neoplasms in patients with bilateral or familial retinoblastomas. The mutation at this gene locus may be inherited, arise in gametogenesis, or occur somatically (Chemello *et al.*, 1988). In 1969, Li and Fraumeni studied 418 reported cases of rhabdomyosarcoma and found in 5 families the presence of a second child (three siblings and two cousins) with a soft tissue sarcoma. They also noted that the parents, grandparents and other relatives of these children had a high frequency of carcinomas of the breast and other diverse neoplasms at a relatively young age, thus suggesting "a familial syndrome of multiple primary cancers" (Enzinger and Weiss, 1988).

Furthermore, a specific chromosomal abnormality has been identified in approximately 50% of cases of rhabdomyosarcomas, viz. translocation between the q35 band of chromosome number 2 and the q14 band of chromosome number 13 (McGill, 1989).

The role that extrinsic factors play is also unknown. Grufferman *et al.* (1982) found an association with a lower socio-economic status. They also found a significant correlation with paternal smoking habits. The development of rhabdomyosarcoma following radiation for retinoblastoma is well known. Abramson (1985) found that patients with retinoblastomas treated with radiation had a greater incidence of second malignant neoplasms compared with those not treated with radiation (cited in Chemello *et al.*, 1988).

Trauma has also been implicated as a causative agent and, Horn and Enterline (1958) have stated that "it is unwise to exclude trauma as a trigger mechanism". Enzinger and Weiss (1988) have witnessed cases of rhabdomyosarcoma at the site of a molar extraction socket, femoral fracture and a traumatic scrotal haematoma.



UNIVERSITY of the
WESTERN CAPE

2.3.3.2 Pathogenesis

Rhabdomyosarcomas are thought to arise from malignant change of primitive mesenchymal cells and not from differentiated muscle cells. Skeletal muscle also arises from primitive mesenchymal cells and during its development passes through a series of stages from a primitive round cell to a spindle cell to a multinucleated muscle fibre with the characteristic transverse and longitudinal structure. Similarly, the rhabdomyosarcomatous cell may assume various morphological appearances depending on the degree of differentiation, thus mimicking normal skeletal development (Proops and Mann, 1984; Peters *et al.*, 1989).

Origin from primitive mesenchymal cells is supported by the development of rhabdomyosarcomas in areas where striated muscle tissue is absent, such as the common bile duct, urinary bladder and bone marrow (e.g. mandible) (Peters *et al.*, 1984).

In addition to primitive mesenchymal cells, satellite cells may play a role in the histogenesis of the tumour (Enzinger and Weiss, 1988). Satellite cells are small cells with a single nucleus that lie between the sarcolemma and endomesium. These cells represent a reservoir of embryonic myoblasts. During life, they can divide and play a role in the repair and regeneration that can occur in mature muscle (Leeson and Leeson, 1981).

There is little support for the origin from metaplastic smooth muscle. Muscle tissues are unable to undergo mitotic activity following injury and therefore it is unlikely for rhabdomyosarcomas to arise from differentiated muscle cells (Enzinger and Weiss, 1988).

2.3.3.3 Histologic classification

The original histologic criteria for the diagnosis of rhabdomyosarcoma was established by Stout in 1946. Horn and Enterline (1958) proposed four subtypes of rhabdomyosarcoma - pleomorphic, embryonal, alveolar and botryoid. The World Health Organisation classifies rhabdomyosarcomas into predominantly pleomorphic, predominantly alveolar, predominantly embryonal and mixed types (Enzinger *et al.*, 1969).

(a) Embryonal rhabdomyosarcoma

The embryonal rhabdomyosarcoma was first described as an entity by Stobbe and Dargeon in 1950. Its name has been derived from the fact that the cells resemble those of normally developing skeletal muscle in the 7-10 week foetus (Proops and Mann, 1989). It is the most common of the four subtypes, accounting for 70-80% of all rhabdomyosarcomas. It affects children between birth and 15 years of age mainly. (Enzinger and Weiss, 1988) It occurs more commonly in the head and neck area than any of the other forms (Shafer, Hine and Levy, 1983), but may also occur in the genitourinary tract, retroperitoneum and less often in the limbs (Enzinger and Weiss, 1988).

(b) Botryoid rhabdomyosarcoma

The botryoid rhabdomyosarcoma (sarcoma botryoides) is regarded as a variant of the embryonal type. The term botryoid is derived from the Greek word for grapes. It describes a modified form of embryonal rhabdomyosarcoma characterised by its grape-like or polypoid growth pattern.

These tumours arise in the submucosa and the growth pattern is due to their unrestricted growth in body cavities or on body surfaces (Enzinger and Weiss, 1988). In the head and neck it may involve the maxillary sinus, nasopharynx, middle ear and soft palate (Horn and Enterline, 1958). It has long been recognised as a tumour of the vagina, prostate, bladder and common bile duct in young children (Shafer, Hine and Levy, 1983).

(c) Alveolar rhabdomyosarcoma

The alveolar rhabdomyosarcoma was first described by Riopelle and Thériault in 1956 (cited in Horn and Enterline, 1958). It derives its name from the alveolar arrangement of the cells histologically. It accounts for 10-20% of all rhabdomyosarcomas (Enzinger and Weiss, 1988). It affects children and young adults in the 10-20 year age group with the majority of cases occurring in the upper and lower extremities, although head and neck involvement may occur in 18% of cases (Shafer, Hine and Levy, 1983). The typical histological features of the alveolar rhabdomyosarcoma permits a positive diagnosis to be made, even in the absence of rhabdomyoblasts. The term "juvenile rhabdomyosarcoma" has been proposed to be used for both embryonal and alveolar variants because of their close histologic relation and resemblance. Other authors, on the other hand, are of the opinion that these 2 types are different in their clinical course and anatomic location, and can also be differentiated from each other histologically, based on strict criteria (Sadeghi *et al.*, 1988). Of the 4 types, the alveolar type has the worst prognosis (Cotton *et al.*, 1987).

(d) Pleomorphic rhabdomyosarcoma

The pleomorphic rhabdomyosarcoma is regarded as the classical type of rhabdomyosarcoma. It is the least common of the 4 histologic subtypes (Enzinger and Weiss, 1988). It occurs more frequently in the extremities and tends to affect older individuals (Shafer, Hine and Levy, 1983). There is a close resemblance between this tumour and the malignant fibrous

histiocytoma, which makes diagnosis at times very difficult.

2.3.3.4 Age and gender distribution

The rhabdomyosarcoma has a fairly uniform age incidence occurring predominantly in infants and children. It is somewhat less common in adolescents and young adults, and rare in adults beyond 45 years of age.

The age distribution varies according to the anatomical location and the histologic type. The embryonal rhabdomyosarcoma including the botryoid type, are found mostly in infants and children, while the alveolar type occurs mainly in adolescents and young adults. Pleomorphic rhabdomyosarcoma occurs mostly in older patients (50-55 years) (Enzinger and Weiss, 1988).

The age distribution specifically for children with maxillofacial and oral rhabdomyosarcomas has not yet been established. All of the reports in the literature dealing with oral and para-oral involvement have included adults. O'Day *et al.* (1965) in their study of 11 cases found an age range of 2-41 years with a mean age of 16 years. The age range for those tumours occurring in children only was 2-15 years with a mean age of 8 years. Similarly, in the series reported by Bras *et al.* (1987), the age range for the childhood rhabdomyosarcomas was 3-15 years with a mean age of 7,4 years.

According to Enzinger and Weiss (1988) males are more commonly affected than females by a ratio of 1,5:1. In adolescents and

young adults, the male preponderance is less pronounced.

2.3.3.5 Anatomical site of lesion

Rhabdomyosarcomas may occur anywhere in the body, but three anatomic locations have been identified:

1. Head and neck.
2. Genitourinary tract and retroperitoneum.
3. Upper and lower extremities.

The head and neck is the most frequent site for the occurrence of childhood rhabdomyosarcomas (Cotton *et al.*, 1987). The instability of mesenchyme in infants may explain the age prevalence of head and neck rhabdomyosarcomas (Enzinger and Weiss, 1988).

Biologic behaviour and prognosis, are influenced by the anatomic site of head and neck rhabdomyosarcomas. Hence head and neck rhabdomyosarcomas have been subdivided into three groups:

1. The orbital group which is characterised by a high cure rate.
2. The parameningeal group which consists of the infratemporal fossa, middle ear, nasopharynx, nasal cavity, and the paranasal sinuses. Each is characterised by the potential for direct meningeal invasion, hence their poor prognosis.
3. Non-parameningeal, non-orbital group which includes the neck, parotid region, oropharynx, cheek and masseter, scalp, oral cavity, and larynx. They have an intermediate cure rate (Wharam *et al.*, 1984).

Site predilections within the maxillofacial and oral region in children has not been as well established as it has for head and neck rhabdomyosarcomas (Peters *et al.*, 1989). Dito and Batsakis (1963), on reviewing 49 oral and pharyngeal rhabdomyosarcomas, found the soft palate and tongue to be the most common sites, followed by the floor of the mouth and gingiva. O'Day *et al.* (1965) in a series of 11 oral rhabdomyosarcomas found 4 in the soft palate, 3 in the cheek and one each in the upper and lower labial folds, as well as the lateral aspect of the tongue. Bras *et al.* (1987) reported on 16 oral rhabdomyosarcomas and found the soft palate to be the most common site. Peters *et al.* (1989) did not find a site predilection in their series, although they found that palatal involvement was somewhat more common and that gingival and floor of mouth lesions were unusual locations. Yammamoto *et al.* (1984) reported the tongue to be the most common site.



2.4 Burkitt's lymphoma

2.4.1 Definition

The WHO defines Burkitt's lymphoma as a malignant neoplasm composed of lymphoid cells believed to be of B-cell type (Enzinger *et al.*, 1969).

2.4.2 Historical background

In 1958, Dennis Burkitt reported for the first time on a type of malignant lymphoma involving the jaws of African children in Uganda. In 1963, at a meeting of the *International Union Against Cancer* (UICC), the tumour was officially designated "Burkitt's tumour" in recognition of his pioneering work on the tumour (Hutt, 1970). In 1969, the World Health Organisation (WHO) recognised the lesion as a malignant lymphoma, undifferentiated, Burkitt's type (Hesseling *et al.*, 1989).

Although Burkitt has been credited for the discovery of the tumour, early African carvings of jaw tumours suggest that these tumours were observed in Africa long before Burkitt first described the condition. The first, almost undoubted case of Burkitt's lymphoma, was described in detail by Sir Albert Cook in his clinical records of the Mengo Hospital for 1904, which reads as follows: "The whole of the right side of the face and cheek is occupied by a numbed swelling, which on examining the interior of the mouth, is seen to be connected with the upper jaw, the substance of the upper jaw being infiltrated and expanded by a growth. The tumour extends back to the anterior pillars of the fauces. The right lower eyelid and nostril and angle of mouth are much displaced. Speech is imperfect. The child is growing thin. The skin on the tumour is quite movable" (Burkitt, 1970).

In another case involving the jaw, Cook's excellent description of the clinical details including an illustration of the extent

of the lesion, leaves no doubt that the lesion was a Burkitt's lymphoma (Figure 2). This case of 1910 reads as follows: "Swelling began underneath the jaw one month ago. The eye began to be affected two weeks ago. Parents cupped swelling and put on Kiganda medicine. No cough. The growth appears to be nearly half the size of the child's head. Its characters are: it is firm and elastic. Fixed to the left side of jaw. Extends upwards to zygoma. Downwards nearly to clavicle. To the right it extends beyond midline. The gum is involved on the left side and the teeth are displaced and dropping out. Operation - child died on the table soon after the operation had commenced" (Davies et al., 1964).

Figure 2: COOK'S DESCRIPTION OF A "SARCOMA OF THE JAW"

Dr. E. N. Cook.

Name: WARD Callington BED. NO. 700

Name: Jyefu Duhalay Disease: Sarcoma of jaw

Date of Admittance: May 18/40 Date of Discharge: May 25th 1940

Religion: P.C Result: Death

History of Present Illness.

Swelling began underneath the jaw one month ago. The eye began to be affected two weeks ago. Parents cupped the swelling & put on Kiganda medicine. No cough.

Previous Illnesses. It's head S.

Present Condition. See following pages

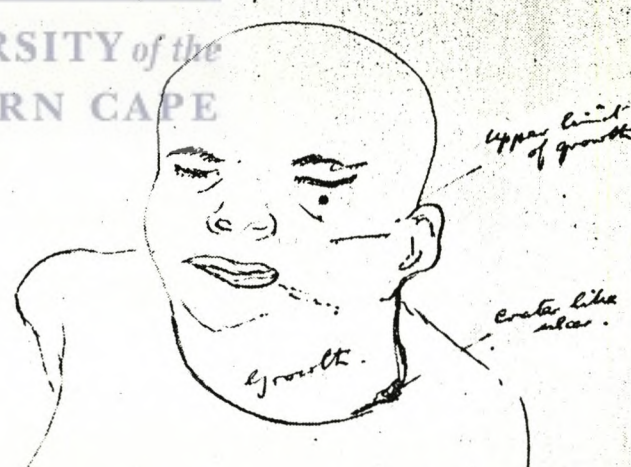
Rj. Mouth to be washed with Boric Acid 1. J.S.

May 21. Mist. S.B. 3iii. 1. J.S.

May 22. Rj. Mist. 2iii 3iii

May 23. Rj. Mist. 2iii 3iii

May 24. R. ac. Ric. 3iii



The growth appears to be nearly half the size of the child's head. Its characters are

- It is firm & elastic
- Fixed to the left side of jaw
- Extends upwards to zygoma
- Downwards nearly to clavicle
- To the right it extends beyond midline.
- The gum is involved on the left side and the teeth are displaced & dropping out.

The child was carefully fed & cleaned up for a week.

May 25th Operation - child died on the table soon after the operation had commenced.

As early as 1901, Cook made the observation that sarcoma of the jaws (both upper and lower) was the most common form of malignant disease in Uganda. In his paper, Cook (1901) had reproduced a photograph of a native princess who had been suffering from a sarcoma of the jaw.

An analysis of Cook's records of the Mengo Hospital in Uganda revealed that the curious lymphoma of childhood had been present since his arrival in Uganda in February 1897, and possibly earlier. In his records on childhood neoplasms, jaw tumours accounted for 27% of the total number seen between 1897 and 1956. Most of these children were in the 5-10 year age group (Davies *et al.*, 1964).

2.4.3 Review of literature: Burkitt's lymphoma

A review of the early literature reveals that reports on Burkitt's lymphoma appeared long before Burkitt's first description of the condition in 1958. Because the nature of the disease was as yet unknown, these tumours were simply referred to as jaw sarcomas. In 1934, Smith and Elmes, described 16 cases in Nigeria. The tumour was also described by Camain in 1954 and Thijs in 1957 (cited in Hutt, 1970).

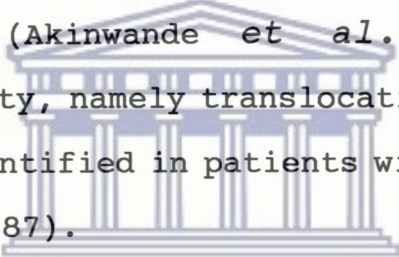
In 1961, Burkitt and O'Connor described in detail the clinical features of Burkitt's lymphoma. They noted the peculiar geographic distribution of the tumour as well as the rapid growth of these lesions. O'Connor (1961) described the histologic features of the tumour and noted the so-called "starry sky" or

"water pot" appearance.

Epidemiologic investigations soon revealed that this lymphoma was found principally in humid, hot areas of low altitude, and was rare in arid, mountainous areas (Burkitt, 1962 [a]). In 1962, Burkitt published the results of a "tumour safari". This expedition revealed that the lesion was found as far south as Maputo (Mozambique). The tumours were never seen at altitudes greater than 5,000 feet above sea level, in areas where the mean temperature (at any time of the year) fell to below 15°C (60°F), or where rainfall was less than 20 inches. The tumour was confined to a belt across Africa, lying approximately between 15° north and 15° south of the equator. These areas were designated the "lymphoma belt". Because of its dependence on climatic factors, Burkitt concluded that the tumour might be induced by one of the "wet-tropics" group of mosquitoes. The peculiar geographic distribution of the tumour suggested to Burkitt that the disease was caused by a virus vector (Burkitt, 1962 [b]). Soon thereafter Epstein, Achong and Bar (1964) demonstrated the presence of a DNA-herpes-like virus in specimens of Burkitt's lymphoma. This virus came to be known as the Epstein-Bar virus. However, because of the ubiquitous nature of this virus, it soon became evident that some additional factor was responsible for the peculiar distribution of this tumour. Dalldorf, in 1962, was the first to suggest that malaria might play a role (cited in Burkitt, 1983). Burkitt found a direct relationship between tumour incidence and malaria intensity. Furthermore, children with the sickle-cell trait, who are protected against malaria,

were found to be at a lower risk of developing Burkitt's lymphoma.

This subsequently led to the postulation that the Epstein-Bar virus, in the presence of immunosuppression caused by prolonged exposure to malaria, became oncogenic and led to the development of the tumour (Burkitt, 1983). Over the years, evidence supporting the role of the Epstein-Bar virus in the etiology of Burkitt's lymphoma has been provided by the presence of high antibody titre to Epstein-Bar virus related antigens and by the demonstration of Epstein-Bar virus genomes in cell lines of Burkitt's lymphoma (Akinwande *et al.* 1986). A specific chromosomal abnormality, namely translocation between chromosome 8 and 14 have been identified in patients with Burkitt's lymphoma (Robins and Kumar, 1987).



2.4.3.1 Burkitt's lymphoma in South Africa

After the tumour safari, Burkitt stated that the condition was virtually unknown in South Africa. Murray and Oettlé, after searching through the records of the South African Institute for Medical Research in Johannesburg in 1961 found no cases of Burkitt's lymphoma. In 1963, Gluckman reported on two cases occurring in white children in Johannesburg. In the same year, Chapman and Jenkins reported on five cases from the coastal region of Northern Natal. These patients lived at altitudes of less than 1,000 feet and within the influence of the warm south-flowing Mozambique current (Burkitt, 1970).

In 1962, Bennet found six cases that were identical to Burkitt's lymphoma in the records of the Radiotherapy Department of Groote Schuur Hospital, Cape Town. This institute receives patients from the whole of the Cape Province and from Namibia (formerly South West Africa). These six patients were scattered over a 10 year period during which time 159 children with cancer were recorded (62 white and 97 black). All six cases were between 5 and 15 years of age and four of them had jaw lesions (cited in Burkitt, 1970).

In 1965, Schmaman *et al.* reported on five children from Baragwanath Hospital, Soweto, Johannesburg. Only one of the five had a jaw lesion that was seen radiologically but not clinically. A review of 10 year's histological records 10 more childhood lymphomas, of which two were considered to be Burkitt's lymphoma. One of these occurred in the mandible of a 2 year old child. In 1965, Becker searched through the pathological records of the University of the Witwatersrand Medical School, Johannesburg, and found no cases of Burkitt's lymphoma (Burkitt, 1970).

In 1989, Hesseling *et al.* reported on 22 cases of Burkitt's lymphoma seen at the Tygerberg Hospital, Cape Town, between 1977 and 1986. Thirteen of the 22 had jaw involvement.

2.4.3.2 Burkitt's lymphoma outside Africa

Until the early 1970's, Burkitt's lymphoma was regarded as an exclusively African disease, being endemic in the "lymphoma belt". It was found to be the most common malignancy of childhood

in tropical Africa (Hupp *et al.*, 1982). It was characterised by the presence of jaw lesions in more than 50% of the cases, affecting either the maxilla, mandible, or both (Burkitt *et al.*, 1961). Loosening of the teeth was often the first symptom of the disease, with the result that the child was first brought to the dental surgeon. Abdominal tumours were also common, and all patients with jaw lesions had abdominal lesions (Burkitt *et al.*, 1961).

In 1975, Banks *et al.* reported on 30 cases of Burkitt's lymphoma in the United States of America. Consequently, a North American Burkitt's lymphoma registry was established. Because of the clinical differences between the American and African cases, the condition was subdivided into African Burkitt's lymphoma (AfBL) and American Burkitt's lymphoma (AmBL) (Levine *et al.*, 1982).

Subsequently many reports of sporadic cases occurring in other parts of the world have appeared in the literature. In 1986, Zachariades and Papanicolaou reported on the first case of Burkitt's lymphoma in Greece. In 1990, Anavi *et al.* published the results of the first multiparametric analysis of Burkitt's lymphoma of the head, neck and maxillofacial region in children in Israel.

Reports of Burkitt's lymphoma in the Middle-East also appeared in the literature (Anaissie *et al.*, 1985). It has therefore become clear that Burkitt's lymphoma is not an exclusively African disease and that sporadic cases have been seen worldwide.

2.4.3.3 Pathogenesis of jaw lesions

The pathogenesis of predilection of Burkitt's lymphoma for the jaws has received little attention in the literature. Adatia (1978) is of the opinion that the disease starts from within the bone marrow and that the predilection for the jaws is related to odontogenesis rather than to the actual presence of teeth. This tends to explain why the incidence decreases with age. This is supported by the fact that the dental pulp is often invaded (Akinwande *et al.*, 1986).

On the other hand, it has been postulated that open oral wounds (from deciduous tooth eruption, exfoliation, extraction and decay) provide an entry for Epstein-Bar virus. Infection related jaw lymphocytosis then provides the necessary substrate for the development of this virally induced lesion. African Burkitt's lymphoma primarily affects the posterior jaw sites, and both active bone marrow therefore areas of infection are prominent in the posterior portion of the jaw. Epstein-Bar virus has been isolated from oral biopsies and teeth, it is also found in oral secretions of patients with Epstein-Bar virus infections (Hesseling *et al.*, 1989).

Burkitt's lymphoma is rare in children younger than two years. This may be due to the lack of a viral entry point before the eruption of the deciduous teeth. The age distribution thus coincides with the time of high caries incidence, eruption and exfoliation of the deciduous dentition. Jaw tumours are also rare in older patients, because of the lack of a dento-alveolar entry

site for Epstein-Bar virus (Hesseling et al., 1989).

2.4.3.4 Signs and symptoms

Jaw lesions constitute the most characteristic feature of Burkitt's lymphoma.

Loosening of the teeth is the earliest sign of jaw involvement. It is unusual for deciduous or permanent molars to become mobile in the absence of any disease. In the majority of cases, it affects the deciduous molars or permanent molars and premolars. Occasionally, the incisors are involved. This sudden, painless loosening of the teeth must be viewed with suspicion. The tumour infiltrates the periodontal ligament and causes destruction of the compact bone around the sockets of the teeth. This results in loosening of the teeth and premature exfoliation of the deciduous dentition. The enlarging tumour pushes against the unerupted teeth, thus resulting in premature eruption of the permanent teeth (Adatia, 1970).

As the tumour grows and enlarges, it displaces adjacent teeth so that these teeth appear to be "floating" in a mass of soft tissue. The occlusion becomes deranged once the teeth have been displaced. The tumour has the ability to break through the outer cortex and invade the soft tissues with resultant facial deformity. Rarely does it ulcerate the skin or mucosa.

Cranial nerves in their extra-cranial course are not affected by the tumour. This is evidenced by the fact that there have been

no reports of anaesthesia or paraesthesia of the lips or mucosa, nor has there been any reports of paralysis of the muscles of facial expression or of the muscles of mastication. In contrast, intra-cranial tumours tend to invade neural structures (Adatia, 1970).

2.4.3.5 Radiographic features

(a) Early signs

Burkitt's lymphoma produces an osteolytic lesion. Early lesions consist of discrete radiolucent areas in the bone. Loss of the lamina dura is one of the earliest signs of bone involvement. The tumour may grow in the dental follicle, thus producing an enlargement of the crypts of developing teeth. Infiltration into the periodontal ligament results in widening of the periodontal ligament space (Goaz and White, 1987).


(b) Later signs

As the tumour progresses, the following radiographic features may be noted in the mandible: loss of the lamina dura; displacement of teeth; small radiolucent areas which coalesce to form large radiolucent areas with irregular margins giving it a "moth-eaten" appearance; and pathologic fractures. Once the lesion breaks through the cortex, subperiosteal new bone formation takes place perpendicular to the bone surface. The maxillary antrum becomes opacified due to the presence of tumour in the antrum. The zygomatic and other facial bones may show evidence of erosion (Adatia, 1966; Goaz and White, 1987).

2.5 Objectives of present study

The objectives of this study are to determine the clinical and pathological characteristics of a series of malignant tumours of the maxillofacial and oral region in children treated at the Red Cross War Memorial Children's Hospital and Groote Schuur Hospital over the past 20 years (1973-1993).

The rationale for this study is to provide a better understanding of the important clinical and pathologic features of malignant tumours of the maxillofacial and oral region in children. It is intended to assist both the clinician and the pathologist in making an early diagnosis so that the proper treatment may be instituted and thereby improving the prognosis.



MATERIALS AND METHODS

- 3.1 Introduction
- 3.2 Identification of study sample
- 3.3 Collection of data
 - 3.3.1 Clinical data
 - 3.3.2 Radiographic data
 - 3.3.3 Histopathologic data
- 3.4 Pilot study
- 3.5 Data analysis



UNIVERSITY *of the*
WESTERN CAPE

3.1 Introduction

A retrospective study of malignant tumours of the maxillofacial and oral region was carried out in children treated at Groote Schuur Hospital and Red Cross War Memorial Children's Hospital in Cape Town from the beginning of 1973 to the end of 1993, a period of 20 years. Both of these institutions treat patients from the Cape Province of South Africa and from Namibia.

3.2 Identification of study sample

Patients that were treated before 1983 were identified by reviewing the patient records of the Department of Radiotherapy, Groote Schuur Hospital, and of the Department of Oncology, Red Cross War Memorial Children's Hospital. Patients that were treated from 1983 onwards were identified by a search of the patient data-base of the Department of Medical Informatics, Groote Schuur Hospital and Red Cross War Memorial Children's Hospital. Additional patients were identified through contact with physicians involved in the management of these patients.

3.3 Collection of Data

3.3.1 Clinical data

Clinical data, as well as follow-up information, was obtained by a review of the patient files. The clinical features were analysed with respect to the following and recorded onto a proforma for each patient:

1. Diagnosis
2. Age at presentation
3. Gender

4. Race
5. Geographic location of patient
6. Anatomical site of lesion
7. Stage of disease (where recorded)
8. Presenting symptoms and signs
9. Duration of symptoms
10. Treatment
11. Survival

Patients with incomplete clinical data were excluded from the study.

3.3.2 Radiographic data

Radiographic features of the tumours with bony involvement were analysed by a review of the patient's radiographs. In cases where radiographs had been taken, but were not available for review, information on radiographic features was obtained from the radiologist's report.

3.3.3 Histopathologic data

Haematoxylin and eosin (H and E) stained histological sections were obtained for all malignant tumours of the maxillofacial and oral region identified in this series of children. Where histologic sections were found to be unsatisfactory, paraffin blocks were recut and stained with haematoxylin and eosin. In a limited number of rhabdomyosarcoma cases, special stained sections were available to help identify the tumour (Table 3).

Table 3: RHABDOMYOSARCOMA SPECIAL STAINS

SPECIAL STAIN	USE
Periodic acid-schiff (PAS)	Glycogen
Phosphotungstic acid haematoxylin (PTAH)	Cross-striations
Anti-myoglobin (ICC)	Myoglobin

Information on immunocytochemistry, when performed, was obtained from the histopathologist's report. Formalin unprocessed surgical or biopsy specimens were not reviewed.

All histopathologic sections were reviewed in conjunction with a histopathologist and the diagnosis confirmed or revised according to new classifications and concepts set out by the WHO.

3.4 Pilot study

A pilot study using ten patients was carried out in order to modify the proforma.

3.5 Data analysis

The completed proformas were processed and the data was recorded on DBase IV. The data was analysed using the Epistat Statistical Package. The analysed data was subjected to measures of central tendency such as arithmetic mean and median and measures of variation such as range.

For each item or variable of interest, a table of the data that would illustrate pertinent characteristics of the totality of

observations was produced. Presentation of the data was either in graph form or in a table to illustrate the distribution of frequencies of the variables.



UNIVERSITY *of the*
WESTERN CAPE

RESULTS

- 4.1 Analysis of entire series**
 - 4.1.1 Incidence**
 - 4.1.2 Histopathology**
 - 4.1.3 Age**
 - 4.1.4 Gender**
 - 4.1.5 Race**
 - 4.1.6 Geographic distribution**
 - 4.1.7 Anatomical site of lesion**
 - 4.1.8 Signs and Symptoms**
 - 4.1.9 Duration of symptoms**
 - 4.1.10 Radiographic features**
 - 4.1.11 Treatment**
 - 4.1.12 Survival**
- 4.2 Analysis of rhabdomyosarcoma series**
 - 4.2.1 Distribution of head and neck cases**
 - 4.2.2 Age, gender and race**
 - 4.2.3 Geographic distribution**
 - 4.2.4 Clinical stage**
 - 4.2.5 Anatomical site of lesion**
 - 4.2.6 Signs and Symptoms**
 - 4.2.7 Duration of symptoms**
 - 4.2.8 Cervical lymph node involvement and metastases**
 - 4.2.9 Histopathology**
 - 4.2.10 Radiographic features**
 - 4.2.11 Treatment**
 - 4.2.12 Survival**
- 4.3 Analysis of Burkitt's lymphoma series**

- 4.3.1 Incidence
- 4.3.2 Age, gender and race
- 4.3.3 Geographic distribution
- 4.3.4 Seasonal pattern
- 4.3.5 Anatomical site of lesion
- 4.3.6 Signs and Symptoms
- 4.3.7 Duration of symptoms
- 4.3.8 Histopathology
- 4.3.9 Immunocytochemistry
- 4.3.10 Radiographic features
- 4.3.11 Treatment
- 4.3.12 Survival

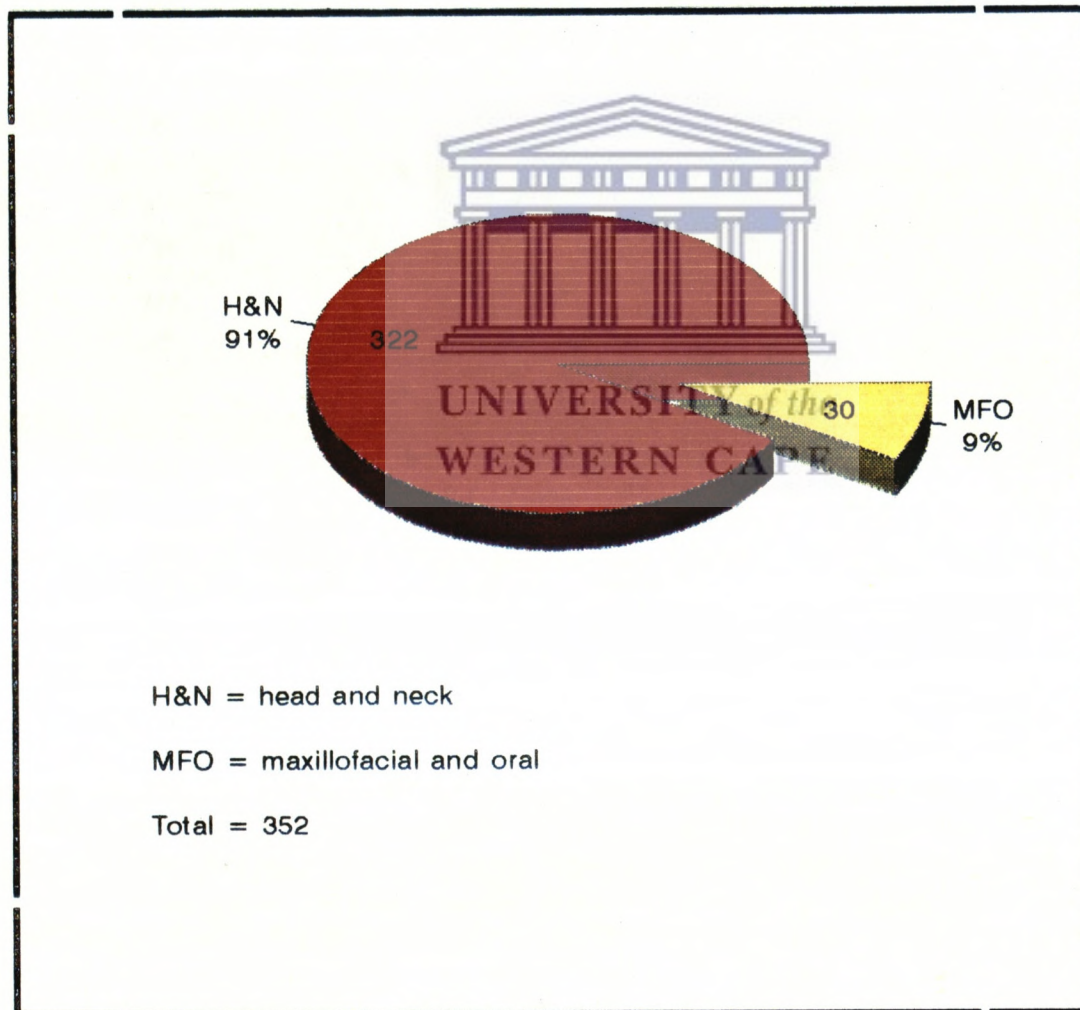


4.1 Analysis of entire series

4.1.1 Incidence

From January 1973 to December 1993, 352 children were treated for a malignant tumour arising from various anatomic sites in the head and neck region. Of these, 30 (8,5%) of the children were treated for a malignant tumour of the maxillofacial and oral region (Figure 3).

Figure 3: INCIDENCE OF MFO TUMOURS (1973-1993)



4.1.2 Histopathology

Table 4 shows the different histologic types of tumours seen in the 30 children. There were 11 rhabdomyosarcomas, 6 Burkitt's lymphomas, 3 acute myeloid leukaemias, 2 non-Hodgkin's lymphomas, 2 malignant fibrous histiocytomas and one of each of the following tumours: osteogenic sarcoma, leiomyosarcoma, Kaposi's sarcoma, malignant histiocytosis, Wilm's tumour and mucoepidermoid carcinoma.

Table 4: HISTOLOGIC TYPES OF PAEDIATRIC MALIGNANCIES

HISTOLOGIC TYPE	No.	%
Rhabdomyosarcoma (RMS)	11	36,7
Burkitt's lymphoma (BL)	6	20
Acute myeloid leukaemia (AML)	3	10
Non-Hodgkin's lymphoma (NHL)	2	6,7
Malignant fibrous histiocytoma (MFH)	2	6,7
Osteogenic sarcoma (OS)	1	3,3
Leiomyosarcoma (LMS)	1	3,3
Kaposi's sarcoma (KS)	1	3,3
Malignant histiocytosis (MH)	1	3,3
Wilm's tumour (WT)	1	3,3
Mucoepidermoid carcinoma (MEC)	1	3,3
TOTAL	30	100

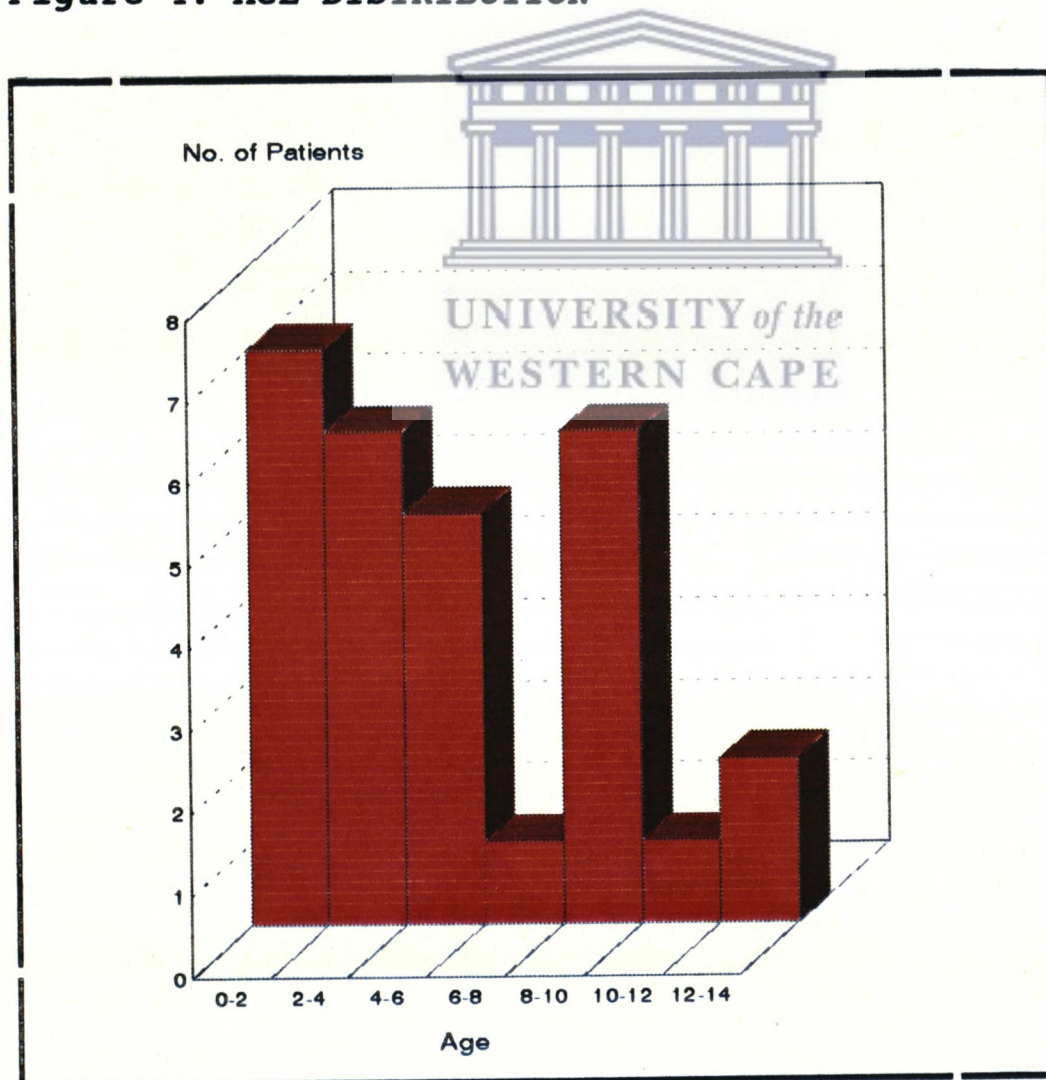
4.1.3 Age

The age at presentation ranged from 6 months to 13,8 years. The mean age was 5,7 years, with a median age of 5 years. Table 5 shows the age distribution of the various types of malignant tumours. The data is graphically represented in Figure 6.

Table 5: AGE DISTRIBUTION

TUMOUR	AGE RANGE (YRS)	MEAN AGE (YRS)
RMS	0,5 - 13	5,4
BL	3 - 8	4,8
AML	1 - 6	4
NHL	8,3 - 11,6	9,9
MFH	2,4 - 13	7,7
OS	—	9,6
LMS	—	13,8
KS	—	4
MH	—	1,6
WT	—	3
MEC	—	2,8

Figure 4: AGE DISTRIBUTION



4.1.4 Gender

There were 17 (56,7%) males and 13 (43,3%) females in the study. The male to female ratio was 1,3:1 (Table 6).

Table 6: GENDER DISTRIBUTION

TUMOUR	MALE		FEMALE		MALE: FEMALE RATIO
	No.	%	No.	%	
RMS	5	45,5	6	54,5	2,5:3
BL	3	50	3	50	1:1
AML	2	66,7	1	33,3	2:1
NHL	2	100	-	-	-
MFH	2	100	-	-	-
OS	-	-	1	100	-
LMS	-	-	1	100	-
KS	1	100	-	-	-
MH	-	1	1	-	-
WT	1	100	-	-	-
MEC	1	100	-	-	-
TOTAL	17	56,7	13	43,3	1,3:1

4.1.5 Race

The racial distribution of the various tumours is depicted in Table 7. There were 26 (86,7%) black patients and 4 (13,3%) white patients. The black to white ratio was 6,5:1 (Figure 5).

4.1.6 Geographic distribution

The patients came from three main geographic areas, viz. Western Cape, Eastern Cape and Namibia. Fifteen (50%) of the patients were from the Eastern Cape, 13 (43,3%) were from the Western Cape and 2 (6,7%) were from Namibia (Figure 6).

Table 7: RACIAL DISTRIBUTION

TUMOUR	BLACK		WHITE		BLACK: WHITE RATIO
	No.	%	No.	%	
RMS	10	90,9	1	9,1	10:1
BL	5	83,3	1	16,7	5:1
AML	2	66,7	1	33,3	2:1
NHL	2	100	-	-	-
MFH	2	100	-	-	-
OS	1	100	-	-	-
LMS	1	100	-	-	-
KS	1	100	-	-	-
MH	-	-	1	100	-
WT	1	100	-	-	-
MEC	1	100	-	-	-
TOTAL	26	86,7	4	13,3	6,5:1

Figure 5: RACIAL DISTRIBUTION

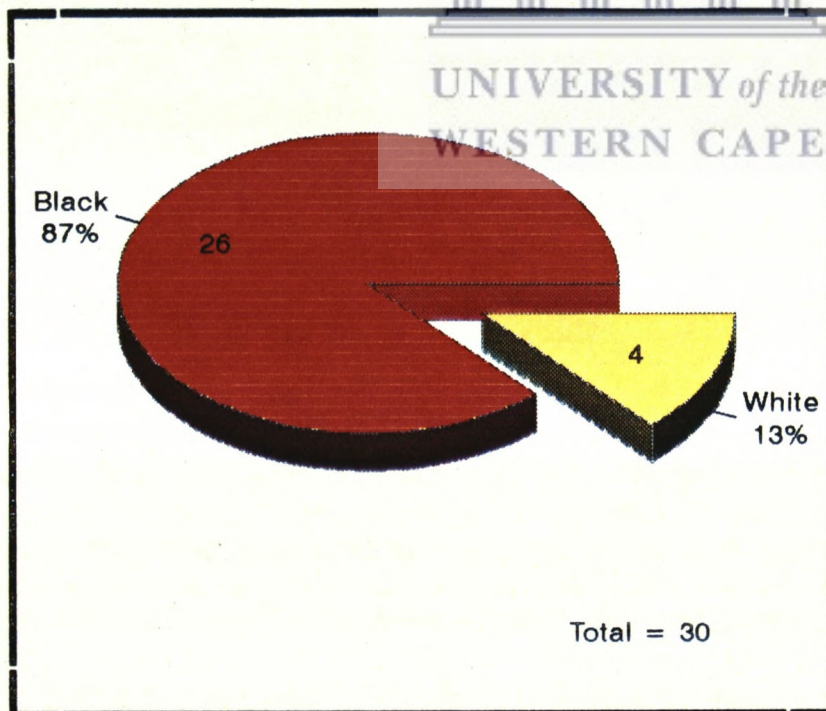
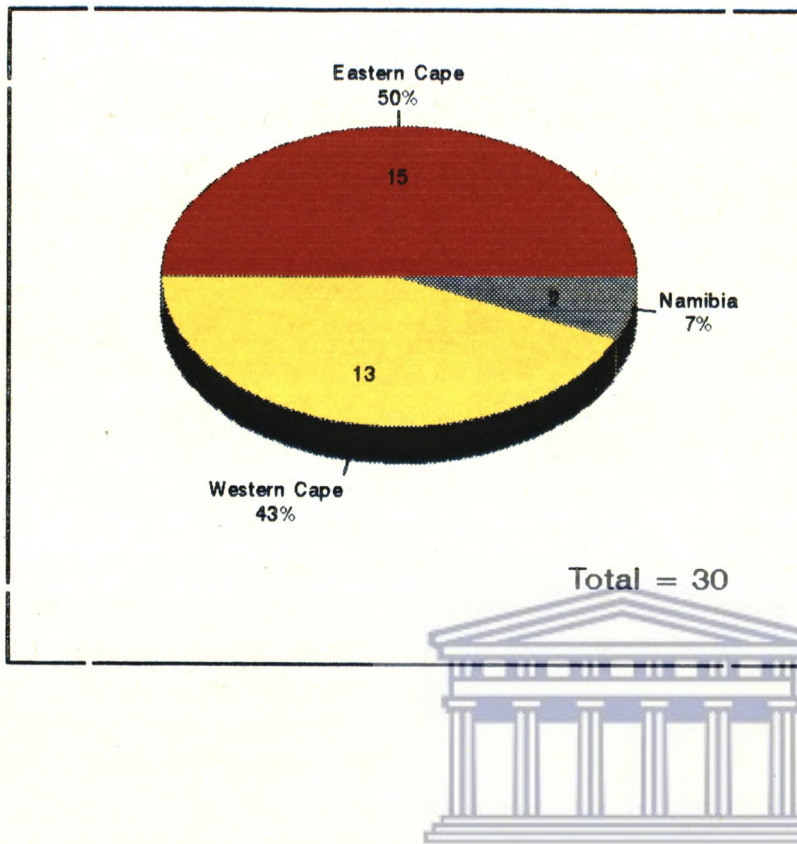


Figure 6: GEOGRAPHIC DISTRIBUTION



4.1.7 Anatomical site of lesion

The mandible and the maxilla were affected in 9 (30%) of the 30 cases. Only one case involved both jaws simultaneously. Five of the 9 patients had Burkitt's lymphoma. The cheek and soft tissues overlying the mandible were affected in 3 cases each. The chin was affected in one case and the nasolabial area in one case. Thus, the total number of tumours affecting the soft tissues of the face was 8 (26,7%).

Other sites of involvement included the palate (3 cases), tongue (2 cases), gingiva (2 cases), parotid gland (2 cases), maxillary sinus (2 cases), pterygopalatine fossa (1 case) and submandibular gland (1 case) (Table 8).

Table 8: SITE DISTRIBUTION

TUMOUR	ANATOMIC SITE													TOTAL	
	MANDIBLE	MAXILLA	MANDIBLE & MAXILLA	CHEEK	SOFT TISSUE MANDIBLE	CHIN	NLF	PALATE	TONGUE	GINGIVA	PAROTID GLAND	SUBMD GLAND	ANTRUM		PF
RMS				2	2	1	1	2	1				1	1	11
BL	2	2	1									1			6
AML	1	1							1						3
NHL				1							1				2
MFH					1								1		2
OS		1							1						1
LMS															1
KS										1					1
MH															1
WT	1														1
MFC														1	1
TOTAL	4	4	1	3	3	1	1	3	2	2	2	1	2	1	30
		9 (308)			8 (26,78)										

NLF - nasolabial fold
 SUBMD GLAND - submandibular gland
 PF - pterygoid fossa



4.1.8 Signs and symptoms

A painless swelling was the main complaint in 22 (73,3%) patients, while 4 (13,3%) patients complained of a painful swelling. Two patients with Burkitt's lymphoma complained of abdominal pain as a primary symptom and swelling of the face as a secondary symptom. One (3,3%) patient complained of bleeding "gums" and one (3,3%) patient sought treatment because of respiratory distress brought about by a large cervical mass. One patient with a rhabdomyosarcoma reported an increased growth rate of the swelling following a bout of measles, while another patient with a lymphoma reported an increased growth rate following trauma to the face. Ulceration of the skin or mucosa was produced by six tumours. Only two of these belonged to the group that complained of painful swellings.

Additional complaints included epistaxis (3 patients), purpuric lesions on the skin of the face and/or body (2 patients), mobile teeth (1 patient), and feeding difficulties due to a tongue mass (1 patient). Nine (30%) patients had an abdominal mass.

The teeth were affected in 6 (20%) of the 30 patients. Tumours produced displacement and/or mobility of the teeth. Only one patient was concerned about the mobile teeth, while the others were more concerned about the swelling. Of the 6 cases with mobile or displaced teeth, Burkitt's lymphoma accounted for 4 (66,7%), acute myeloid leukaemia accounted for 1 (16,7%) and Wilm's tumour accounted for 1 (16,7%).

The general health of the patients was good in 28 (93,3%) of the 30 cases, while in the remaining 2 (6,7%) the patients were found to have malaise, anorexia and weight loss. One of these was a patient with a rhabdomyosarcoma of the palate and the other was a patient with an acute myeloid leukaemia of the mandible. In the patient with Kaposi's sarcoma, both mother and child tested negative to HIV. The clinical presentation of the different tumours is shown in Table 9 and graphically represented in Figure 7.

Figure 7: CLINICAL PRESENTATION (PRIMARY COMPLAINTS)

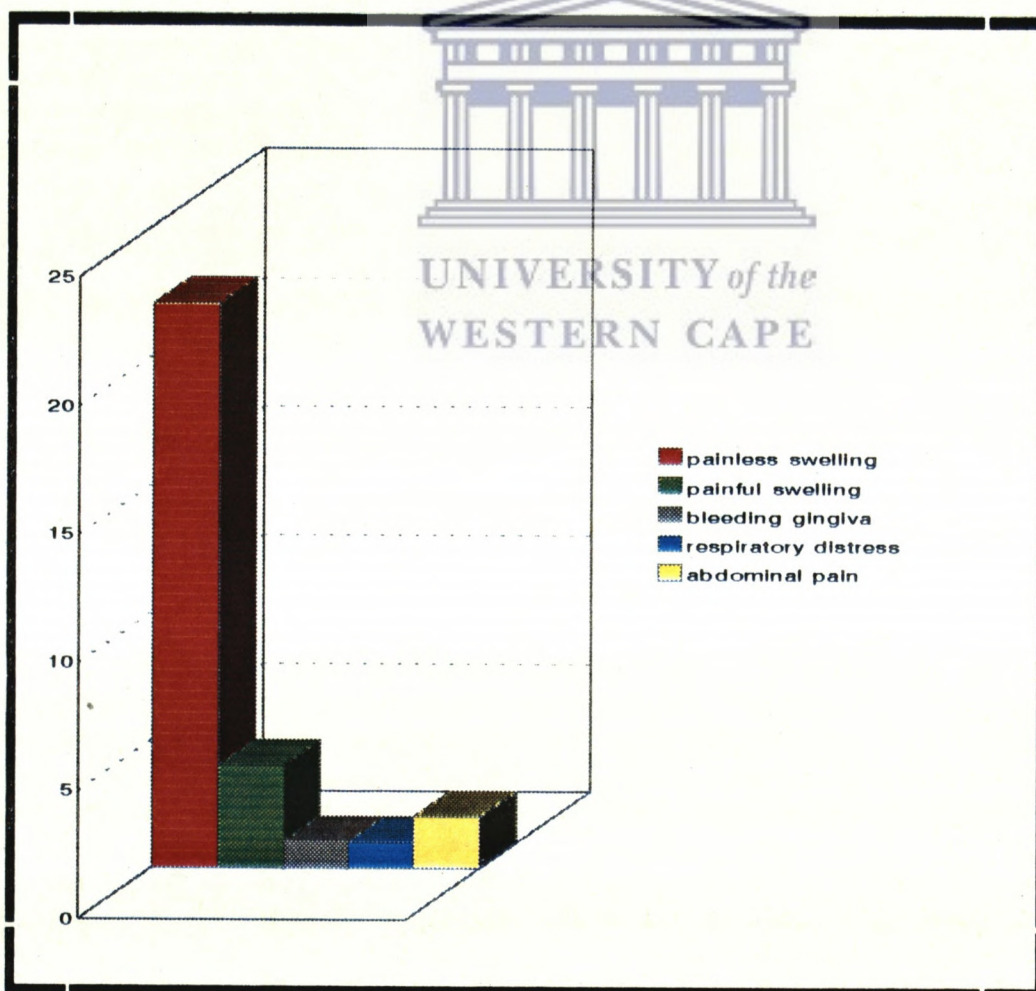


Table 9: CLINICAL PRESENTATION OF MALIGNANT PAEDIATRIC MAXILLOFACIAL AND ORAL TUMOURS

CLINICAL PRESENTATION	RMS	BL	AML	NHL	MFH	OS	LMS	KS	MH	WT	MEC	TOTAL
PRIMARY COMPLAINTS												
PAINLESS SWELLING	8	3	2	2	2	1		1	1	1	1	22
PAINFUL SWELLING	2	1					1					4
BLEEDING GINGIVA			1									1
RESPIRATORY DISTRESS	1											1
ABDOMINAL PAIN		2										2
TOTAL	11	6	3	2	2	1	1	1	1	1	1	30
SECONDARY COMPLAINTS												
EPISTAXIS			1	1	1							3
PURPURIC LESIONS			2									2
BLEEDING GINGIVA		1	1					1				3
MOBILE TEETH		4	1							1		6
ABDOMINAL MASS		6	1					1		1		9
FEEDING PROBLEMS	1											1
SWELLING	1	2										3
TOTAL	2	13	6	1	1			2		2		27



4.1.9 Duration of symptoms

The duration of symptoms was not recorded in 5 patients (3 rhabdomyosarcomas, 1 Burkitt's lymphoma, and 1 Kaposi's sarcoma). In the remaining 25 patients, the duration of symptoms ranged from one week to three years before seeking treatment. The mean duration of symptoms was 4,5 months. If 3 patients with a duration of one year or more are excluded, the mean duration of symptoms changes to 1,5 months with a range of one week to nine months (Table 10).

Table 10: DURATION OF SYMPTOMS

TUMOUR	RANGE	MEAN
RMS	3 weeks - 2 years	4,3 months
BL	1 week - 4 weeks	2,8 weeks
AML	1 week - 4 weeks	2,3 weeks
NHL	6 weeks - 3 years	1,6 months
MFH	2 weeks - 4 weeks	3,0 weeks
OS	-	1,0 month
LMS	-	5,0 months
KS	-	9,0 months
MH	-	1,0 month
WT	-	unknown
MEC	-	1 year

4.1.10 Radiographic features

Of the 27 (90%) children who had radiographs taken, 15 (59,3%) had radiographic evidence of bone involvement (Table 11). All of the tumours produced ill-defined radiolucent lesions, the margins of which were irregular. When the tumour involved the alveolus, there was displacement of erupted and unerupted teeth. Loss of

the lamina dura, widening of the periodontal ligament space and enlargement of the crypts of unerupted teeth were consistent findings in four patients with Burkitt's lymphoma, in one patient with a leukaemia and in one patient with a Wilm's tumour of the kidney that had metastasized to the mandible.

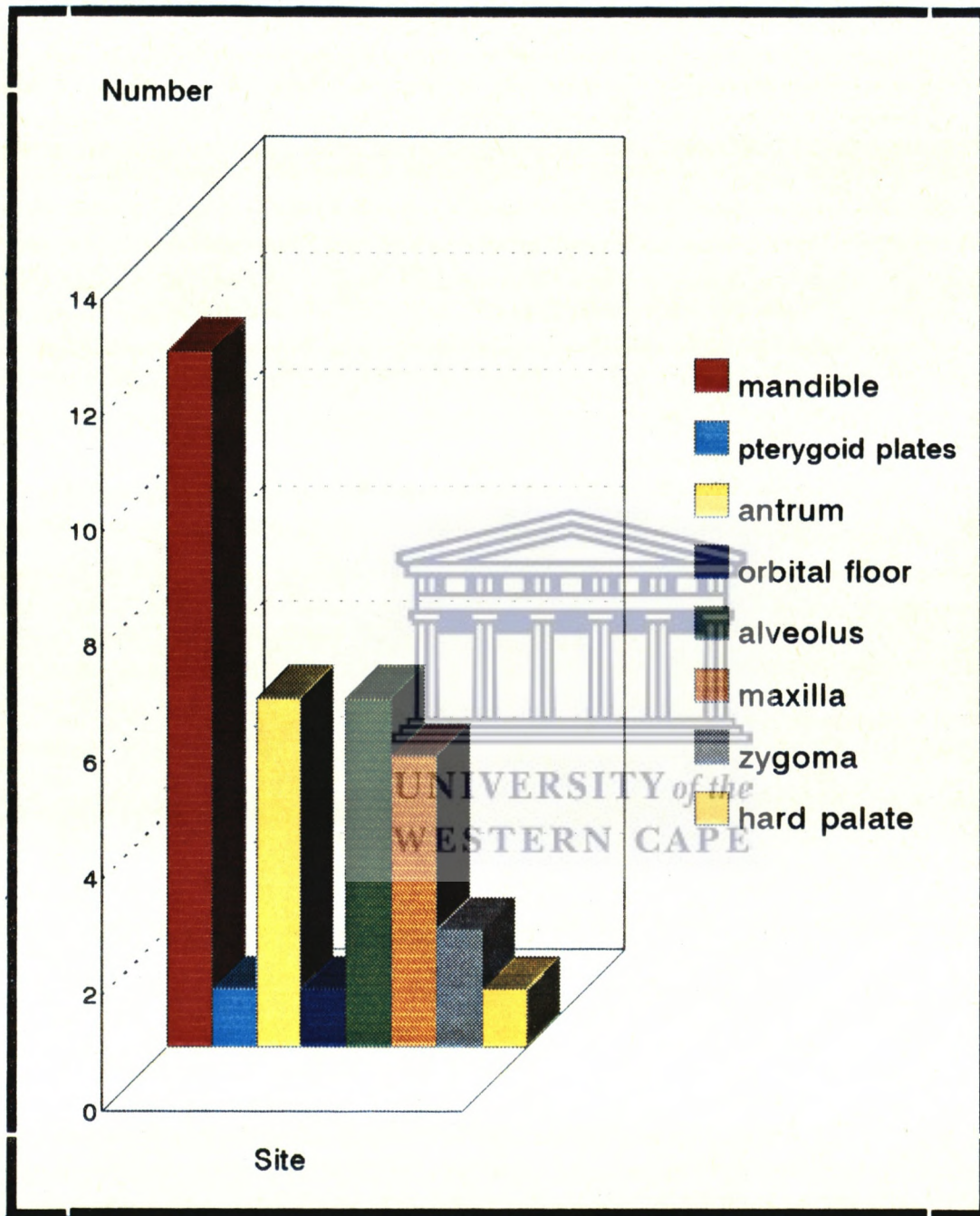
Computerised tomograms (CT Scan) had been performed in six patients only (3 rhabdomyosarcomas, 1 osteogenic sarcoma, 1 leukaemia, and 1 lymphoma). Two of these confirmed the absence of any bony involvement (1 rhabdomyosarcoma, and 1 lymphoma). Figure 8 shows the anatomic site distribution of the tumours as seen radiographically.



Table 11: RADIOGRAPHIC FINDINGS


TUMOUR	BONE INVOLVED	SITE OF PRIMARY LESION
RMS	<ul style="list-style-type: none"> * Superficial erosion of malar bone * Bone scan - increased uptake in ramus of mandible * Pterygoid plates, posterior wall of maxilla * Maxillary sinus, orbital floor - superiorly displaced * Symphysis of mandible 	<ul style="list-style-type: none"> Cheek Angle of mandible Pterygoid fossa Maxillary sinus Chin
BL	<ul style="list-style-type: none"> * Bilateral mandible (body, angle, alveolus, displaced teeth) * Bilateral mandible (body, angle, ramus displaced teeth) * Maxilla (displaced teeth) * Maxilla (anterior, antrum, zygoma, displaced teeth) * Mandible (body) Maxilla (anterior) Maxillary sinus Zygoma 	<ul style="list-style-type: none"> Mandible Mandible Maxilla Maxilla Mandible & Maxilla
AML	<ul style="list-style-type: none"> * Maxillary sinus * Mandible (body, symphysis, displaced teeth) 	<ul style="list-style-type: none"> Maxilla
MFH	<ul style="list-style-type: none"> * Maxillary sinus 	<ul style="list-style-type: none"> Maxillary sinus
OS	<ul style="list-style-type: none"> * Maxilla, palate, antrum 	<ul style="list-style-type: none"> Maxilla
MH	<ul style="list-style-type: none"> * Palatal bone 	<ul style="list-style-type: none"> Palate
WT	<ul style="list-style-type: none"> * Right mandible (ramus, body, displaced teeth) 	<ul style="list-style-type: none"> Right kidney

Figure 8: ANATOMIC SITE (SEEN RADIOGRAPHICALLY)



4.1.11 Treatment

Of the 11 patients with rhabdomyosarcomas, 4 (36,4%) were treated using a combination of surgery, radiotherapy and chemotherapy, 4 (36,4%) were treated with radiotherapy and chemotherapy, 2 (18,2%) were treated with surgery and chemotherapy and 1 (9,1%) was treated with chemotherapy only. Before 1977, chemotherapy protocols consisted of vancomycin, actinomycin and cyclophosphamide. After 1977, chemotherapy consisted of vancomycin, actinomycin and cyclophosphamide (VAC) or VAC plus adriamycin and/or endoxan. Patients diagnosed after 1977 were treated according to the IRS protocol (Figure 1) (Maurer *et al.*, 1977).



Of the 6 patients with Burkitt's lymphoma, 4 (66,7%) were treated using a combination of surgery, radiotherapy and chemotherapy, one (16,7%) with radiotherapy and chemotherapy and one (16,7%) with chemotherapy only. Treatment in the remaining cases is shown in Table 12. The chemotherapeutic agents used for the various tumour types is shown in Table 13.

Nine (30%) patients were treated by a combination of surgery, radiotherapy and chemotherapy, 5 (16,7%) with radiotherapy and chemotherapy, 7 (23,3%) with surgery and chemotherapy, 1 (3,3%) with surgery and radiotherapy, and 8 (26,7%) patients were treated with chemotherapy only. All patients received chemotherapy, except the patient with a leiomyosarcoma of the tongue. Treatment in this patient consisted of surgery and radiotherapy.

Table 12: TREATMENT

TUMOUR	S R C		R C		S C		S R		C		TOTAL
	No.	%	No.	%	No.	%	No.	%	No.	%	
RMS	4	36,4	4	36,4	2	18,2			1	9,1	11
BL			1	16,7	4	66,7			1	16,7	6
AML									3	100	3
NHL									2	100	2
MFH	2	100									2
OS					1	100					1
LMS							1	100			1
KS									1	100	1
MH	1	100									1
WT	1	100									1
MEC	1	100									1
TOTAL	9	30	5	16,7	7	23,3	1	3,3	8	26,7	30

S = Surgery R = Radiotherapy C = Chemotherapy

Table 13: CHEMOTHERAPEUTIC AGENTS

TUMOUR	DRUGS
RMS	VAC, adriamycin, endoxan
BL	Vincristine, prednisone, endoxan, methotrexate, adriamycin
AML	Retinoic acid + polychemotherapy
NHL	Prednisone, cyclophosphamide, vincristine, methotrexate
MFH	Actinomycin, vincristine, endoxan
OS	Cisplatinum, adriamycin, doxyrubicin
LMS	Nil
KS	Polychemotherapy
MH	VAC
WT	Vincristine, actinomycin
MEC	Nil

VAC - Vancomycin
 - Actinomycin
 - Cyclophosphamide

4.1.12 Survival

Follow-up information was not recorded in one patient. The mean period of follow-up for the remaining 29 patients with a malignancy of the maxillofacial and oral region was 3,6 years, with a range of one month to 15 years and a median of 2 years. At the time of writing this dissertation, 15 (51,7%) patients were alive with no evidence of disease. Thus 14 (47%) patients died as a result of their disease (Figure 9; Table 14). Nine (31%) patients died within the first year of being diagnosed. Seventeen (58,6%) patients survived for a period of two years or longer, while 6 (20,7%) patients survived for a period of five years or more. Only 4 (13,8%) patients had survived for a period of 10 years or longer. The two longest survivors have remained disease-free for a period of 15 years. Both were treated for a rhabdomyosarcoma, one with a combination of chemotherapy and surgery and the other with a combination of chemotherapy, surgery and radiotherapy.

The most common method of treatment for patients who had survived their disease, was a combination of surgery and chemotherapy, while a combination of surgery, chemotherapy and radiotherapy, was the most common form of treatment in patients who had succumbed to their disease.

Figure 9: RESULT OF TREATMENT

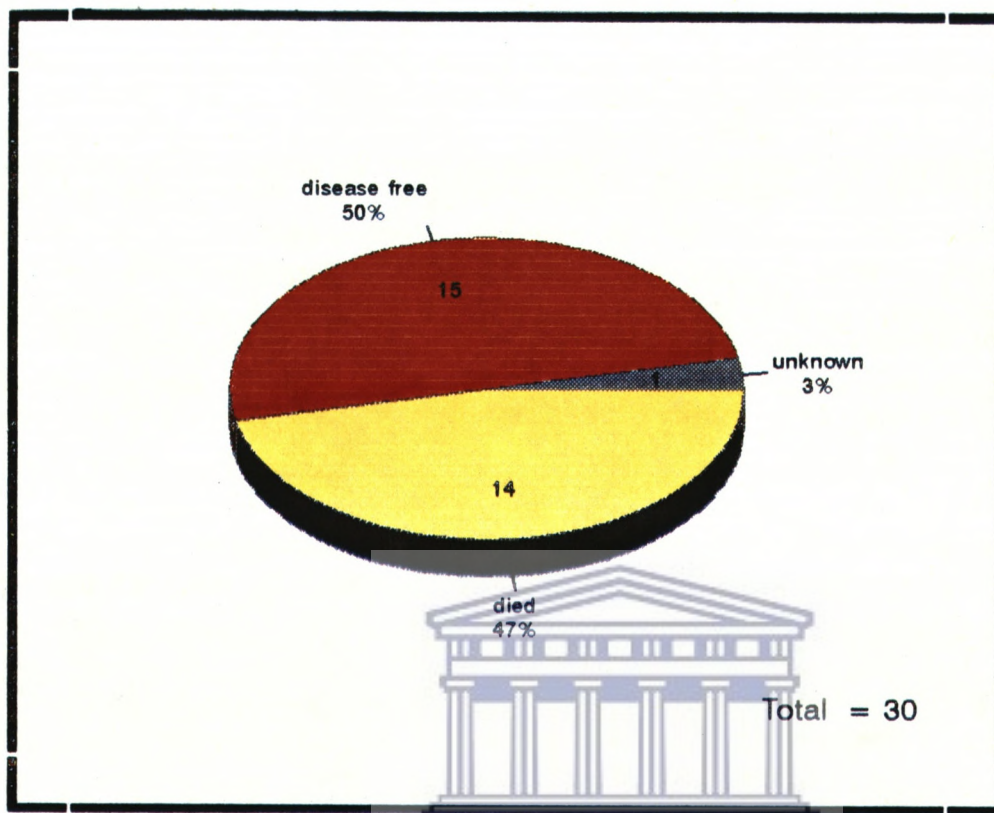


Table 14: RESULT OF TREATMENT CAPE

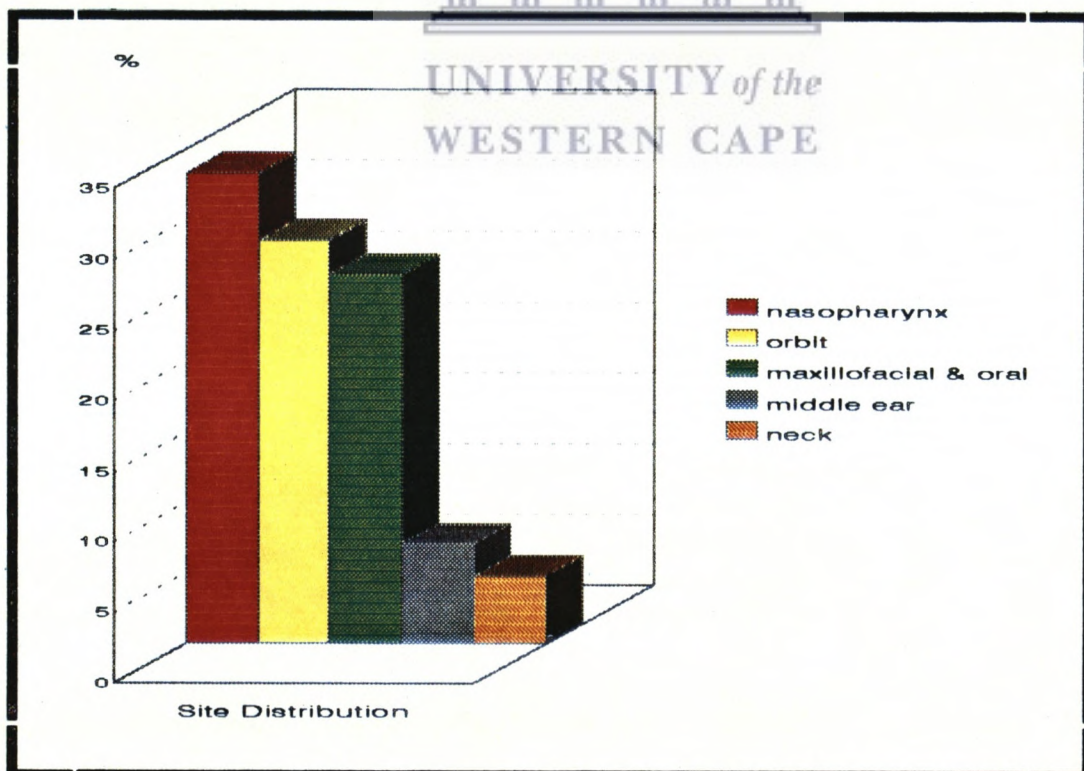
TUMOUR	RESULT						TOTAL
	UNKNOWN		DISEASE-FREE		DIED		
	No.	%	No.	%	No.	%	
RMS			4	36,4	7	63,6	11
BL			5	83,3	1	16,7	6
AML			2	66,7	1	33,3	3
NHL			1	50	1	50	2
MFH					2	100	2
OS			1	100			1
LMS			1	100			1
KS					1	100	1
MH			1	100			1
WT					1	100	1
MEC	1	100					1
TOTAL	1	3,3	15	50	14	46,7	30

4.2 Analysis of rhabdomyosarcoma series

4.2.1 Distribution of head and neck cases

A total of 42 children with rhabdomyosarcoma of the head and neck were found in the archival material over the 20 year period from 1973-1993. The distribution of cases in the head and neck was as follows: nasopharynx 14 cases (33,3%); orbit 12 cases (28,6%), maxillofacial and oral region 11 cases (26,2%); middle ear 3 cases (7,1%) and soft tissues of the neck 2 cases (4,8%) (Figure 10). One case of a pleomorphic rhabdomyosarcoma of the maxillary antrum was reclassified as a malignant fibrous histiocytoma and was therefore excluded from the series of rhabdomyosarcomas.

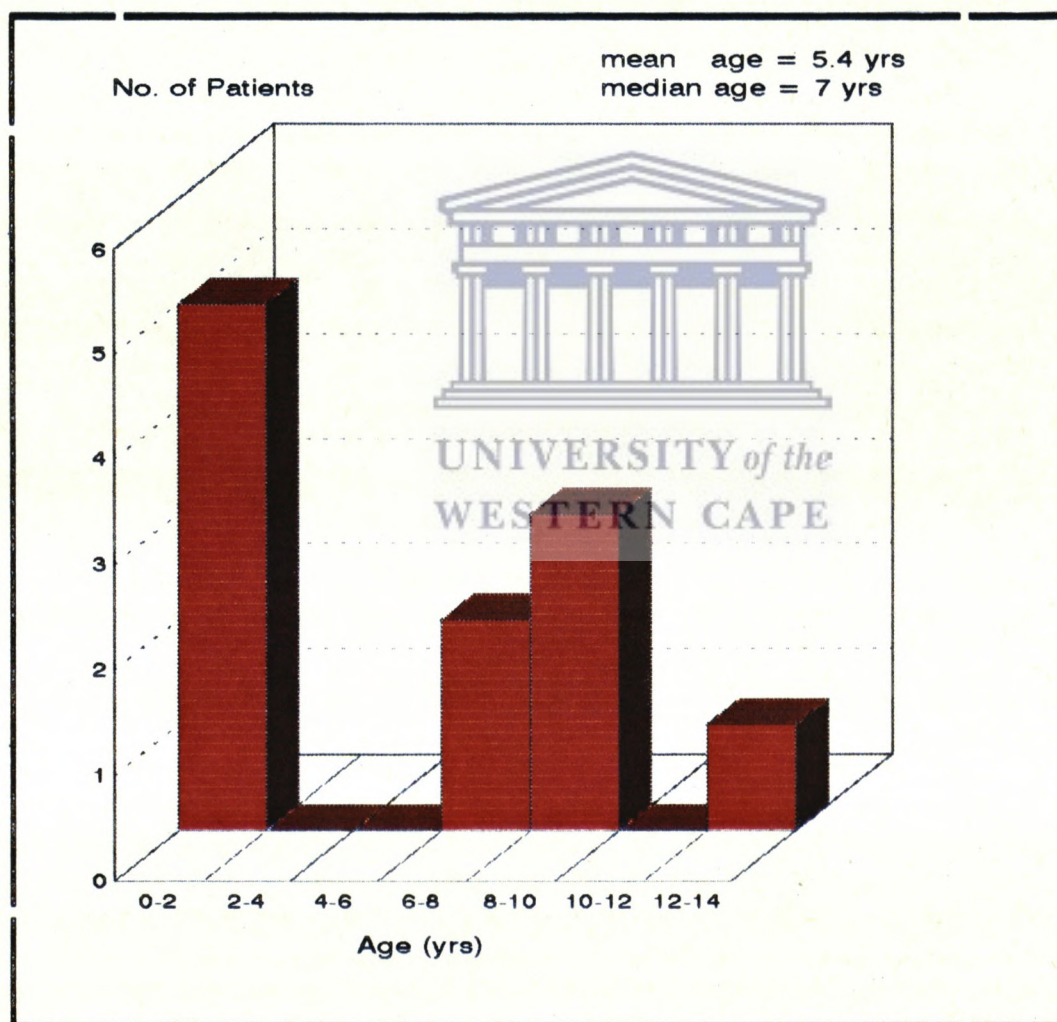
Figure 10: DISTRIBUTION OF HEAD AND NECK RHABDOMYOSARCOMAS



4.2.2 Age, gender and race

The age frequency of rhabdomyosarcoma in the maxillofacial and oral region is shown in Figure 11. The age at the time of diagnosis ranged from 6 months to 13 years, with a median age of 7 years and a mean age of 5,4 years. There were 6 females and 5 males. All the patients, but one, were black.

Figure 11: AGE DISTRIBUTION (RHABDOMYOSARCOMA)



4.2.3 Geographic distribution

The geographic distribution of the 11 patients is shown in Table 15.

Table 15: GEOGRAPHIC DISTRIBUTION

REGION	PERCENTAGE
Eastern Cape	54,5 (6)
Western Cape	27,3 (3)
Namibia	18,2 (2)

4.2.4 Clinical stage

Patients diagnosed before 1975 were retrospectively classified into clinical disease groups I-IV as defined by the Intergroup Rhabdomyosarcoma Study (Maurer et al., 1975) (Table 2).

The classification of patients according to the Intergroup Rhabdomyosarcoma Study is shown in Table 16.

Table 16: CLINICAL STAGE - RHABDOMYOSARCOMA

STAGE	PERCENTAGE
Group I	9,1 (1 case)
Group II	9,1 (1 case)
Group III	72,2 (8 cases)
Group IV	9,1 (1 case)

4.2.5 Anatomical site of lesion

The distribution of tumours by primary site is shown in Table 17.

Table 17: ANATOMICAL SITE - RHABDOMYOSARCOMA

SITE OF LESION	NUMBER OF CASES
soft palate	2
cheek	2
angle of mandible (soft tissues)	2
tongue	1
pterygoid fossa	1
maxillary antrum	1
nasolabial fold	1
chin and anterior mandible	1

The distribution of intra-oral and/or extra-oral manifestations was as follows: Four cases (36,4%) had only manifested in the extra-oral soft tissues (angle of mandible 2 cases; cheek 1 case; nasolabial fold 1 case), three cases (27,2%) had only manifested in the intra-oral tissues (soft palate 2 cases; tongue 1 case), while four cases (36,4%) had both extra-oral and intra-oral involvement (cheek 1 case; pterygoid fossa 1 case; maxillary antrum 1 case; chin 1 case).


4.2.6 Signs and symptoms

In 10 of the 11 cases (90,9%) the main complaint was a painless swelling. Only one case (9,1%) presented as a painful swelling. The case involving the tongue presented for treatment because of difficulty with feeding due to a painless swelling. One case presented with respiratory distress as a result of airway obstruction produced by a progressively enlarging neck mass

(primary site in palate). An emergency tracheostomy had to be performed in this case.

In all of the tumours that presented with a swelling, whether painless or painful, the swelling was described as a rapidly growing mass, save for one case where the mass was present for two years before seeking treatment. This case represented the only congenital rhabdomyosarcoma (primary site in soft tissues at angle of mandible).

One case exhibited an increased growth rate of the swelling following a bout of measles. In none of the cases was the mass preceded by trauma. The general health was good in all but one patient who presented in respiratory distress and had an emaciated appearance.



4.2.7 Duration of symptoms

In three cases the duration of symptoms were not recorded. In the remaining eight cases the duration of symptoms ranged from three weeks to two years, with a mean of 4,3 months. If one case with an extremely long duration of two years is disregarded, then the range for the remaining 10 cases is from 3-12 weeks, with a median of 4 weeks and a mean duration of 5,9 weeks.

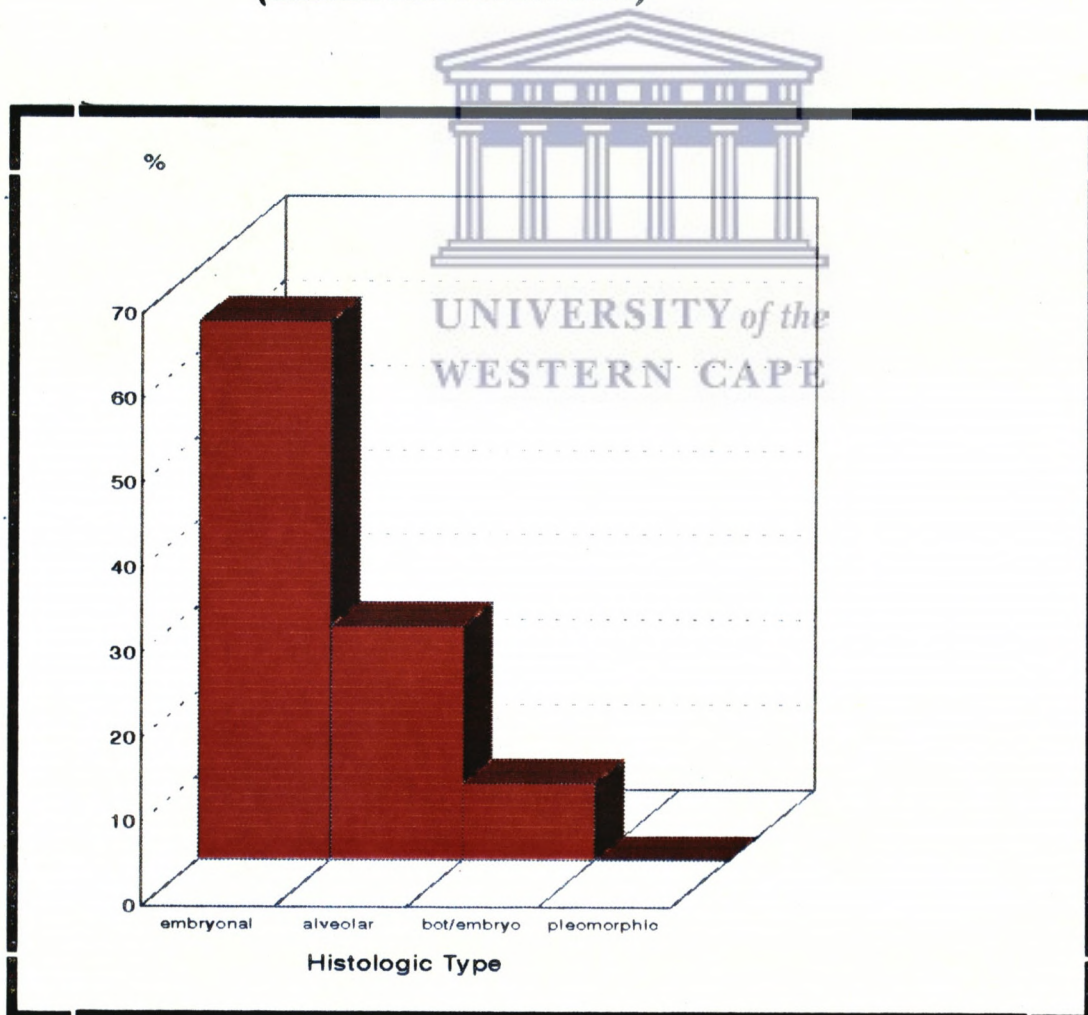
4.2.8 Cervical lymph node involvement and metastases

Six (54,5%) cases had cervical lymph node involvement at the time of diagnosis, while only one case had distant metastases (lungs and bone marrow) at the time of diagnosis.

4.2.9 Histopathology

Histologically, the most common variety of rhabdomyosarcoma was the embryonal form, representing 63,6% of the total number, followed by the alveolar rhabdomyosarcoma (27,3%) and the botryoid/embryonal rhabdomyosarcoma (9,1%). The more adult type of pleomorphic rhabdomyosarcoma did not feature in this series. The distribution of patients by histologic type is shown in Figure 12.

**Figure 12: DISTRIBUTION BY HISTOLOGIC TYPE
(RHABDOMYOSARCOMA)**



4.2.10 Radiographic features

Five (45,5%) out of the 11 patients had radiologic evidence of bony involvement. The radiographic findings in these five cases is summarized in Table 15. The case involving the soft tissues of the chin had a large radiolucent lesion in the anterior mandible. The case involving the pterygoid fossa revealed displacement of the mandible and posterior wall of the maxillary sinus. In all cases, the radiologic features revealed poorly defined, "moth eaten" radiolucent lesions.

Table 18: RADIOGRAPHIC FEATURES OF RHABDOMYOSARCOMAS

<i>SITE OF LESION</i>	<i>RADIOGRAPHIC FEATURES</i>
Cheek	Superficial erosion of malar bone.
Pterygoid fossa	Displacement and erosion of pterygoid plates and posterior wall of maxilla.
Maxillary sinus	Obliteration of maxillary sinus, erosion of bony walls of maxillary sinus and superior displacement of orbital floor.
Symphysis (soft tissue)	Radiolucent lesion in anterior mandible.
Angle of mandible (soft tissue)	Scintiscan - increased uptake of Technetium 99 in ramus of mandible.

4.2.11 Treatment

In all cases treatment consisted of a combination of surgery, chemotherapy and radiotherapy. In the 3 cases diagnosed before 1977, chemotherapy consisted of actinomycin and vincristine. The remaining 8 cases diagnosed since 1977 were treated according to the IRS protocol (Maurer *et al.*, 1977). Chemotherapy in these cases consisted of vancomycin, actinomycin and cyclophosphamide (VAC) or VAC plus adriamycin and/or endoxan.

4.2.12 Survival

"Survival time" is defined as the time lapse from initial diagnosis until death related to disease (Dito and Batsakis, 1962). The mean duration of follow-up for this group of patients was 3,8 years with a range of six months to 15 years and a median of 2 years. Four of the 11 (36,4%) patients were alive with no evidence of disease after a mean follow-up time of 8,6 years (range 2-15 years). Two out of the 4 patients were alive with no evidence of disease 15 years after diagnosis.

In contrast, 7 patients died after a mean survival time of one year (range 6 months to 2,2 years). Three of the 7 died as a result of local recurrence, while 4 died due to metastatic disease. The lungs, bone marrow and central nervous system were the major sites of metastases.

UNIVERSITY of the

4.3 Analysis of Burkitt's lymphoma series

4.3.1 Incidence

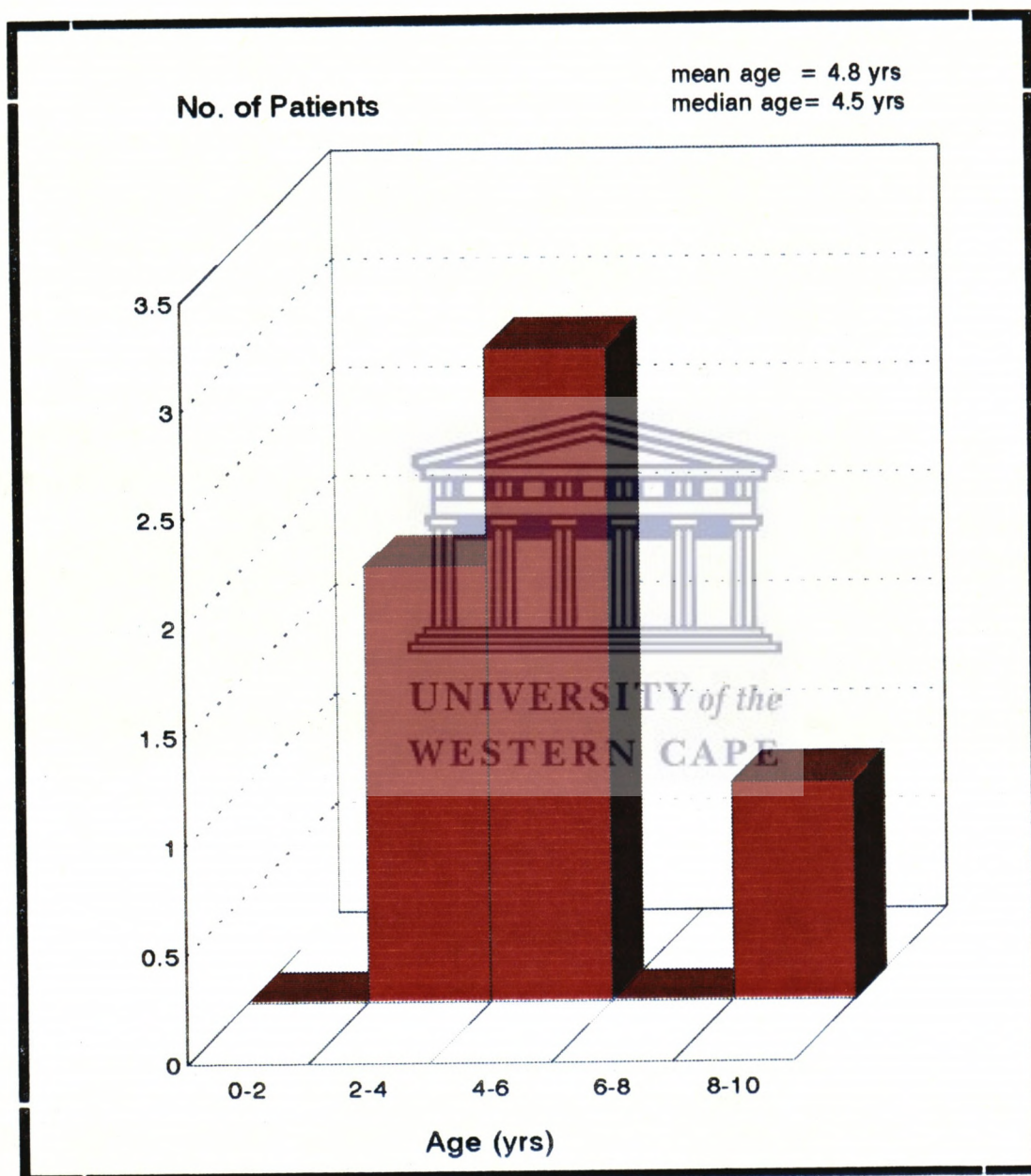
Of the 30 childhood maxillofacial and oral malignancies analysed over a 20 year period, 6 were found to be Burkitt's lymphoma. This represented 20% of the total number and represented the second most common malignant tumour in children.

4.3.2 Age, gender and race

The ages ranged from 3-8 years with a mean age of 4,8 years and a median of 4,5 years (Figure 13). The only case involving a White patient was 8 years old at the time of diagnosis. There were 3 male patients and 3 female patients. There were five black

patients and one white patient.

Figure 13: AGE DISTRIBUTION (BURKITT'S LYMPHOMA)



4.3.3 Geographic distribution

All of the patients were from the Cape Province, which is characterised by winter rainfall. None of the patients resided in areas more than 5,000 feet in altitude.

4.3.4 Seasonal pattern

Only two of the six (33,3%) patients had their first symptoms in winter months.

4.3.5 Anatomical site of lesion

Of the six cases, two had affected the mandible only while two had affected the maxilla only. One case had affected the mandible and maxilla simultaneously. The remaining case occurred in the submandibular region with no bony involvement.

4.3.6 Signs and symptoms

In four of the six (66,7%) cases, the main complaint was a rapidly growing painless swelling of the jaw or face. In two (33,3%) cases, the patients complained of abdominal pain as well as a swelling of the face. Three (50%) of the patients also complained of mobile teeth in addition to swelling. All six patients had maxillofacial as well as abdominal involvement.

4.3.7 Duration of symptoms

The duration of symptoms ranged from 3 days to 4 weeks, with a mean duration of 2,1 weeks. In one case, the duration of symptoms was not recorded.

4.3.8 Histopathology

Histologically, all the cases revealed typical features of Burkitt's lymphoma, save for one case. This case did not reveal the classical "starry-sky" appearance, but consisted of sheets of undifferentiated lymphoreticular cells. Jaw lesions were microscopically indistinguishable from lesions at other sites.

4.3.9 Immunocytochemistry

Four patients were tested for antibodies (IgG and IgM) and Epstein-Bar virus viral core antigen with the use of indirect immuno-fluorescent techniques. Two patients tested positive for antibodies against Epstein-Bar virus, and two tested positive for viral core antigen.

4.3.10 Radiographic features

Five of the six (83,3%) patients had radiographic evidence of bony involvement. Radiographic features included moth-eaten radiolucencies, loss of the lamina dura around the teeth, early loss of primary teeth, teeth floating in space, and enlargement of crypts of developing teeth. Lesions in the maxilla had produced opacification of the maxillary antrum and erosion of the zygoma in two cases. One case involving the mandible exhibited erosion of the pituitary fossa and sphenoid bone.

4.3.11 Treatment

In five of the six cases, the primary mode of therapy consisted of surgery (laparotomy) and chemotherapy. Radiotherapy was used as an adjunct to chemotherapy in one case. Chemotherapy consisted

of a combination of vincristine, prednisone, endoxan, adriamycin and methotrexate (B-cell leukaemia protocol).

4.3.12 Survival

The mean duration of follow-up for this group of patients was 7,4 years, with a range of 3,6-13 years and a median of 7,6 years. Only one patient died after a survival time of 13 years. Death was due to recurrent disease. The remaining five patients were alive with no evidence of disease after a mean follow-up time of 6,6 years (range 3,6-11,10 years).



DISCUSSION

- 5.1 Discussion on entire series
 - 5.1.1 Incidence
 - 5.1.2 Histopathology
 - 5.1.3 Age, gender and race
 - 5.1.4 Geographic distribution
 - 5.1.5 Anatomical site of lesion
 - 5.1.6 Signs and Symptoms
 - 5.1.7 Duration of symptoms
 - 5.1.8 Radiographic features
 - 5.1.9 Treatment
 - 5.1.10 Survival
- 5.2 Discussion: Rhabdomyosarcomas
 - 5.2.1 Aetiology
 - 5.2.2 Histologic classification
 - 5.2.3 Age
 - 5.2.4 Gender
 - 5.2.5 Race
 - 5.2.6 Geographic distribution
 - 5.2.7 Anatomical site of lesion
 - 5.2.8 Signs and symptoms
 - 5.2.9 Duration of symptoms
 - 5.2.10 Clinical stage
 - 5.2.11 Radiographic features
 - 5.2.12 Treatment
 - 5.2.13 Survival
- 5.3 Discussion: Burkitt's lymphoma
 - 5.3.1 Age



- 5.3.2 Gender
- 5.3.3 Race
- 5.3.4 Geographic distribution
- 5.3.5 Anatomical site of lesion
- 5.3.6 Signs and symptoms
- 5.3.7 Duration of symptoms
- 5.3.8 Histopathology
- 5.3.9 Radiographic features
- 5.3.10 Treatment
- 5.3.11 Survival
- 5.3.12 Pathogenesis of jaw lesions



UNIVERSITY *of the*
WESTERN CAPE

5.1 Discussion on entire series

5.1.1 Incidence

In the present study, 352 children were treated for a malignant tumour of the head and neck over a 20 year period. Thirty or 8,5% occurred in the maxillofacial and oral region. Sutow (1964) analysed 210 malignant tumours of the head and neck in children over a 17 year period. Only 3,3% of the cases had maxillofacial and oral involvement. Jaffe and Jaffe (1973) reported on 178 paediatric head and neck tumours over a 10 year period and found 14% of the tumours in the maxillofacial and oral region.

The small number of cases reported in this study and in the literature is an indication of the infrequency with which malignant tumours involve the maxillofacial and oral region in children aged 15 years or younger. Another possible reason for the small number of cases seen in this study may be due to the fact that the data for this study was obtained from only one of the two major academic hospitals in the Western Cape, viz. Groote Schuur Hospital (with Red Cross War Memorial Children's Hospital regarded as the paediatric wing of Groote Schuur Hospital). The other major academic hospital is Tygerberg Hospital, which also treats patients from the Cape Province and Namibia, but falls under the auspices of another university.

5.1.2 Histopathology

The rhabdomyosarcoma was found to be the most common malignant tumour of the maxillofacial and oral region in children 15 years and younger, representing 36,7% (11) of the total number. This

was followed by Burkitt's lymphoma, which represented 20% (6) of the total number. Acute myeloid leukaemia was the third most common malignant tumour representing 16% (3) of the total number, followed by the T-cell lymphoma and malignant fibrous histiocytoma (Figure 14), each representing 6,7% (2) of the total number of cases. There was one case each of an osteogenic sarcoma, leiomyosarcoma, Kaposi's sarcoma, malignant histiocytosis, Wilm's tumour and a mucoepidermoid carcinoma (Figure 15), each representing 3,3% of the total number and collectively representing 19,8% of the total number of cases (Table 4).

The majority of tumours were mesenchymal in origin. There were no malignant odontogenic tumours in this series. This is consistent with published findings that paediatric maxillofacial and oral tumours are usually non-odontogenic and mesenchymal in origin (Asamoah *et al.*, 1990). About 71% of childhood malignancies are sarcomas. In children, the sarcomas are regarded as the most common malignancy of the oral cavity (Christensen, 1979).

5.1.3 Age, gender and race

The ages of the patients at the time of diagnosis ranged from 6 months to 13,8 years, with a mean age of 5,7 years. Most of the tumours (60%) occurred in the first 6 years of life. Tumours were least common in the 10-12 year age group and were rare after 14 years of age (Figure 6). Asamoah *et al.* (1990) reported a mean age of 7,4 years and an age range of 2-4 years for malignant jaw

Figure 14: MALIGNANT FIBROUS HISTIOCYTOMA

Tumour composed of spindle cells arranged in a storiform pattern. (H AND E, X25).

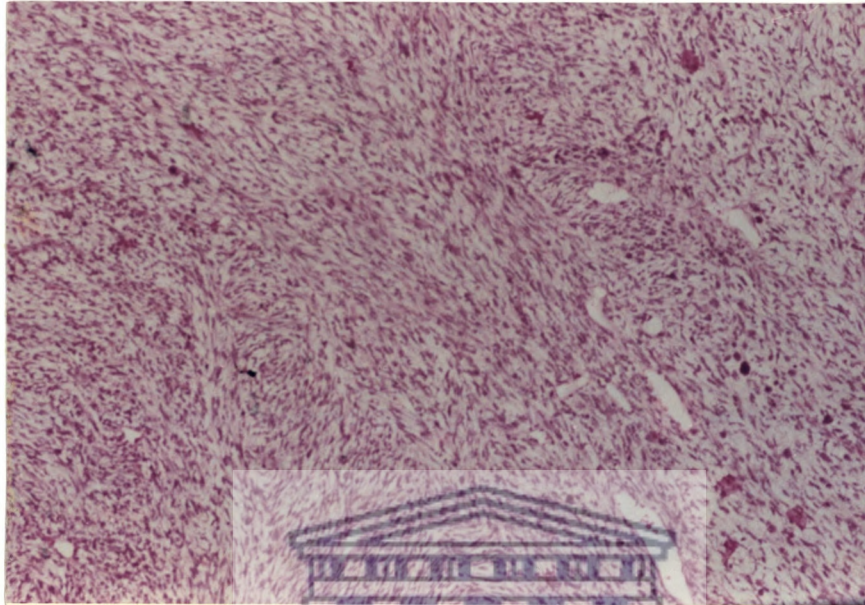
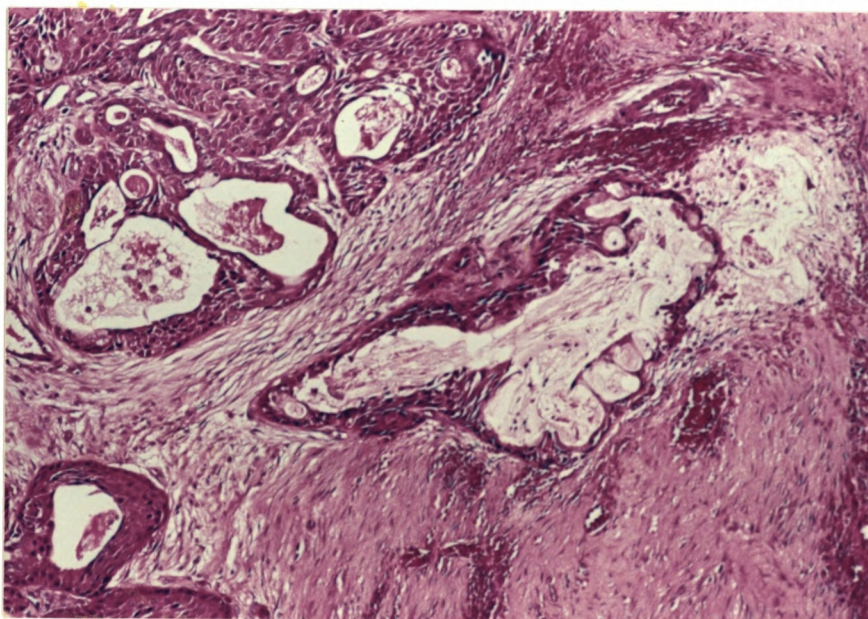


Figure 15: LOW-GRADE MUCOEPIDERMOID CARCINOMA

Tumour composed of pale mucous-secreting cells and epidermoid cells. (H AND E, X25).



tumours. Chuong and Kaban (1985) reported an average age of 11,8 years. The findings of the present study is supported by Karabus and Hartley (1987) who found that the incidence of malignancy in the first five years of life was greater than in the subsequent ten years.

The 0-2 year age group represents the period when the deciduous teeth erupt. It is, however, difficult to prove a relationship between tumour development and tooth eruption as the second most common age group (8-10 years) is a period during which tooth eruption is quiescent. It is therefore more likely that prenatal influences were responsible for the development of these tumours and that environmental carcinogens had a minor role to play. The nature of these prenatal influences is as yet unknown and could form the subject for another study. There was, however, only one congenital tumour, a rhabdomyosarcoma that was present at birth but only diagnosed at the age of two years.

There was a slight male predominance with a male to female ratio of 1,3:1 (Table 6). Asamoah *et al.* (1990) found a male to female ratio of 2:1. Dehner (1973) found an equal gender distribution. The literature therefore is not unanimous as regards gender distribution.

The majority of patients (86,7%) in this study were blacks. The black to white ratio was 6,5:1. The literature dealing with the subject of oral and maxillofacial tumours in children provide little information on the racial distribution of these tumours

(Dehner, 1973; Chuong and Kaban, 1985; Asamoia *et al.*, 1990). It is well known that jaw involvement in African Burkitt's lymphoma, which affects mainly blacks, is common, whereas jaw involvement in American Burkitt's lymphoma, which affects mainly whites, is uncommon (Hesseling, 1989). In this study, 83,3% of the patients with Burkitt's lymphoma were black. Similarly 90,9% of the rhabdomyosarcomas and 66,7% of the leukaemias occurred in black patients. The only other case to have involved a white patient was the case of a malignant histiocytosis (Table 7).

5.1.4 Geographic Distribution

Most of the patients in this study were from the Eastern Cape, followed by the Western Cape and Namibia (Figure 8). Most of the patients with rhabdomyosarcomas were from the Eastern Cape (including Transkei) while most of the patients with Burkitt's lymphoma were from the Western Cape.

5.1.5 Anatomic Site of Lesion

In the present study, the mandible and maxilla were found to be the most prevalent sites. This represented 30% of the total number of cases (Table 8). The soft tissues of the face were found to be the second most common site of involvement (26,7%). This included the cheek, chin, nasolabial fold area and soft tissues overlying the mandible. In this study cheek tumours represented primary tumours arising from the soft tissues of the cheek. Jaffe (1973) stated that a cheek tumour could represent a primary tumour of the soft tissues of the cheek, but could also represent a primary tumour arising in the maxillary bone,

maxillary antrum, pterygoid fossa or infra-temporal fossa. Hence, the importance of the topography of a cheek tumour.

Intra-oral tumours, as a group, were more common than extra-oral tumours. The most common intra-oral site was found to be the palate. The only intra-oral site not affected by a malignancy was the floor of the mouth. The floor of the mouth in children therefore, appears to be resistant to the effects of carcinogens, unlike adults. This finding is supported by the fact that none of the cases reported in the literature had floor of mouth involvement (Bhasker, 1963; Sutow, 1964; Jaffe and Jaffe, 1973 and Peters *et al.*, 1989).

This study, therefore, confirms the findings in the literature that site predilections of childhood malignancies in the maxillofacial and oral region is not well established. Jaffe (1973) found the cheek to be the most common site of involvement, followed by the mandible and the intra-oral soft tissues respectively. Bhasker (1963) found the oral soft tissues and the tongue to be the most common sites of involvement.

Although rhabdomyosarcomas involved the soft tissues of the maxillofacial and oral region exclusively, with bony involvement being a secondary phenomenon, none of these sites had a greater predilection for the occurrence of a rhabdomyosarcoma than any other site. The mandible and maxilla were the most common sites for the occurrence of Burkitt's lymphoma. Multiple quadrant involvement was a common finding.

In this study all of the three cases of leukaemia had oral involvement, two of which involved the jaws, while the third case involved the gingiva. Oral manifestations in leukaemia in the form of jaw and gingival lesions, is not an uncommon finding (Dehner, 1973).

Of the two cases of malignant fibrous histiocytoma in this study, one occurred in the maxillary antrum with destruction of the maxilla, while the other occurred in the facial soft tissues. Malignant fibrous histiocytoma has been reported as occurring in the soft tissues in the rest of the body, whereas in the maxillofacial and oral region they most often occur centrally within the maxilla or mandible (Shafer *et al.*, 1983).

Most lymphomas first present in the cervical lymph nodes. The most common site of origin of primary extranodal lymphoma in the head and neck is Waldeyer's ring. Less frequent sites of involvement include the palate, oropharynx, larynx, salivary glands and jaws (Shafer *et al.*, 1983). The present study yielded two cases of non-Hodgkins lymphoma. One presented in the cheek and upper lip while the other presented in the parotid gland. None had oral involvement.

The only case of an osteosarcoma occurred in the maxilla. The literature, however, seems to indicate that mandibular involvement is more common than maxillary involvement (Shafer *et al.*, 1983).

Leiomyosarcomas have been reported as occurring on the tongue, cheek, floor of mouth and rarely centrally within the mandible (Shafer *et al.*, 1983). In this study, the single case of a leiomyosarcoma occurred on the dorsal surface of the tongue.

Three patterns of Kaposi's sarcoma have emerged since it was first described by Kaposi in 1872. In the classic form described in mediterranean people, it occurs primarily in the skin of the lower extremities, with oral lesions being rare. In the second type, the skin of the extremities is the most common site to be affected, while oral lesions are rarely encountered. This type has been identified in Africa where the condition is endemic. In the third type, where Kaposi's sarcoma has been seen in patients with AIDS and other conditions associated with immunodeficiency, oral lesions are common (Regezi and Sciubba, 1989). In this study there was only one case of a Kaposi's sarcoma that presented with a gingival mass and cervical lymphadenopathy. It is interesting to note that this patient as well as the mother were both found to be HIV negative. Skin involvement was absent.

The only case of a malignant histiocytosis in this study involved the palate and cervical lymph nodes. Malignant histiocytosis may affect several intra-oral sites including the jaws and gingiva (Shafer *et al.*, 1983).

The single case of a Wilm's tumour in this study had metastasised to the molar region of the mandible. True metastatic tumours to the jaws are uncommon, but when it does occur, the mandible tends

to be affected far more frequently than the maxilla. In the mandible, the molar region is the most common site for metastases to develop because of its rich blood supply (Shafer *et al.*, 1983).

The most common site for the occurrence of a mucoepidermoid carcinoma in children is the parotid gland (Coulthard, 1987) and indeed the single case of a mucoepidermoid carcinoma in this study was found to have involved the parotid gland. Although the mucoepidermoid carcinoma may also occur centrally within the bone, there was no bony involvement in this case.

5.1.6 Signs and symptoms

The most common complaint in this group of patients was that of a painless swelling. Pain was not a significant complaint and only four patients complained of painful swellings: two rhabdomyosarcomas; one Burkitt's lymphoma and one leiomyosarcoma (Figure 16 and 17). This is in contrast to reports in the literature. Chuong and Kaban (1985) found that pain was a significant complaint in patients with malignant lesions.

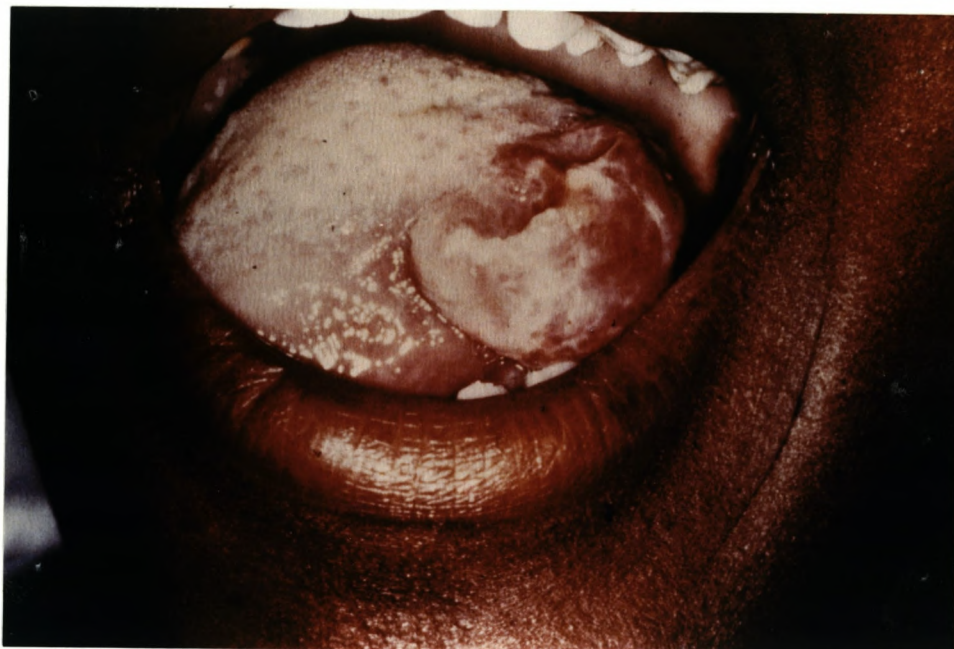
The presence or absence of paraesthesia was not recorded, the reason being that subtle degrees of sensory change is often difficult to detect in young patients.

Apart from swelling, additional symptoms included epistaxis, bleeding gingiva and purpuric lesions of the skin (Table 9). These symptoms were common to the tumours derived from the

Figure 16: RHABDOMYOSARCOMA OF THE MAXILLARY SINUS
Presenting as a swelling of the cheek.



Figure 17: LEIOMYOSARCOMA OF THE TONGUE



lymphoreticular system (leukaemia and lymphoma) and Kaposi's sarcoma. Trauma and measles were found to be predisposing factors to rapid growth of a slowly enlarging mass in two patients with a lymphoma and rhabdomyosarcoma respectively.

Loose or displaced teeth was noted in six cases: four Burkitt's lymphomas, one leukaemia and one Wilm's tumour.

Four patients (13,3%) first presented to the dentist with complaints of a swelling in the jaw and mobile teeth (osteogenic sarcoma, Wilm's tumour and two leukaemias). None of the patients complained of odontalgia.

The majority of the patients were generally in good health. Only two patients (rhabdomyosarcoma and leukaemia) had signs of a systemic illness, viz. malaise, anorexia and weight loss. In addition, the patient with the rhabdomyosarcoma presented with respiratory obstruction produced by an enormously enlarged cervical lymph node. This patient needed an emergency tracheostomy to maintain a patent airway.

The above signs and symptoms are of great clinical importance, since their appearance may be the first indication of an undiscovered malignancy at a distant site (leukaemia, non-Hodgkins lymphoma and Burkitt's lymphoma in this study). Furthermore, a tumour of the maxillofacial and oral region may be the first evidence of dissemination of a known tumour from its primary site (Wilm's tumour in this study).

5.1.7 Duration of symptoms

Dehner (1973) found that symptoms were present for a longer period and were less severe in children with primary malignant disease of the mandible and maxilla compared with secondary tumours. Although no distinction was made between primary and secondary tumours in this study, the secondary tumours were not found to have symptoms that were present for a longer period. For example, the leukaemias (3 cases) had a mean duration of 2,3 weeks.

The mean duration of symptoms for the entire series was 4,5 months with a range of one week to 3 years.

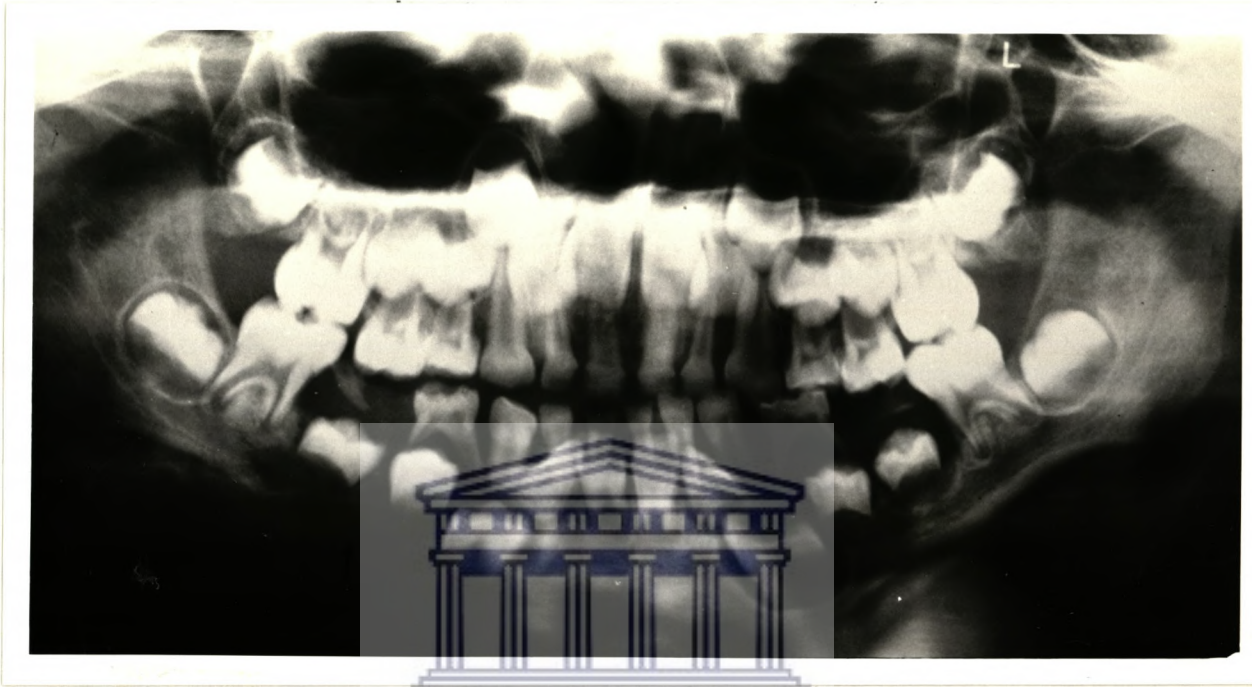
The results of this study indicates a relatively high incidence of maxillofacial and oral tumours in blacks compared with whites. This is most likely an indication of the racial distribution of the population in the Cape Province.

5.1.8 Radiographic Features

The most consistent radiographic feature of the malignant tumour involving the jaws or facial bones was that of a ill-defined radiolucent lesion, the margins of which were almost always irregular (Figure 18). These lesions had a typical "moth-eaten" appearance. Multiple radiolucent lesions were a common finding in patients with Burkitt's lymphoma (Figure 19). Destruction of the cortex with invasion into soft tissues was not uncommon.

Figure 18: ACUTE MYELOID LEUKAEMIA OF THE MANDIBLE

(A) orthopantomograph showing the ill-defined radiolucent lesions around the unerupted right and left mandibular bicuspid. Note the pathological fracture on the left side.




(B) same patient, 4 months following initiation of chemotherapy demonstrating resolution of the lesions and healing of the fracture.

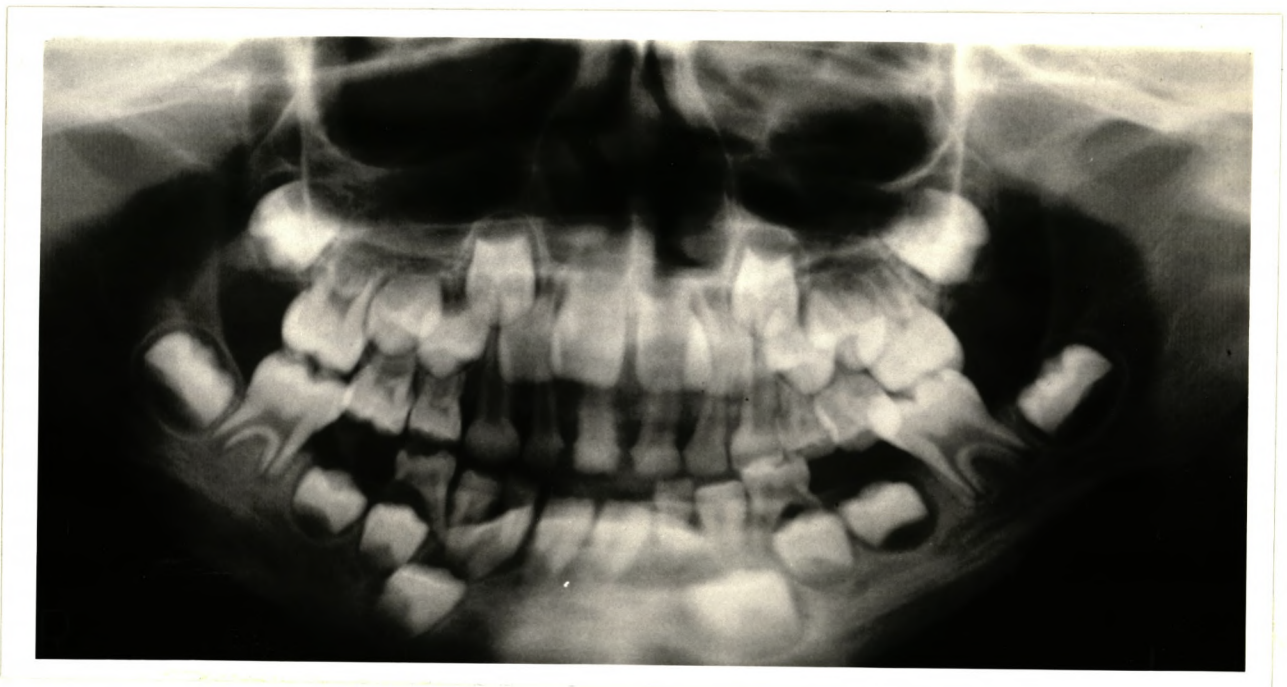

Figure 19: BURKITT'S LYMPHOMA OF THE MANDIBLE

Orthopantomograph demonstrating the multiple radiolucent lesions.



UNIVERSITY of the
WESTERN CAPE

Displacement of teeth, early loss of teeth and teeth "floating in space" appearance were common in patients with Burkitt's lymphoma, but were also noted in the patient with Wilm's tumour and acute myeloid leukaemia (Figure 22, pg.117).

Loss of the lamina dura, widening of the periodontal ligament space and enlargement of the crypt of unerupted teeth should be regarded as ominous signs, as these features were a consistent finding in patients with Burkitt's lymphoma.

None of the tumours showed the typical "sun-ray" appearance characteristic of some malignant tumours such as the osteosarcoma and Ewing's sarcoma.

Radiographic examination of a patient presenting with a swelling or mass in the maxillofacial and oral region is thus mandatory. Similarly in patients presenting with mobility, displacement or early loss of teeth, radiographs should be taken as part of the initial examination process. The orthopantomogram should be used as a screening radiograph for all suspected malignancies because of its general availability and broad overview of the jaws. When identified, malignant lesions should be viewed in at least two planes (two X-rays taken at 90° to each other). This may be done with the use of postero-anterior (PA) views or occlusal views. Tumours of the maxilla and maxillary antrum can be viewed with Water's views, lateral skull and postero-anterior skull views. Intra-oral periapical radiographs can be helpful in detecting loss of lamina dura, widening of the periodontal ligament space

or periapical bone destruction.

Computerised tomographic (CT) scanning has become recognised as a valuable diagnostic tool and has an accepted role in the evaluation of head and neck tumours. It provides important information on the extent of the lesion (Brooks and Velzen, 1990). Recently, the use of magnetic resonance imaging has become a useful aid in the diagnosis of head and neck tumours and especially maxillofacial malignancies.

5.1.9 Treatment

The most common treatment regimen used in this series of patients was a combination of surgery, radiotherapy and chemotherapy (30%) (Table 12). This was followed by chemotherapy (26,7%), surgery plus chemotherapy (23,3%), radiotherapy plus chemotherapy (16,7%) and surgery plus radiotherapy (3,3%). None of the patients were treated with surgery or radiotherapy only, while chemotherapy as the only method of treatment was used in 26,7% of the patients, representing the second most common treatment method.

The majority of the rhabdomyosarcomas were treated with surgery, radiotherapy and chemotherapy (36,4%) or radiotherapy plus chemotherapy (36,4%). Most of the patients with Burkitt's lymphoma (66,7%) were treated with surgery plus chemotherapy.

5.1.10 Survival

The patients were followed-up for a mean period of 3,6 years with a range of 1 month to 15 years. The two year survival rate was

58,6% and the 10 year survival rate was 13,8%. The longest survivors were two patients with rhabdomyosarcomas who survived a period of 15 years with no evidence of disease.

The most common cause of death was metastatic disease followed by local disease. The lungs were the most common site for metastatic deposits followed by the bone marrow and central nervous system.

Interestingly, there was no correlation between the methods of treatment and survival. There was, however, a strong correlation with histologic type and survival (Table 14). All but one of the patients with Burkitt's lymphoma were alive with no evidence of disease. The only patient that died as a result of a Burkitt's lymphoma, survived for 13 years before succumbing to the disease. Death was due to widespread metastases (CNS, abdomen, heart). Thus, patients with Burkitt's lymphoma need longer follow-up periods as relapse may occur several years after remission.

5.2 Discussion: Rhabdomyosarcomas

5.2.1 Aetiology

None of the cases in the present study were preceded by trauma. However, this should not exclude trauma as a "trigger mechanism" as most children are accident prone. Trauma on the other hand, may be the indirect result of a pre-existing but silent rhabdomyosarcoma. One case experienced an increased growth of the tumour following a bout of measles. It would be interesting to determine whether chromosomal abnormalities had any role to play

in the development of these tumours. The majority of the patients in this study were from a low socio-economic group, a finding supported by Grufferman *et al.* (1982).

5.2.2 Histopathologic features

The classification used in this study is based on the one defined by Horn and Enterline (1958) and described by Enzinger and Weiss (1988). It is important to know that there is a great deal of overlap between the various types and it is often difficult to decide in which category to place the tumour. Thus, an embryonal tumour may have areas that resemble an alveolar type. The botryoid rhabdomyosarcoma is considered a variant of the embryonal type, differing only in location and gross form. Both may include areas that resemble alveolar or pleomorphic types (Horn and Enterline, 1958).

A review of the histopathologic characteristics of these tumours revealed the embryonal rhabdomyosarcoma to be the most common type, representing 63,6% of the total number. This was followed by the alveolar type (9,1%). The classical or pleomorphic type was not encountered. Two cases that were originally diagnosed as pleomorphic rhabdomyosarcomas were reclassified as malignant fibrous histiocytomas, and were therefore excluded from this part of the study. The above results are in agreement with the literature. Most childhood rhabdomyosarcomas are of the embryonal type, while the least common is the pleomorphic or adult type (Enzinger and Weiss, 1988).

In this series the single case involving the tongue was of the embryonal type. According to the early literature, tongue tumours were exclusively pleomorphic in nature (Dito and Batsakis, 1962). Enzinger and Weiss (1988) have made the point that most of the so-called pleomorphic rhabdomyosarcomas were examples of malignant fibrous histiocytoma and that in some cases it is difficult to distinguish between the two.

It is difficult to determine whether prognosis or survival is affected by histologic type because of the small number of cases. Of the 4 survivors in this study, 2 were of the embryonal type, 1 was of the botryoid/embryonal type and 1 was of the alveolar type.

The histopathologic features exhibited all of the details described by Horn and Enterline (1988).

(a) Embryonal rhabdomyosarcoma

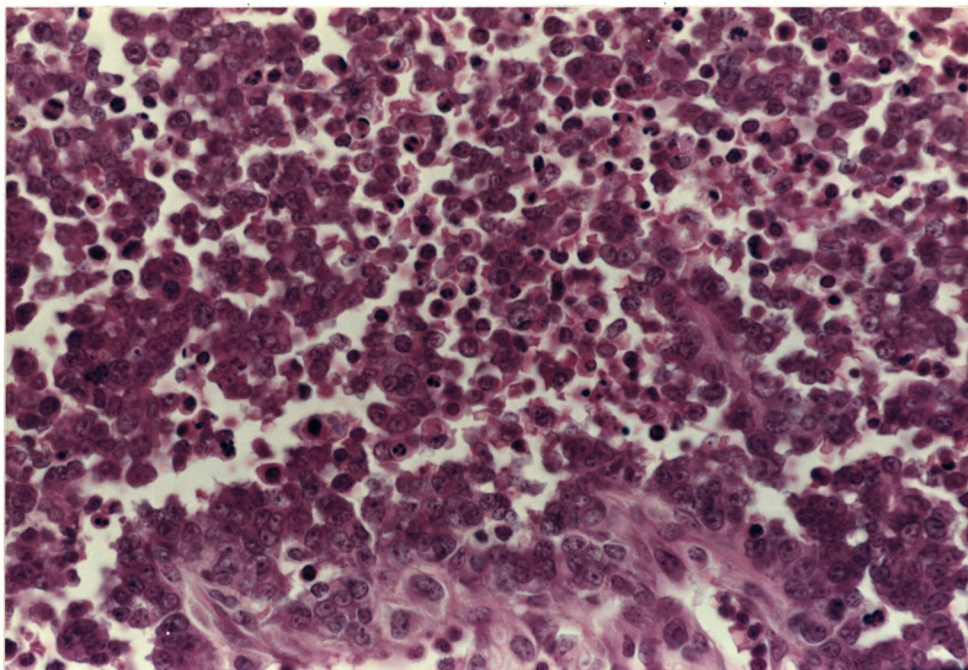
The embryonal rhabdomyosarcomas in this study were composed of one or more of the three cell types described by Stobbe and Dargeon (1950), viz. spindle cells with a centrally situated nucleus and eosinophilic cytoplasm; "tadpole" cells in which the nucleus is situated near one end of the cell, and the rest of the cell tapers outward from the body for a variable distance; or small rounded cells (Figure 20). The cytoplasm exhibited vacuolation which stained positively for glycogen. No cross-striations were seen in any of the sections examined. Horn and Enterline (1957) have emphasised the fact that the identification

Figure 20: EMBRYONAL RHABDOMYOSARCOMA

(A) Typical "tadpole", strap-like and spindle shaped cells. (PTAH, X100).



(B) Note the round cell pattern of growth, cellular pleomorphism, hyperchromatic nuclei and numerous mitotic figures. (H AND E, X100).



of cross-striations is not a sine qua non for the diagnosis of a rhabdomyosarcoma. The tumours exhibited considerable variation in cellularity with alternating hypercellular and densely packed areas and less cellular, loosely textured myxoid areas. In all cases, the cells exhibited the typical features of malignant cells, viz. hyperchromatism, cellular pleomorphism, tripolar mitosis, and increased mitotic activity (Figure 19).

(b) Botryoid rhabdomyosarcoma

The only case of a botryoid rhabdomyosarcoma was identified by the presence of a hypercellular "cambium" layer below the surface epithelium. It also had features of an embryonal rhabdomyosarcoma. The matrix of the tumour was edematous and myxoid in nature.

(c) Alveolar rhabdomyosarcoma

This tumour was characterised by the presence of alveoli separated by connective tissue trabeculae. The cells at the periphery of the alveolar spaces were well preserved and adherent to the fibrous septa, while the cells in the centre were floating freely due to the loss of cellular cohesion. The cells were either rounded, oval or strap-like. Cross-striations were not seen in the sections examined. Mitotic figures were abundant.

5.2.3 Age

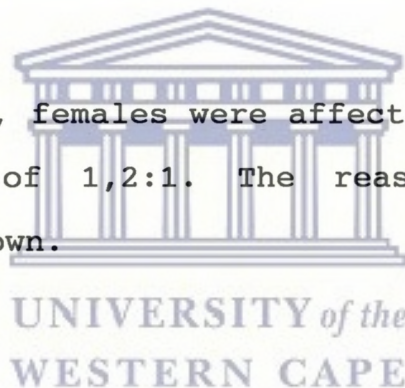In the present study, the ages at the time of diagnosis ranged from 6 months to 13 years with a mean age of 5,4 years and a median of 7 years. Ninety-one percent of the patients were in the

first decade of life, 45,5% were 2 years or younger, while 27,3% were younger than 1 year. Rhabdomyosarcoma of the maxillofacial and oral region in children therefore seems to be a disease of the first decade of life, with almost half of the cases occurring in the first two years of life (Figure 13).

The instability of mesenchyme in infants may explain this age prevalence. It is interesting to note that there was only one case of a congenital rhabdomyosarcoma that only presented for treatment after two years.

5.2.4 Gender

In the present study, females were affected more commonly than males by a ratio of 1,2:1. The reason for this female predominance is unknown.



5.2.5 Race

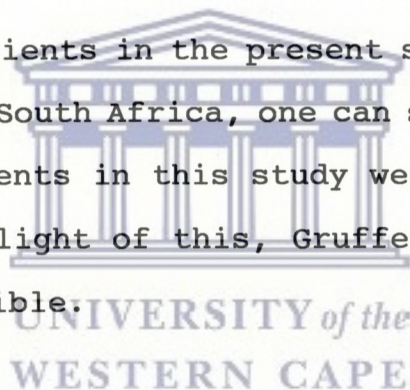Rhabdomyosarcomas have been reported as occurring more often in whites than in blacks (Dito and Batsakis, 1962; Young and Miller, 1975). In the present study, all patients but one were black, a ratio of 10:1. This is in contrast to the reports in the literature.

This racial distribution is important in that it represents the racial distribution of the population served by the two hospitals in the Western Cape. This finding is supported by Swart *et al.* (1985) and Peters *et al.* (1989) who also found a predominance amongst blacks. These two studies were carried out at

institutions serving a similar population to those in the present study.

Thus, rhabdomyosarcoma affects both whites and blacks and the racial distribution will depend on the ratio of the different racial groups in a given population. It may be that genetic factors also play a role.

Extrinsic factors may also play a role. Grufferman *et al.* (1982) found that rhabdomyosarcoma was associated with people of a lower socio-economic status. When one considers the socio-political background of the patients in the present study, and knowing the political history of South Africa, one can safely assume that the majority of the patients in this study were from disadvantaged communities. In the light of this, Grufferman's *et al.* (1982) findings seems plausible.



5.2.6 Geographic distribution

There is no information in the literature that suggests a higher susceptibility in any geographic area (Stout, 1946).

Groote Schuur Hospital and Red Cross War Memorial Children's Hospital receive patients from many other peripheral hospitals. 72,7% of the patients were referred from other centres, with 34,5% of the patients coming from the Eastern Cape, and 18,2% coming from Namibia. 27,3% of the patients were from the Western Cape.

This study therefore indicates that for some, as yet unknown reason/s, rhabdomyosarcoma has a somewhat higher incidence in the Eastern Cape compared with the Western Cape and with Namibia.

5.2.7 Anatomical site of lesion

The most common site of disease in the present series was the nasopharynx, accounting for 33,3% of all the head and neck cases. This is followed by the orbit (28,6%); maxillofacial and oral region (26,2%); middle ear (7,1%) and the soft tissues of the neck (4,8%) in decreasing order of frequency (Figure 1). The predominance of nasopharyngeal tumours over orbital tumours is in contrast to reports appearing in the literature. It is generally agreed that the orbit is the most commonly affected site in the head and neck, followed by the nasopharynx and middle ear (Peters *et al.*, 1989). In the head and neck series reported by Enzinger and Weiss (1988) the orbit was found to be the leading site of involvement followed by the nasopharynx, ear and ear canal, paranasal sinuses, soft tissues of the face and neck, and oral cavity including the tongue, lip and palate. The reason for the difference in anatomic distribution between orbital and nasopharyngeal tumours in the present study may be due to the fact that most head and neck reports in the literature have included children and adults, whereas the present study has been confined to children. It may indicate that the rhabdomyosarcoma has a preference for occurring in the nasopharynx of children.

In the present series, maxillofacial and oral tumours accounted for 26,2% of all head and neck rhabdomyosarcomas in children. In

the IRS series, oral, oropharyngeal and parotid tumours accounted for 11% of all head and neck rhabdomyosarcomas (Wharam *et al.*, 1984). Bras *et al.* (1987) found that oral rhabdomyosarcomas represented 12% of all head and neck rhabdomyosarcomas.

From the literature, it appears that the soft palate is the most likely site for the development of an oral rhabdomyosarcoma (Dito and Batsakis, 1963; O'Day *et al.*, 1965; Bras *et al.*, 1967). Site predilections for the present study were as follows: there were 2 cases each that involved the soft palate, cheek and the soft tissues at the angle of mandible; and one case each involving the maxillary antrum, tongue, pterygoid fossa, nasolabial fold and chin. The findings of this study is in contrast with that of the literature in that there was no definite site predilection. Rhabdomyosarcoma, therefore in this study had a tendency to affect any site in the maxillofacial and oral region in children. However, tumours involving the floor of the mouth and gingiva seemed to be uncommon.

An interesting feature of the present study is the absence of any primary intrabony tumours. Although one case involving the chin had involvement of the symphysis of the mandible, it was felt that this was as a result of contiguous spread of the tumour into bone rather than the opposite. Another case involving the cheek showed evidence of erosion of the malar bone, thus indicating the local aggressiveness of the tumour. Peters *et al.* (1989) found several intrabony cases in their series, all involving the posterior region of the mandible. Several case reports have

appeared in the literature on rhabdomyosarcomas occurring centrally within bone (Yammamoto *et al.*, 1984; Lazzaro *et al.*, 1990). This seems possible when one considers that rhabdomyosarcomas develop as a result of malignant change of primitive mesenchymal cells rather than differentiated muscle (Proops and Mann, 1984).

5.2.8 Signs and symptoms

The findings of this study as regards signs and symptoms, corresponds with those of others. O'Day *et al.* (1965) found that rhabdomyosarcoma of the oral and para-oral regions most often appear as an enlarging painless mass. Pain may be present if there is nerve involvement or when secondary infection has occurred. Suspected infection is an important cause of delay in diagnosis (Bras *et al.*, 1987). Late symptoms include pain, dysphagia, dysphonia, deviation of the mandible, paraesthesia, loosening of the teeth and trismus. Physical debilitation is also regarded as a late sign (O'Day *et al.*, 1965; Bras *et al.*, 1987).

Of the 11 patients in the present study, 81,8% (9) presented with a painless mass (Figure 16, pg.93). In only one patient was the mass reported to be painful. One patient presented with advanced disease as evidenced by respiratory distress and an emaciated appearance.

5.2.9 Duration of symptoms

The average duration of symptoms of the 8 cases in whom this

feature had been recorded, was 4,3 months and the range was 3 weeks to 2 years. This closely approximates the average duration of 3,6 months and a range of 1 month to 2 years reported by O'Day *et al.* (1965). However, if one case with an extremely long duration of 2 years is disregarded, then the range for the remaining cases is from 3-12 weeks and the mean 5,9 weeks.

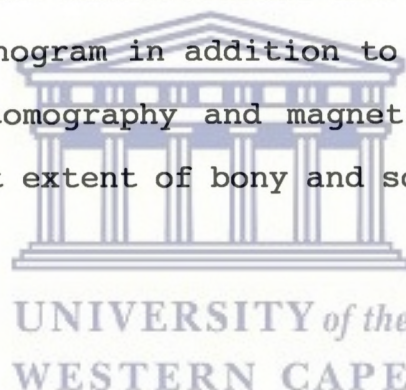
5.2.10 Clinical stage

Tumours in this study have been classified according to the International Rhabdomyosarcoma Study staging system for childhood rhabdomyosarcoma (Table 2). The reason for staging these tumours is because prognosis is determined by the clinical group, with clinical group I having the best survival and clinical group IV the worst (Maurer *et al.*, 1988). In the present study the majority of cases (72,7%) were in clinical group III, with one each in clinical group I, II and IV. All the patients who died as a result of their disease were either in clinical group III or IV at the time of diagnosis. Of the 4 patients who were alive 2-15 years after diagnosis, one belonged to clinical group I, one to clinical group II and two were in clinical group III. One of the 2 patients who was disease free for a total of 15 years belonged to clinical group III, while the other belonged to clinical group I.

5.2.11 Radiographic features

Bony involvement was present in only 45,5% (5) of the patients (Table 11). Bone involvement occurred as a result of contiguous spread of the tumour into bone. There were no primary bone

tumours in this series of rhabdomyosarcomas. Peters *et al.* (1989) found a high frequency of intrabony tumours involving the posterior mandible in their study. This is possible because of origin of rhabdomyosarcomas from primitive mesenchymal cells rather than differentiated muscle. Four of the five patients had radiographic features suggestive of a malignant tumour, viz. radioluscent lesions with poorly defined and irregular margins, giving a "moth eaten" appearance. The fifth case was found to have bony involvement following a Scintiscan. Thus, radiographic examination should be carried out routinely in patients with a rhabdomyosarcoma of the maxillofacial and oral region and should include an orthopanthogram in addition to other conventional X-rays. Computerized tomography and magnetic resonance scanning will reveal the exact extent of bony and soft tissue involvement respectively.



5.2.12 Treatment

Treatment of patients in this series consisted of a combination of surgery, radiotherapy and chemotherapy consisting of vincristine, actinomycin, cyclophosphamide (VAC) or VAC plus adriamycin and/or endoxan.

5.2.13 Survival

The overall actuarial 2 year survival rate for this group of patients is 54,5% and for 5 years, 18,2%. Only 2 of the 11 patients have survived for a period of 15 years. This poor prognosis is in contrast to the findings of Bras *et al.* (1987) and Peters *et al.* (1989) who found the oral and para-oral

tumours to have a good prognosis. The reason for this poor prognosis is not known. One can only speculate that the socio-economic background, and hence the nutritional status of the patient might have played a role.

5.3 Discussion: Burkitt's lymphoma

5.3.1 Age

The age incidence of patients in the present study closely resembles that of African Burkitt's lymphoma (AfBL). Burkitt's finding that the tumour is virtually unknown under the age of one year, and that less than 3% are under three years of age is confirmed by this study as all the patients were in the 3-8 year age group (Burkitt and Wright, 1970).

5.3.2 Gender

In African Burkitt's lymphoma, the ratio of males to females with jaw lesions is 3:1 (Burkitt and Wright, 1970). The American Burkitt's lymphoma has no gender predilection (Regezi and Sciubba, 1989). It is not known why the present study had a sex distribution similar to that of the American Burkitt's lymphoma.

5.3.3 Race

African Burkitt's lymphoma affects primarily blacks, whereas American or non-endemic Burkitt's lymphoma affects white persons primarily (Regezi and Sciubba, 1989). In the present study, all the patients but one were black. This racial distribution is a reflection of the general population presenting for treatment at this institution.

5.3.4 Geographic distribution

All of the patients in the present study were from the Cape Province and lived in regions below 5,000 feet in altitude. The Cape Province has a winter rainfall pattern. However, only two (33,3%) of the patients had their symptoms during this period of the year. The remaining four (68,7%) had their symptoms either at the end of the rainy season or during the summer months when there was little or no rainfall. Furthermore, most of the patients lived in areas where the temperature dropped to below 15°C. These findings contradict the conclusions drawn from Burkitt's tumour safari (Burkitt, 1962). Hesselting *et al.* (1989) reported on 22 patients with Burkitt's lymphoma in the Cape Province and Namibia. Although most of their patients had clinical features similar to African Burkitt's lymphoma, several patients were residents of arid areas. Like the African Burkitt's lymphoma, however, they found that the development of the patient's disease was more likely during the rainy season. In the present series, this seasonal variation was lacking.

5.3.5 Anatomical site of lesion

In the present study 83,3% of the patients had jaw involvement, corresponding to figures found in endemic areas (Burkitt and O'Connor, 1961). The mandibular tumours affected both quadrants, while the maxillary tumours were confined to a single quadrant. None of the cases had more than two quadrants involved. The only case with no jaw bone involvement was a female who had involvement of the ovary, a finding also noted by Burkitt (1970).

The abdomen is the second most common site of involvement in African Burkitt's lymphoma (Burkitt and O'Connor, 1961), a finding supported by the present study.

5.3.6 Signs and symptoms

In the present study, jaw lesions represented the most common presenting symptom, followed by an abdominal mass. This corresponds to the pattern of organ involvement in African Burkitt's lymphoma. Fifty percent of the patients had mobile teeth. Adatia (1970) regards this as one of the earliest signs of jaw involvement. Displacement of teeth was found in 66,6% of cases. All the tumours involving the jaw bones had produced buccal, palatal or lingual expansion.

5.3.7 Duration of symptoms

The mean duration of symptoms was 2,1 weeks with a range of 3 days to 4 weeks. The clinical significance of the duration of symptoms in Burkitt's lymphoma lies in the fact that Burkitt's lymphoma has a doubling time of 24 hours (Burkitt, 1961). Thus the earlier the patient presents, the better the prognosis. The early presentation of patients in this series may partly be responsible for the favourable outcome of treatment.

5.3.8 Histopathologic features

Histologically, all the cases revealed the typical features of Burkitt's lymphoma, save for one case. Jaw lesions were indistinguishable from lesions at other sites. The tumours consisted of a monotonous overgrowth of undifferentiated,

monomorphic, lymphoreticular cells. The cells contained round or oval nuclei with several prominent basophilic nucleoli. The overall monotony was broken by the presence of large macrophages with abundant clear cytoplasm containing cellular debris. This gave the tumours the typical "starry sky" appearance with the darkly staining uniform, undifferentiated lymphocytic cells making up the "dark background", and the phagocytic histiocyte constituting the "stars". Mitotic figures were present in all cases (Figure 21).

The "starry sky" pattern is not pathognomonic of Burkitt's lymphoma, as evidenced by one case in the present series (Enzinger *et al.*, 1969). This tumour consisted of sheets of undifferentiated lymphoreticular cells containing round or oval nuclei and prominent nucleoli staining deeply basophilic. Mitotic figures were present, but the presence of macrophages with a clear cytoplasm was lacking. However, cell surface markers found the tumour to be LCA positive, T-cell negative and B-cell positive, thus confirming the nature of the tumour.

Testing for the presence of Epstein-Bar virus antigens or antibodies was not performed in all the patients. Of the four patients tested with indirect immuno-fluorescence, two were positive for antibodies against Epstein-Bar virus, while two were positive for viral core antigen.

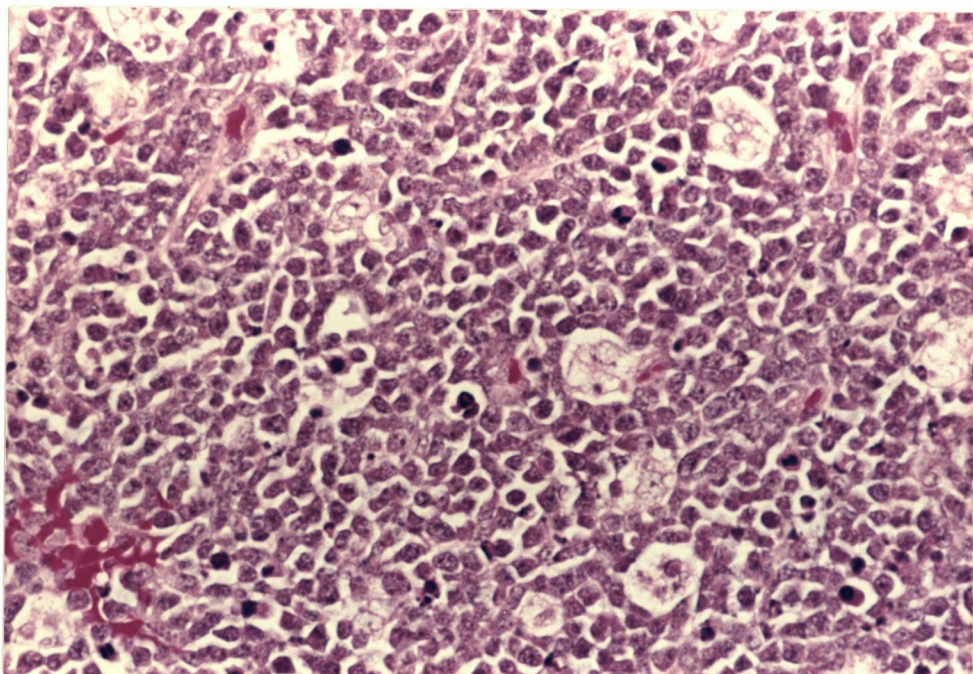
Histologic examination of the teeth was not performed at the time of diagnosis due to the fact that most patients were diagnosed by general pathologists rather than oral pathologists. The

Figure 21: BURKITT'S LYMPHOMA

(A) "Starry-sky" appearance produced by an overgrowth of lymphocytes with interspersed macrophages. (H AND E, X25).



(B) Note the clear cytoplasm of the macrophages and the numerous mitotic figures. (H AND E, X100).



demonstration of dental involvement is important from a diagnostic point of view, because very few neoplasms invade the pulp and pulpal involvement may be the first sign of jaw involvement or of the disease (Adatia, 1970).

5.3.9 Radiographic features

Radiographic examination in the present series of Burkitt's lymphoma revealed one or more of the classical features discussed in the literature (Adatia, 1970). The most consistent finding was loss of the lamina dura, widening of the periodontal ligament space and displacement of teeth (Figure 22). It is important to note that these findings are not specific to Burkitt's lymphoma, as these changes may also be found in odontogenic infection, osteosarcoma and histiocytosis (Hupp *et al.*, 1982).

5.3.10 Treatment

In the early 1960's, surgical removal of the tumour mass was popular as radiotherapy and chemotherapy was not available in many parts of Africa (Yagi *et al.*, 1984).

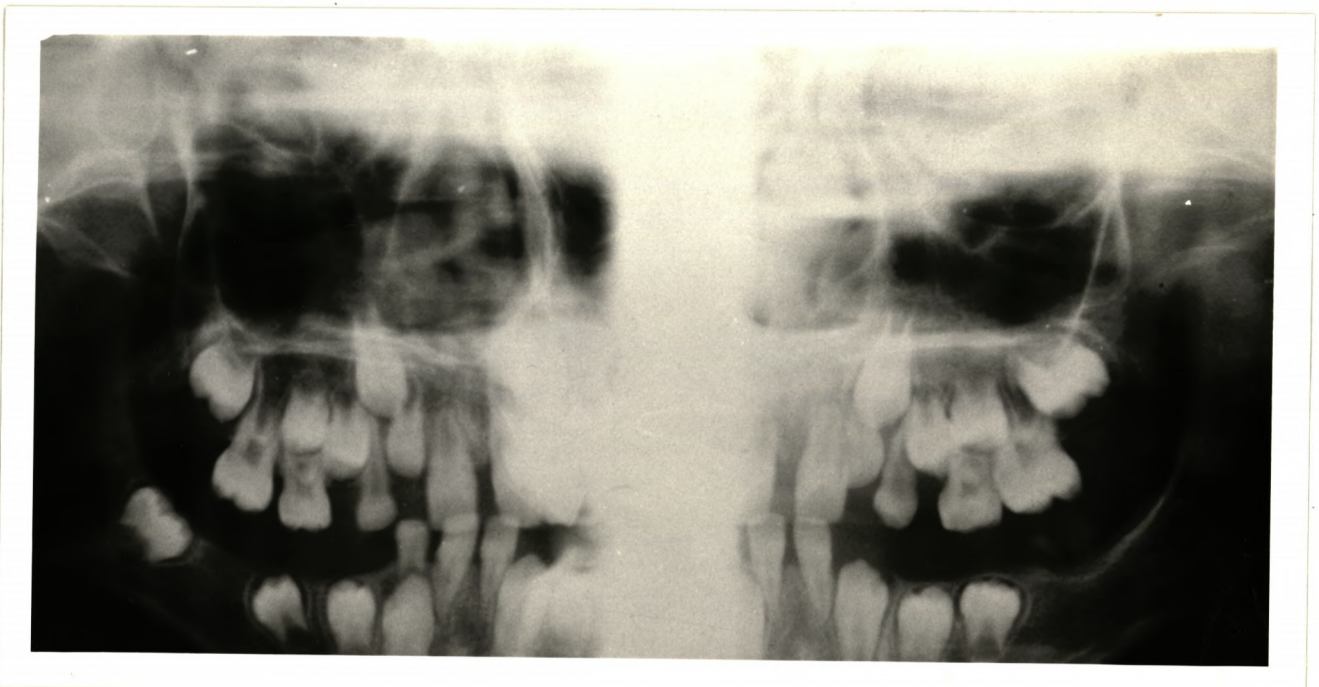
Because Burkitt's lymphoma is a multifocal disease, surgery and/or radiotherapy is usually unsuccessful. Chemotherapy is therefore the treatment of choice with surgery and radiotherapy being used as adjuncts (Burkitt, 1970). Chemotherapeutic agents used in the present series included a combination of vincristine, prednisone, endoxan, methotrexate, and adriamycin (French Protocol).

Figure 22: BURKITT'S LYMPHOMA OF THE MANDIBLE.

(A) Orthopantomograph demonstrating displacement of the mandibular first permanent molar teeth with resultant "teeth floating in space" appearance.




(B) Same patient, 6 months following initiation of chemotherapy.



5.3.11 Survival

Burkitt's lymphoma is considered to be the fastest growing tumour in man, usually leading to death within 4-6 months if left untreated (Zacharaides and Papanicolaou, 1986). It said that Burkitt's lymphoma has a doubling time of 24 hours (Burkitt, 1961). Survival in the present series was excellent. Only one patient died of recurrent disease 13 years after diagnosis. This excellent survival rate may be explained by the fact that patients were diagnosed and treated early. However, long term follow-up is essential. The two year survival rate was 100%. Hesseling *et al.* (1989) reported on a 2 year survival rate of 27%. This low survival rate was attributed to the fact that a greater number of patients presented at an advanced stage of the disease.



CONCLUSIONS

- 6.1 **Maxillofacial and oral tumours in general**
- 6.2 **Rhabdomyosarcomas**
- 6.3 **Burkitt's lymphoma**
- 6.4 **Criticism of study**



UNIVERSITY *of the*
WESTERN CAPE

6.1 Maxillofacial and oral tumours in general

- (a) Malignant tumours of the maxillofacial and oral region in children are rare.
- (b) The tumours tend to be non-odontogenic and mesenchymal in origin. Malignant odontogenic tumours are extremely rare in children.
- (c) The rhabdomyosarcoma is the most common tumour to affect the maxillofacial and oral region in children, followed by Burkitt's lymphoma, acute myeloid leukaemia, non-hodgkins lymphoma and malignant fibrous histiocytoma in decreasing order of frequency.
- (d) The incidence of malignancy is greatest in the first 6 years of life and is less common in the subsequent 10 years.
- (e) Blacks are affected more commonly than whites. This racial distribution may represent case material from an unselected geographic population and hence represents the racial distribution of the population in the Cape Province.
- (f) Children from the Eastern Cape seem to have a somewhat greater predilection for the development of a maxillofacial and oral malignancy.
- (g) The mandible and maxilla are the most common sites to be

involved, followed by the soft tissues of the face.

- (h) Intra-oral tumours as a group are more common than extra-oral tumours. Floor of mouth involvement in children is extremely rare, unlike adults.
- (i) The most common primary complaint is that of a painless swelling. Thus, a high index of suspicion is needed when dealing with a child presenting with this symptom. Mobility and displacement of teeth in children should be viewed with suspicion.
- (j) Radiographic assessment of a child with a maxillofacial and oral swelling is compulsory. The most consistent radiographic appearance of a malignancy in this site is that of a poorly-defined or "moth-eaten" radiolucency. CT and MR scanning are important to determine the extent of bony and soft tissue involvement.
- (k) As far as treatment is concerned, there is no correlation between method of treatment and survival. There is, however, a correlation between histologic type and survival, with Burkitt's lymphoma having the best prognosis.
- (l) Overall, malignant tumours of the maxillofacial and oral region in children has a poor prognosis. The 5 year survival is 20,7% and the 10 year survival is 13,8%.

(m) The most common cause of death is metastases to the lungs.

6.2 Rhabdomyosarcomas

Inspite of the small number of patients in this series, the following conclusions can be drawn from this study:

(a) Rhabdomyosarcomas of the maxillofacial and oral region in children are uncommon.

(b) Children in the first decade of life are most often affected.

(c) There is no sex or race predilection. The tumour is more common in the Eastern Cape than in the Western Cape.

(d) The most common mode of presentation is that of a painless swelling. Because of its non-specific presentation, it may be mistaken for various other conditions, the most common being dental sepsis. Thus, a high index of suspicion is necessary when a child in the first decade of life presents with a facial or oral swelling.

(e) There is no definite site predilection in the maxillofacial and oral region. However, palatal involvement is somewhat more common, while gingival and floor of mouth involvement is unusual.

(f) Most patients present for treatment in an advanced stage,

viz. clinical group III, thus making prognosis worse.

- (g) The majority of tumours are of the embryonal subtype, while pleomorphic tumours are rare.
- (h) Bone involvement is not uncommon.
- (i) Response to treatment in this series was poor, hence the poor survival rate.

6.3 Burkitt's lymphoma

The small number of patients in this series makes it difficult to draw any definite conclusions. However, the following statements can be made:

- (a) Burkitt's lymphoma does occur in South Africa, and more specifically, in the Cape Province. This is in contrast to Burkitt's statement in the literature that "the tumour is virtually unknown in South Africa " (Burkitt, 1962).
- (b) The tumour distribution in this series is similar to that of African cases. Maxillofacial and abdominal involvement occurred in all patients.
- (c) The age incidence was similar to that of African Burkitt's lymphoma.
- (d) Despite the overwhelming clinical similarity between

patients in this series and patients with African Burkitt's lymphoma, there were definite differences with respect to environmental factors. Most of the patients lived in regions where the temperature frequently dropped to below 15°C (60°F). Most of the patients had their symptoms during the summer months when there was very little or no rainfall.

- (e) The frequency of jaw lesions and oral involvement, emphasises the importance of considering this condition in the differential diagnosis of paediatric jaw swellings.
- (f) The clinical and radiographic features are not pathognomonic and the differential diagnosis should include odontogenic infection, Ewing's sarcoma, rhabdomyosarcoma, histiocytosis and neuroblastoma. Confirmation by histologic examination is mandatory.
- (g) Burkitt's lymphoma has a good prognosis when diagnosed and treated early. However, long term follow-up is necessary.

6.4 Criticism of study

This study may be criticised for the small sample size. However, if one considers the fact that this was a retrospective study carried out over a 20 year period (1973-1993) then such criticism is not valid. This study reinforces the findings in the literature that malignant tumours of the maxillofacial and oral region in children are extremely rare.

7. **RECOMMENDATIONS**

Because of the relative infrequency of tumours of the maxillofacial and oral region in children, a single institution has difficulty in accumulating sufficient patients for an analysis of the clinicopathologic features of these neoplasms.

In order to collect a series of cases large enough, it is recommended that information from multiple centres countrywide be combined. This will permit characterization of the disease more thoroughly than was possible heretofore, and relate multiple factors including age, site of tumour origin, histologic type, gender, race and extent of disease to treatment responses and prognosis.

It would be interesting to know the effects of ionizing radiation and chemotherapy on the growth of the mandible and maxilla and on the development of the dentition. This could form the basis of another study.

8. **APPENDICES**

Appendix I - Proforma for the collection of clinical
data

Appendix II - Letter sent to institutions concerned



UNIVERSITY *of the*
WESTERN CAPE

PROFORMA FOR THE COLLECTION OF CLINICAL DATA

1. Record Number		
-------------------------	--	--

2. Folder Number									
-------------------------	--	--	--	--	--	--	--	--	--

3. Demographic Features		
3.1 Age		
3.2 Sex M / F		
3.3 Race W / B		

4. Diagnosis _____

5. Site of Lesion _____

6. Signs and Symptoms

6.1 Duration of Symptoms _____

6.2 Symptoms (main complaint) _____

6.3 Signs _____

7. Special Investigations _____



8. Radiographic Features

8.1 Site of Lesion _____

8.2 Overall Degree of Radiolucency / Opacity

8.2.1 Radiolucent _____

8.2.2 Radiopaque _____

8.2.3 Mixed _____

8.3 Origin of Lesion

8.3.1 Intrabony _____

8.3.2 Extrabony _____

8.4 Margins _____

8.5 Effect on Teeth _____

9. Treatment

9.1 Surgery _____

9.2 Chemotherapy _____

9.3 Radiotherapy _____

9.4 Combination _____

10. Current Status

10.1 Disease free _____

10.2 Residual disease _____

10.3 Died _____

11. Follow-up Period

12. Histopathology





University of the Western Cape

Universiteit van Wes-Kaapland

**DEPARTMENT OF MAXILLOFACIAL
AND ORAL SURGERY AND RADIOLOGY**

Private Bag X12
Tygerberg, 7505
Tel. Ad.: UNIBELL, S.A.
Tel. 931-9981

Privaatsak X12
Tygerberg, 7505
Tel. Ad.: UNIBELL, S.A.
Tel.: 931-4281

Faculty of Dentistry
Fakulteit Tandheelkunde

Dir. line/lyn

Ref./Verwys.

Dear Sir/Madam

RE: PERMISSION FOR THE USE OF CLINICAL/HISTOPATHOLOGIC RECORDS

As a registrar in the Department of Maxillofacial and Oral Surgery, I am required to submit a dissertation in partial fulfilment of the degree MChD at the Faculty of Dentistry, University of the Western Cape.

The topic of my dissertation is "Malignant Tumours of the Maxillofacial and Oral Region in children presenting at the Red Cross War Memorial Children's Hospital and Groote Schuur Hospital between the period 1973-1993".

Your permission is hereby requested for the use of the relevant clinical/histopathologic records. Acknowledgement of your department will be made should any academic papers arise from this study.

Thanking you in anticipation.

Yours sincerely

Dr. A. Mohamed: _____

Dr. G. Kariem / Dr. J.J. Hille (Promoters): _____

9. **REFERENCES**

Adatia, A.K. (1966) Radiology of Burkitt's tumour in the jaws. Br. Dent. J. **120**: 315-326.

Adatia, A.K. (1970) Dental Aspects. In: Burkitt, D.P. and Wright, D.H. (eds) Burkitt's Lymphoma. E and S Livingstone, Edinburgh and London.

Akinwande, J.; Odukoya, O.; Nwoku, A.L.; Taiwo, E.O. (1986) Burkitt's lymphoma of the jaws in Lagos: Ten-year Review. J. Maxillofac. Surg. **14**: 323-328.

Anaissie, W.; Geha, S.; Allan, C. et al. (1985) Burkitt's Lymphoma in the Middle East. Cancer **56**: 2538.

Anavi, Y.; Kaplinsky, C.; Calderon, S.; Zaizou, R. (1990) Head, neck and maxillofacial childhood Burkitt's lymphoma: A Retrospective Analysis of 31 Patients. J. Oral Maxillofac. Surg. **48**: 708-713.

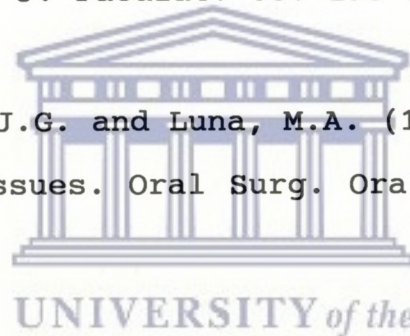
Asamoah, E.A.; Ayanlere, A.O.; Olaitan, A.A.; Adekaye, E.O. (1990) Paediatric tumours of the jaws in Northern Nigeria: Clinical Presentation and Treatment. J. Cran. Maxillofac. Surg. **18**: 130-135.

Banks, P.M.; Arseneau, J.C.; Gralnick, H.R.; Canellos, G.P.; De Vita, V.T. and Berard, C.W. (1975) American Burkitt's Lymphoma: A Clinicopathological Study of 30 Cases II: Pathologic Correlations. *Am. J. Med.* **58**: 322-329.

Berkovitz, B.K.B.; Holland, G.R. and Mothan, B.J. (1978) A Colour Atlas and Textbook of Oral Anatomy. Wolfe Medical Publications Ltd.

Bhasker, S.N. (1963) Oral Tumours of Infancy and Childhood: Survey of 293 Cases. *J. Paediat.* **63**: 195-210.

Bras, J.; Batsakis, J.G. and Luna, M.A. (1987) Rhabdomyosarcoma of the Oral Soft Tissues. *Oral Surg. Oral Med. Oral Path.* **64**: 585-596.



Burkitt, D.P. (1958) A sarcoma involving the jaws in African children. *Brit. J. Surg.* **46**: 218-223.

Burkitt, D.P. and O'Connor, G.T.O. (1961) Malignant lymphoma in African children II. A Pathological Entity. *Cancer* **14**: 270-281.

Burkitt, D.P. (1962 [a]) Determining the climatic limitations of a children's cancer common in Africa. *Brit. Med. J.* **2**: 1019-1022.

Burkitt, D.P. (1962 [b]) A tumour safari in east and central Africa. *Brit. J. Cancer* **16**: 379-386.

Burkitt, D.P. (1970) General Features and Facial Tumours. In: Burkitt, D.P. and Wright, D.H. (eds) Burkitt's Lymphoma. Edinburgh and London, E and S Livingstone, p.6-15.

Burkitt, D.P. (1983) The discovery of Burkitt's lymphoma. *Cancer* **51**: 1777-1786.

Chemello, P.D.; Nelson, C.L.; Tomich, C.E. and Sadove, A.M. (1988) Embryonal rhabdomyosarcoma arising in the masseter muscle as a second malignant neoplasm. *J. Oral Maxillofac. Surg.* **46**: 899-905.

Christensen, R.E. Jr. (1979) Soft tissue lesions of the head and neck. In: Sanders, B. Paediatric Oral and Maxillofacial Surgery. Mosby, St. Louis.



Chuong, R. and Kaban, L.B. (1985) Diagnosis and treatment of jaw tumour in children. *J. Oral Maxillofac. Surg.* **43**: 323-332.

Cook, A.R. (1901) Notes on the diseases met with in Uganda, Central Africa. *J. Trop. Med. Hyg.* **4**: 175-178.

Cotton, R.T.; Ballard, E.T.; Going, J.A.; Myer, C.M.; Towbin, R.B. and Wong, K.Y. (1987) Tumours of the head and neck in children. In: Thawley, S.E.; Panje, W.R.; Batsakis, J.G. and Lindberg, R.D. (eds) Comprehensive Management of Head and Neck Tumours. W.B. Saunders Company, Philadelphia.

Coulthard, S.W. (1987) Tumours of the salivary glands. In: Thawley, S.E.; Panje, W.R.; Batsakis, J.G. and Lindberg, R.D. (eds) Comprehensive Management of Head and Neck Tumours. W.B. Saunders Company, Philadelphia.

Davies, J.N.P.; Elmes, S.; Hutt, M.S.R.; Mtimavalye, L.A.R.; Owar, R. and Shaper, L. (1964) Cancer in an African Community, 1897-1956: An Analysis of the Records of Mengo Hospital, Kampala, Uganda, I. Brit. Med. J. **1**: 259-264.

Dehner, L.P. (1973) Tumours of the mandible and maxilla in children. II A study of 14 primary and secondary malignant tumours. Cancer **32**: 112-120.

Dito, W.R. and Batsakis, J.G. (1962) Rhabdomyosarcoma of the head and neck: An appraisal of the biologic behaviour in 170 cases. Arch. of Surg. **84**: 582-588.

Dito, W.R. and Batsakis, J.G. (1963) Intra-oral, pharyngeal and nasopharyngeal rhabdomyosarcoma. Arch. Otolaryngol. **77**: 123-128.

Enzinger, F.M.; Lattes, R. and Torloni, H. (1969) Histological typing of soft tissue tumours. Geneva, World Health Organization.


Enzinger, F.M. and Weiss, S.W. (1983) Soft Tissue Tumours. C.B. Mosby, St. Louis.

Epstein, M.A.; Achong, B.G. and Bar, Y.M. (1964) Virus particles in cultured lymphoblasts from Burkitt's lymphoma. *Lancet*. **1**: 702-703.

Goaz, P.W. and White, S.C. (1987) *Oral Radiology. Principles and Interpretation*. C.V. Mosby Company, St. Louis.

Greer, R.O. Jr. and Mierau, G.W. (1980) *Tumours of the oral mucosa and jaws in infants and children*. University of Colorado Medical Centre, Denver.

Grufferman, S.; Wang, H.H.; De Long, E.R.; Kimm, S.Y.S.; Delzel, E.S. and Falletta, J.M. (1982) Environmental factors in the etiology of rhabdomyosarcoma in children. *J. Nat. Cancer Inst.* **68**: 107-113.



Hays, D.M. (ed) (1986) *Paediatric Surgical encology. The principles and practice of the paediatric surgical specialties*. Grune and Stratton, Inc. Orlando, Florida.

Hesseling, P.; Wood, R.E.; Nortjé, C.J.; Mouten, S. (1989) African Burkitt's lymphoma in the Cape Province of South Africa and in Namibia. *Oral Surg. Oral Med. Oral Path.* **68**: 162-166.

Horn, R.C. Jr. and Enterline, H.T. (1958) Rhabdomyosarcoma: A Clinicopathological Study and Classification of 39 Cases. *Cancer* **11**: 181-199.

Hupp, J.R.; Collins, F.J.V.; Ross, A. and Myall, R.B.T. (1982) A review of Burkitt's lymphoma. Importance of Radiographic Diagnosis. *J. Maxillofac. Surg.* **10**: 240-245.

Hutt, M.S.R. (1970) Introduction and Historical Background. In: Burkitt, D.P. and Wright, D.H. (eds) *Burkitt's Lymphoma*. Edinburgh and London, E and S Livingstone.

Jablonski, S. (1982) *Illustrated Dictionary of Dentistry*. W.B. Saunders Company, Philadelphia.

Jaffe, B.F. (1973) Paediatric head and neck tumours: A study of 178 cases. *Laryngoscope* **83**: 1644-1651.

Jaffe, B.F. and Jaffe, N. (1973) Head and neck tumours in children. *Paediatrics* **51**: 731-740.

Jones, P.G. and Campbell, P.E. (1976) *Tumours of infancy and childhood*. Blackwell Scientific Publications, Melbourne.

Karabus, C.D. and Hartley, P.S. (1987) Malignant disease. In: Cook, R. (ed) *Paediatric Handbook of the Institute of Child Health*, University of Cape Town. Haum Educational Publishers, Pretoria.

Lanzkowsky, P. (1983) *Paediatric oncology: A treatise for the clinician*. McGraw-Hill Book Company, U.S.A.

Lazzaro, B.; Schwartz, D.; Lewis, J. and Weiss, W. Jr. (1990) Rhabdomyosarcoma involving the oral cavity, mandible and roots of the third molar: A Clinicopathological Correlation and Review of the Literature. *J. Oral Maxillofac. Surg.* **48**: 72-77.

Leeson, T.S. and Leeson, C.R. (1981) *Histology* (4th ed.) W.B. Saunders Company, Philadelphia.

Levine, P.H.; Kamaraju, L.S.; Connelly, R.R. *et al.* (1982) The American Burkitt's lymphoma registry: Eight year's experience. *Cancer* **49**: 1016-1022.

Li, F.P. and Frauman, J.F. (JB) (1969) Soft tissue sarcomas, breast cancer, and other neoplasms. A familial syndrome? *Annals of Internal Medicine* **71**: 747-752.

Martin, G.E. and Alexander, W.A. (1924) A case of rhabdomyosarcoma of the soft palate. *J. Laryng. and Otolaryngol.* **39**: 312-321.

Maurer, H.M.; Moon, T.; Donaldson, M. *et al.* (1977) The Intergroup Rhabdomyosarcoma Study: A preliminary report. *Cancer* **40**: 2015-2026.

Maurer, H.M.; Beltangady, M. *et al.* (1988) The intergroup rhabdomyosarcoma study I: A final report. *Cancer* **61**: 209-220.

McGill, T. (1989) Rhabdomyosarcomas of the head and neck: An update. Otolaryngologic clinics of North America. **22**: 631-636.

Nicory, C. (1923) Rhabdomyoma of the uvula: With a collection of cases of rhabdomyoma. Brit. J. Surg. **11**: 218-222.

O'Day, R.A.; Soule, E.H. and Gores, R.J. (1965) Embryonal rhabdomyosarcoma of the soft tissues. Oral Surg. Oral Med. Oral Path. **20**: 85-93.

Peters, E.; Cohen, M.; Altini, M. and Murray, J. (1989) Rhabdomyosarcoma of the oral and paraoral region. Cancer **63**: 963-966.

Proops, D.W. and Mann, J.R. (1984) The presentation of rhabdomyosarcomas of the head and neck in children. J. Laryng. Otolaryngol. **98**: 381-390.

Raney, R.B. Jr. and Handler, S.D. (1981) Management of neoplasms of the head and neck in children. II Malignant Tumours. Head and Neck Surg. **3**: 500-507.

Regezi, J.A. and Sciubba, J.J. (1989) Oral Pathology: Clinical Pathologic Correlations. W.B. Saunders Company, Philadelphia.

Robbins, S.L. and Kumar, V. (1987) Basic Pathology (4th ed). W.B. Saunders Company, Philadelphia.


Sadeghi, E.M.; Gingrass, D.J.; Surwillo, E.J.; Aderson, T. and Tang, T.T. (1988) Embryonal Rhabdomyosarcoma. *Int. J. Oral Maxillofac. Surg.* **17**: 198-200.

Shafer, W.G.; Hine, M.K. and Levy, B.M. (1983) *A Textbook of Oral Pathology* (4th ed). W.B. Saunders Company, Philadelphia.

Stobbe, G.D. and Dargeon, H.W. (1950) Embryonal rhabdomyosarcoma of the head and neck in children and adolescents. *Cancer* **3**: 826-836.

Stout, A.P. (1946) Rhabdomyosarcoma of the skeletal muscles. *Ann. Surg.* **123**: 447-472.

Sutow, W.W. (1964) Cancer of the head and neck in children. *J. Am. Med. Ass.* **190**: 414-416.



Swart, J.G.; Klopper, S. and Hamersma, T. (1985) Rhabdomyosarcoma of the head and neck. A review of 25 cases. *S.A. J. Surg.* **23**: 88-89.

Walter, J.B. and Israel, M.S. (1987) *General Pathology* (6th ed) Butler and Tanner Limited, London.

Wharam, M.D.; Foulkes, M.A.; Lawrence, W. *et al.* (1984) Soft tissue sarcoma of the head and neck in children: Nonorbital and nonparameningeal sites. A report of the Intergroup Rhabdomyosarcoma Study (IRS) I. *Cancer* **53**: 1016-1019.

Willis, R.A. (1973) The spread of tumours in the human body (3rd ed). Butterworth and Company, London.

Yagi, K.I.; Rahman, A.; Abbas, K. and Prabhu, S.R. (1984) Burkitt's lymphoma in the Sudan. *Int. J. Oral Surg.* **13**: 517-527.

Zachariades, N. and Papanicolaou, S. (1986) Non-endemic Burkitt's lymphoma. *Int. J. Oral Maxillofac. Surg.* **15**: 88-92.



UNIVERSITY *of the*
WESTERN CAPE