

**Maxillary Canine Ectopia and other Developmental
Anomalies on Mixed Dentition Panoramic Radiographs at
the Tygerberg Oral Health Centre**



Full Thesis submitted by:

Dr. Lenita Rebecca Johan
BDS

Student Number: 3318747

For the degree of:

Master of Science in Dentistry

University of Western Cape

Supervisor: Dr. A. Hudson

Co-supervisor: Dr. N. Mohamed

Maxillary Canine Ectopia and other Developmental
Anomalies on Mixed Dentition Panoramic Radiographs
at the Tygerberg Oral Health Centre

Lenita Rebecca Johan

Keywords

Ectopic Maxillary Canines

Developmental Anomalies


Early Diagnosis

Interceptive Orthodontics

Mixed Dentition

Panoramic Radiographs

Dental Age



Abstract

Aim: The aim of this study was to establish whether there is any association between developing maxillary canine ectopia and various other dental anomalies using panoramic radiographs in the mixed dentition stage of development.

Method: A total of 574 mixed dentition panoramic radiographs of children between dental ages 8-12 were used. The prevalence of potentially ectopic maxillary canines and developmental anomalies was noted. Chi-square test of independence was used to determine if the two variables were dependent.

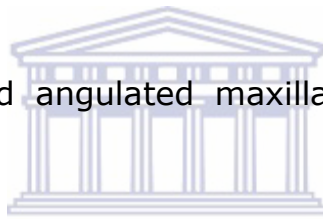Results: The prevalence of potentially ectopic maxillary canines at Tygerberg Oral Health Centre was recorded as 86%. The prevalence of developmental anomalies in cases with potentially ectopic maxillary canines was 23%. These were the statistically significant relationships found between the radiographic markers:

1. Rotated maxillary lateral incisors and distal overlap of the maxillary canine cusp tip over the root of the maxillary lateral incisor.
2. Non-resorption of primary maxillary canines and distal overlap of the maxillary canine cusp tip over the root of the maxillary lateral incisor, overlap over the pulp chamber of the maxillary lateral incisor and angulated maxillary canines greater than 30°.
3. Maxillary canine enlargement and mandibular canine enlargement.

4. Mandibular canine enlargement and mesial overlap of the maxillary canine cusp tip over the root of the maxillary lateral incisor.

The following anomalies showed a statistically significant relationship with individual radiographic markers:

1. Peg-shaped maxillary lateral incisors and mesial overlap of the maxillary canine cusp tip over the root of the maxillary lateral incisor and rotated maxillary lateral incisors
2. Root dilaceration and non-resorption of primary maxillary canines.
3. Supernumerary teeth and non-resorption of primary maxillary canines.
4. Taurodontism and angulated maxillary canines greater than 30° .



Conclusion: Practitioners should clinically examine patients for the maxillary canine bulge at dental age 9, and panoramic radiographs should be used as an adjunct. This study also suggests that peg-shaped maxillary lateral incisors and taurodontism could indicate a risk for developing maxillary canine ectopia. Since developmental anomalies develop earlier than ectopic maxillary canines, practitioners should identify these anomalies and intercept where they can, by monitoring the position of the maxillary canine or extracting the primary maxillary canine.

Declaration

I, Lenita Rebecca Johan, declare that *Maxillary Canine Ectopia and other Developmental Anomalies on Mixed Dentition Panoramic Radiographs at the Tygerberg Oral Health Centre* is my work and it has not been submitted before for any degree or examination in any other university. I confirm that information derived from other sources has been indicated in the thesis and acknowledged as complete references.

Lenita Rebecca Johan

Date: August 2017



Acknowledgements

Firstly, I would like to express my sincere gratitude to my supervisor Dr. A. Hudson and co-supervisor Dr. N. Mohamed for their continuous support through my MSc in Orthodontics, for their patience, immense knowledge and for always being available throughout my study.

I would also like to thank Prof. A. Harris for giving me the opportunity to commence the program. I would have never had the chance to partake in a postgraduate study without you.

I would like to acknowledge Mr. Fareed Davids and Mr. Eric Abrahams for all their help in acquiring various articles to write a thorough literature review.

My deepest appreciation to Prof. J. S Maritz and my dad, Johan Thomas for helping me obtain accurate statistics.

Last but not the least, I would like to thank my husband Jikku Joseph and my family for their unceasing love, constant support and understanding, which took me through the challenging phases of my thesis.

Table of Contents

Title Page	I
Keywords	II
Abstract	III
Declaration	V
Acknowledgments	VI
Table of Contents	VII
List of Tables	X
List of Abbreviations	XII
Appendix A	XIII
Chapter 1 Introduction	1
1.1 Aim	6
1.2 Objectives	6
Chapter 2 Literature Review	7
2.1 Normal development of the maxillary canine	7
2.1.1 Sequence of eruption.....	13
2.2 Aetiology of maxillary canine ectopia.....	14
2.3 Sequelae of maxillary canine ectopia.....	17
2.4 Dental age vs. chronological age.....	18
2.5 Radiographic markers of maxillary canine ectopia.....	19
2.5.1 Rotated maxillary lateral incisors.....	20
2.5.2 Non-resorption of primary maxillary canines	21
2.5.3 Degree of overlap of the permanent maxillary canine cusp tip and maxillary lateral incisor root.....	23
2.5.4 Angulation of the maxillary canines	26
2.5.5 Maxillary and mandibular canine enlargement	26
2.6 Developmental anomalies.....	27
2.6.1 Congenitally missing teeth	27
2.6.1.1 Congenitally missing maxillary lateral incisors	27
2.6.1.2 Aplasia of premolars.....	28
2.6.2 Peg-shaped maxillary lateral incisors	29
2.6.3 Infraocclusion of primary molars	30
2.6.4 Supernumerary teeth	32

2.6.5 Taurodontism	33
2.6.6 Dilaceration	34
2.6.7 Ectopic eruption of permanent first molars	35
Chapter 3 Materials and Methods	37
3.1 Null hypothesis.....	37
3.2 Study design	37
3.3 Sample.....	37
3.3.1 Inclusion criteria	37
3.3.2 Exclusion criteria	38
3.4 Inter/intra-examiner variability	38
3.5 Data collection	39
3.5.1 Radiographic markers for maxillary canine ectopia	39
3.6 Data processing and analysis.....	40
Chapter 4 Results	41
4.1 Prevalence of potentially ectopic maxillary canines.....	41
4.2 Radiographic markers and their comparisons	43
4.3 Developmental Anomalies	48
Chapter 5 Discussion of Results	50
5.1 Prevalence of potentially ectopic maxillary canines.....	50
5.1.1 Limitations.....	53
5.2 Radiographic Markers	55
5.2.1 Rotated maxillary lateral incisors.....	55
5.2.2 Non-resorption of primary maxillary canines	61
5.2.3 Degree of overlap of the permanent maxillary canine cusp tip and maxillary lateral incisor root.....	67
5.2.4 Angulation of the maxillary canines	73
5.2.5 Maxillary and mandibular canine enlargement	74
5.3 Developmental anomalies as predictors of ectopic maxillary canines .	76
5.3.1 Congenitally missing teeth	77
5.3.2 Aplasia of premolars	79
5.3.3 Peg-shaped maxillary lateral incisors.....	80
5.3.4 Infraocclusion of the primary molars.....	82
5.3.5 Supernumerary teeth	83
5.3.6 Taurodontism	84
5.3.7 Dilaceration	86

5.3.8 Ectopic molars.....	88
Chapter 6 Conclusion and Recommendations	89
6.1 Conclusion.....	89
6.2 Clinical Considerations and Recommendations	91
References	94
Appendix A	117



List of Tables

Table 4.1.1: Dental age vs. the prevalence of potentially ectopic maxillary canines.....	41
Table 4.1.2 Prevalence of each radiographic marker for potentially ectopic maxillary canines (n=493).....	42
Table 4.1.3 Prevalence of each radiographic marker at various dental ages.....	42
Table 4.2.1 Occurrence of the other radiographic markers when the primary marker (grey block) already exists at dental age < 10 years (n=89)	43
Table 4.2.2 Occurrence of the other radiographic markers when the primary marker (grey block) already exists at dental age ≥ 10 years (n=404).....	44
Table 4.2.3 Dental age vs. simultaneous occurrence of rotated maxillary lateral incisors and non-resorption of primary maxillary canines.....	44
Table 4.2.4 Extent of overlap of the maxillary canine cusp tip over the root of the maxillary lateral incisor at ≥ 10 years (Total n=404).....	45
Table 4.2.5 Extent of overlap when rotated maxillary lateral incisors and non-resorption of primary canines existed simultaneously at various dental ages.....	46
Table 4.2.6 Prevalence of technical error on a panoramic radiograph in cases with maxillary/mandibular canine enlargement (n=493).....	46

Table 4.2.7 Maxillary lateral incisors that reached Nolla Stage 9 vs dental age.....	47
Table 4.3.1 Prevalence of developmental anomalies in potentially ectopic maxillary canines (n=493).....	48
Table 4.3.2 Presence or absence of developmental anomalies vs selected radiographic markers.....	49



List of Abbreviations

Mx- Maxillary

Mnd- Mandibular

n- Number of Cases

N- Normal

RHS- Right Hand Side

LHS- Left Hand Side



Appendix A

Codes for Data Capture Sheet

A. Radiographic Markers

1. Is maxillary lateral incisor rotation present?	117
2. Is non-resorption of the primary maxillary canines evident?	117
3. What is the degree of overlap of the maxillary canine cusp tip on the root of the maxillary lateral incisor on the RHS?	118
4. What is the degree of overlap of the maxillary canine cusp tip on the root of the maxillary lateral incisor on the LHS?	118
5. Is the angulation of the maxillary canines more than 30 ⁰ to the mid-sagittal plane?	119
6. Are the maxillary canines enlarged?	119
7. Are the mandibular canines enlarged?	120

B. Developmental Anomalies

1. Are there congenitally missing teeth on the RHS?	120
2. Are there congenitally missing teeth on the LHS?	121
3. Is aplasia of premolars present?	121
4. Are peg-shaped maxillary lateral incisors present?	121
5. Is infraocclusion of the primary molars present?	122
6. Are there any supernumerary teeth present on the RHS?	122

7. Are there any supernumerary teeth present on the LHS?.....	123
8. Is taurodontism evident (not tooth specific)?	123
9. Is dilaceration present on the RHS?	124
10. Is dilaceration present on the LHS?	124
11. Are ectopic first molars present?	125

C. Other

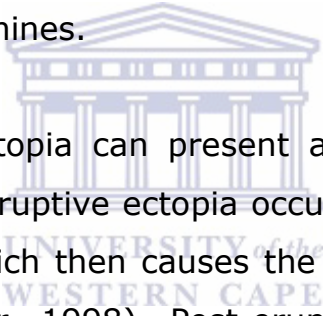
1. Is root resorption of the maxillary central incisors evident?	125
2. Is root resorption of the maxillary lateral incisors evident?	125



Chapter 1

Introduction

Dentists are usually concerned about the developing permanent maxillary canines as they are the last tooth to erupt into the mouth and the one that causes several problems. Usually, limited space is available to accommodate the entire tooth in the maxillary arch of the mouth. The permanent maxillary canines try to erupt in their original position but sometimes they can lose their path, situating them in a new location i.e. they become ectopic maxillary canines.



Maxillary canine ectopia can present as either pre-eruptive or post-eruptive. Pre-eruptive ectopia occurs due to the tooth germ being displaced, which then causes the tooth to erupt along the wrong path (Becker, 1998). Post-eruptive ectopia refers to a tooth that has erupted into the mouth but is out of its normal position (Paul and Raju, 2013). Second to the third molars, maxillary canines are the most frequent non-erupted tooth (Mead, 1930; Moyers, 1988).

It is important to identify maxillary canine ectopia as early as possible. The consequence of late diagnosis of maxillary canine ectopia are root resorption of adjacent teeth (Arens, 1995; Algerban *et al.*, 2009; Sameshima and Sinclair, 2001), impaction of the maxillary canine itself (Kuroi, 2002), migration of adjacent teeth, loss of arch length (Litsas *et al.*, 2011) and formation of dentigerous cysts (Edamatsu *et al.*, 2005). Once the maxillary canine becomes impacted, the process to get the maxillary

canine back into the arch is time consuming, costly and requires surgical treatments, such as surgical exposure of the tooth with alignment (Andreasen, 1971; Kurol *et al.*, 1997; Bjerklin and Ericson, 2006; Falahat *et al.*, 2008).

The diagnosis and treatment of ectopic maxillary canines is a major clinical problem due to the large number of patient factors (eg. chronological age vs. dental age, gender and ethnicity) and treatment variables such as, extraction of the primary maxillary canines. Interceptive treatment should be carefully considered as to which cases require it, the prognosis of each case and most importantly, the optimal treatment timing for each case (Kurol, 2002). The success of Interceptive Orthodontic treatment requires practitioners to be vigilant in the monitoring of dental development during the mixed dentition stage. Dental age is important at this stage, as each phase of eruption of each tooth can be visualized clearly radiographically and can be identified easily (Nystrom *et al.*, 1988).

Maxillary canine ectopia can be diagnosed more easily when practitioners conduct a thorough clinical examination and radiologic assessment. The clinical examination must include the examination of the maxillary buccal canine bulge at dental age of 9 years and a supplementary radiograph should be taken to support the finding (Ericson and Kurol, 1986b; Rayne 1969; McSherry, 1998).

The most recent United Kingdom guidelines (Isaacson and Thom, 2001) on the use of radiographs for orthodontic diagnosis recommend that when a maxillary canine is unerupted and not palpable at 10-11 years (Ericson and Kurol, 1986b), radiographic

examination is indicated (Isaacson and Thom, 2001). If a permanent tooth has erupted on one side of the mouth, but the contralateral tooth remains unerupted, a radiograph should be taken to investigate any potential problems (Mosby, 1986).

There are several forms of dental imaging such as periapical radiographs, panoramic radiographs and cone beam computed tomography (CBCT). Cone beam computed tomography detects up to 50% more instances of root resorption than panoramic radiographs (Ericson and Kurol, 1987b). It also gives more detail about the relationship between the canine and the incisors (Duterloo, 1991) but most general practices have no access to this technology as it is expensive and is not a routine method for the diagnosis of ectopic maxillary canines (Shapira and Kuflinec, 1998).

On the other hand, a panoramic radiograph enables the clinician to draw up a comprehensive diagnostic list. It allows one to view the entire mouth on a single film (Moyers, 1988). The various phases of eruption of teeth can be visualized with the aid of the panoramic radiograph. The practitioner can compare the dental age to the chronological age of the patient and perhaps isolate any tooth or teeth that erupt outside the normal sequence (Hudson *et al.*, 2009). The cause of the disruption in the series may often be visible on the panoramic radiograph (Suri *et al.*, 2004). In addition, the accelerated or delayed eruption process can be viewed on the panoramic radiograph (Suri *et al.*, 2004).

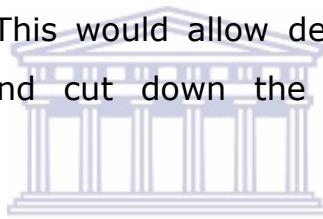
A mixed dentition panoramic radiograph may be used to:

- Gauge dental maturity (Wellbury and Kilpatrick, 2001; Profit, 1986; American Academy of Pediatric Dentistry Reference Manual, 2001). It may show a generalized acceleration or delay in biologic maturity (Suri *et al.*, 2004).
- Identify developmental anomalies (Patti and Perrier, 2005; American Academy of Paediatric Dentistry Reference Manual, 2001).
- Monitor the developing canines and assess the sequence of eruption (Wellbury and Kilpatrick, 2001; Patti and Perrier, 2005; Ericson and Kurol, 1988a).
- Assess the presence, position, and morphology of unerupted teeth (Wellbury and Kilpatrick, 2001; American Academy of Paediatric Dentistry Reference Manual, 2001; Patti and Perrier, 2005).
- Recognize compromised leeway space as indicated by
 - a) Missing primary teeth (Moyers, 1988),
 - b) Tilting of first permanent molars and permanent incisors (Moyers, 1988) or,
 - c) Infraocclusion of primary molars (Hudson *et al.*, 2007)

Ectopic maxillary canines have previously been linked to developmental anomalies such as congenitally missing teeth, aplasia of premolars, peg-shaped lateral incisors, infraocclusion of primary molars and ectopic molars (Baccetti, 1998 and Mercuri *et al.*, 2013). Developmental anomalies are marked deviations from the normal, which can be caused by local and systemic factors (Guttal *et al.*, 2010) and may affect the colour, shape, size, position, number and degree of development of one or more of the teeth. On the other hand, supernumerary teeth,

taurodontism and dilaceration have not been previously linked to ectopic maxillary canines. Even though ectopic maxillary canines may occur in dentitions without any developmental anomalies, these anomalies could possibly be early predictors of maxillary canine ectopia as they are considered easier to identify when compared to ectopic maxillary canines (Sorensen *et al.*, 2009; Baccetti, 1998).

It is vital to conduct the present study to emphasize the importance of detecting ectopic maxillary canines at an early stage by looking at the radiographic markers and developmental anomalies that may possibly act as predictors of ectopic maxillary canines. This would allow dentists to provide shorter treatment plans and cut down the costs of treatment for patients.



Studies have previously found the prevalence of palatally displaced maxillary canines or impacted canines (Thilander and Jakobsson, 1968; Ericson and Kuroi, 1987a, 1986a and 1986b; Kramer and Williams, 1970; Baccetti, 1998a; Brin *et al.*, 1986; Chu *et al.*, 2003). No previous studies were conducted on the South African population to determine the prevalence of potentially ectopic maxillary canines or to find out their association with developmental anomalies using panoramic radiographs.

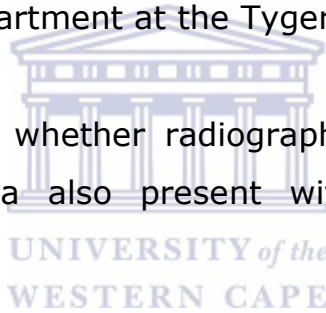
The present study was conducted at the Tygerberg Oral Health Centre in Cape Town as it is a well-known public hospital that has a good inflow of paediatric patients and is a fair representation of the general Western Cape population.

1.1 Aim

The aim of this study was to establish whether there is an association between developing maxillary canine ectopia and various other dental anomalies using panoramic radiographs in the mixed dentition stage of development.

1.2 Objectives

1. To determine the prevalence of potentially ectopic maxillary canines in mixed dentition panoramic radiographs of patients presenting at the Paediatric Dentistry Department at the Tygerberg Oral Health Centre.
2. To determine whether radiographs with known maxillary canine ectopia also present with other developmental anomalies.
3. To determine whether the presence of developmental anomalies can be used to predict maxillary canine ectopia.



Chapter 2

Literature Review

2.1 Normal development of the maxillary canine

To identify potentially ectopic maxillary canines, one needs to know the normal developmental pathway of the maxillary canines. "No tooth is more interesting from a development point of view" than the maxillary canine (Dewel, 1949). The maxillary canine tooth buds have the longest period of development. Eruption time of a maxillary canine can vary from 9.3 to 13.1 years (Ericson and Kurol, 1986b; Hurme, 1949). Normally, the maxillary canines follow a certain sequence of movements from the point of migration to the original position of the maxillary canine within the mouth (Dewel, 1949; Newcomb, 1959). This can be described in 5 stages:

Stage 1: The calcification of the permanent maxillary canine crown starts at 1 year of age between the roots of the first primary molar and is complete at 7 years (Broadbent, 1941). As the primary first molar erupts, the permanent maxillary canine crown is left behind, allowing the first premolar to develop between the roots of the primary first molar (Broadbent, 1941; Coulter and Richardson, 1997).

Stage 2: The first transitional stage, otherwise known as mixed dentition stage begins at dental age 6 with the eruption of the mandibular first permanent molars and mandibular central incisors (Schour and Massler, 1941; Proffit, 1986).

The permanent maxillary canines, first premolars and first primary molars appear to “stack up” one above another to lie in a vertical row (Nanda, 1983; Duterloo, 1991). The distal surface of the permanent maxillary canines and the mesial surface of the maxillary first premolars are in close proximity (Duterloo, 1991).

The main event at the dental age of 7 years is the eruption of the maxillary central incisors and mandibular lateral incisors with the permanent maxillary canines and premolars still in the crown stage or just beginning root formation (Proffit *et al.*, 2007). The permanent maxillary canine crown lies medial to the root of the primary maxillary canine crown and there is a vertical overlap of approximately 3mm (Noyes, 1930).

The dental age of 8 years coincides with the clinical appearance of the maxillary lateral incisors. No resorption of the primary maxillary canines is seen. There is a delay of 2 to 3 years before any further permanent teeth develop, but in the meantime, root development can be seen in various teeth (Proffit *et al.*, 2007).

Stage 3: During the inter-transitional stage (9 to 10 years), more commonly known as the ugly duckling stage:

Root development of the permanent maxillary canine is in its beginning stages at dental age 9. The maxillary lateral incisors have not reached Nolla Stage 9 i.e. fully formed root with an open apex. It is normal for the primary maxillary canines to remain non-resorbed or the amount of root resorption of the primary maxillary canine is relative to the position of the crown of the permanent maxillary canine (Duterloo, 1991).

The permanent maxillary canine appears to move in a buccal direction from a position lingual to the root apex of the primary maxillary canine (Coulter and Richardson, 1997). With a sufficient increase in the size of the subnasal area, the permanent maxillary canine gradually begins to up-right at dental age 9 by moving downward, forward and laterally away from the root end of the permanent lateral incisor (Coulter and Richardson, 1997).

Between dental age 9 and 10 years, the maxillary canine buccal bulge located apical to the root of the primary maxillary canine should become clinically palpable (Shapira and Kuftevec, 1998; Nanda, 1983) but it can be clinically palpated as early as 8 years (Kettle, 1957).

According to Nanda (1983), the permanent maxillary canine exerts pressure on the root of the maxillary lateral incisor, causing the maxillary lateral incisors to tip towards the midline. The crown of the maxillary lateral incisor tips distally, possibly creating a space or diastema between the permanent incisors. The physiological diastema if present, closes once the permanent maxillary canine erupts along the distal aspect of the roots of the maxillary lateral incisor, thereby correcting the so-called "Ugly Duckling" stage (Kuroi *et al.*, 1997; Broadbent, 1941).

At dental age 10, roots of the permanent mandibular incisors are completed while the maxillary lateral incisors are at Nolla Stage 9 (Proffit *et al.*, 2007). At this stage, half the root of the permanent maxillary canine has formed, but active eruption has not yet started (Duterloo, 1991). The resorption of the primary

maxillary canines should be clearly visible in the apical third of the root (Proffit *et al.*, 2007; Duterloo, 1991).

Stage 4: At the beginning of the second transitional stage during dental age 11:

The permanent maxillary canines are actively erupting and three-quarter of the root is formed, the roots of primary canines are almost completely resorbed (Duterloo, 1991). The “stacking” described in the first transitional stage disappears when the primary maxillary canines and molars shed increasing the primary intercanine width (Nanda, 1983). This increase in the intercanine width allows the larger permanent incisors to be accommodated in the arch (Moyers *et al.*, 1976). Dental age 11 is characterized by the eruption of the mandibular canine and the first maxillary and mandibular premolars (Mosby, 1986).

Stage 5: The final stage of the second transitional period occurs at dental age 12. The permanent maxillary canines have erupted, and the primary maxillary canines have completely resorbed at this stage (Proffit *et al.*, 2007). The final position of the permanent maxillary canine upon completion of the eruption is between the maxillary lateral incisor and maxillary first premolar (Nanda, 1983).

If the developing permanent maxillary canines sway away from their trajectory, there is a greater risk of abnormal development due to the prolonged exposure to various environmental factors (Dewel, 1949).

Observation of the permanent maxillary canine eruption should begin no later than 10 years (Duterloo, 1991). In individual cases, even earlier evaluation may be necessary (Ericson and Kurol, 1986a). The objective of early interceptive treatment is to attempt to reverse the disturbance with a view to allowing normal development to proceed (Hudson *et al.*, 2010).

There are 3 theories related to the normal eruption of the maxillary canines i.e. the guidance theory, genetic theory and the sequential theory.

a) Guidance theory of eruption of maxillary canines

Researchers have supported Miller (1963) and Bass's (1967), theory of eruption of the maxillary canine, which originated from Broadbent's (1941) observations. They suggested that the permanent maxillary lateral incisor root was large enough to guide the crown of the permanent maxillary canine through its normal eruption pathway. They noticed the maxillary canines were displaced in cases where the maxillary lateral incisors were either congenitally missing or peg-shaped.

In the absence of the maxillary lateral incisor guidance, the canine is said to continue in its normal strong mesial and palatal eruption pathway, as opposed to the downward-guided movement along the distal aspect of the maxillary lateral incisor (Becker, 1998).

On the other hand, peg-shaped lateral incisors can obstruct the corrective movements of the maxillary canine after it has initially deviated in a palatal direction from its physiological

eruption pathway. The developed root of the peg-shaped lateral incisor prevents the maxillary canine from moving into an up-right position to fit into the dental arch, bringing about ectopic maxillary canines (Sajnani, 2015).

b) Genetic theory of eruption of maxillary canines

Several studies suggested that ectopic maxillary canines occur due to various genetic factors and are associated with other genetically interrelated dental anomalies such as ectopic molars (Bjerklin *et al.*, 1992; Baccetti, 1998) and congenitally missing teeth (Pirinen *et al.*, 1996; Baccetti, 1998).

Female predominance (Becker *et al.*, 1981; Ericson and Kuroi, 1988a) and bilateral occurrence (Ericson and Kuroi, 1988a; Becker *et al.*, 1981) of palatally displaced canines are like other dental anomalies of genetic origin. Familial occurrence (Zilberman *et al.*, 1990; Svinhufvud *et al.*, 1988) and population differences (Kramer and Williams, 1970; Montelius, 1932) imply that palatally displaced canines is a product of one group of genes that together control the trait i.e. polygenic multifactorial inheritance (Peck *et al.*, 1994).

c) Sequential theory of eruption of maxillary canines

The sequential theory proposed by Sajnani and King (2012) postulated a sequence in which the genetic and guidance theories may influence different stages during the eruption of the maxillary canine. It postulates that both buccally and palatally displaced maxillary canines share similar aetiologies. The role of genetics and local factors, especially the maxillary lateral

incisors, play a critical role during the development of the maxillary canine at various stages.

2.1.1 Sequence of eruption

Mosby (1986) stated that a change in the sequence of eruption is a reliable sign of disturbance in normal development rather than a generalized delay or acceleration. The more a tooth deviates from its expected position in the sequence, the greater the probability of problems occurring.

In 1953, Lo and Moyers studied the sequence of eruption in a Canadian population. The authors found 18 different sequences in the maxillary arch and 17 different sequences in the mandibular arch. Collectively they found that the most frequently seen combination of sequences of 6 1 2 4 5 3 7 for the maxilla and 6 1 2 3 4 5 7 for the mandible produced the highest percentage of Class I occlusions.

Normal variations in the sequence of eruption have clinical significance. These include eruption of maxillary canines ahead of the premolars in the maxillary arch and asymmetries in eruption between the right and left sides (Proffit *et al.*, 2007). However, if the maxillary canines and maxillary first premolars erupt simultaneously, the maxillary canines can be forced labially (Proffit *et al.*, 2007). This often occurs when there is a lack of space in the arch and the maxillary canine tooth bud is labially positioned (Proffit, 1986).

2.2 Aetiology of maxillary canine ectopia

The exact aetiology of ectopic maxillary canines is unknown. Local predisposing factors that affect the tortuous path of eruption of the maxillary canine were predominantly late developing dentition, congenitally missing teeth, peg-shaped maxillary lateral incisors, crowding, excessive space and other factors such as trauma.

1. Late developing dentition- Becker and Chaushu (2000), pointed out that a generalized delay in the eruption process could be considered as a potential indicator for palatally displaced maxillary canines. The radiographic study showed that among patients with palatally displaced maxillary canines, approximately half had delayed dental development. Buccal displacement of the maxillary canine, however, was not associated with the late development of the dentition.

Newcomb (1959) noted an apparent link between maxillary canines and generalized lateness of the dentition. He studied the migration process of teeth (in particularly the maxillary canines) in various cases at intervals during the mixed dentition stage. He stated that a slow rate of tooth formation, as well as delayed exfoliation of the primary teeth, could be the cause for the maxillary canines not erupting.

Late development of the maxillary lateral incisors may be more disruptive for the path of eruption of the maxillary canines than missing maxillary lateral incisors (Leifert and Jonas, 2003). In the presence of late developing maxillary lateral incisors, any corrective movement of the permanent maxillary canines is prevented, and the vertical development of the maxillary canine

may only occur on the palatal side (Becker, 1998). This direct obstruction of the normal pathway of the maxillary canine by the late developing maxillary lateral incisor is believed to be the reason for palatally displaced maxillary canines.

2. Congenitally missing teeth- In support of the guidance theory (refer to section 2.1, Page 11), Brin *et al.*'s (1986) study showed that 1% of a randomly selected population had missing maxillary lateral incisors but this was five times higher (5.5%) in a sample with displaced maxillary canines. Miller (1963), Becker *et al.* (1981) and Bass (1967) have also reported palatally displaced canines with congenitally missing laterals. In support of the genetic theory, several authors suggested that palatally displaced canine occurs due to genetic reasons as it often occurred simultaneously with other developmental anomalies, of which congenitally missing laterals is one of them (Zilberman *et al.*, 1990; Pirinen *et al.*, 1996 and Baccetti, 1998).
3. Peg-shaped maxillary lateral incisors- Brin *et al.* (1986) showed that of the patients with palatally displaced canines, only 52% had a normal shaped maxillary lateral incisor compared to the general population (93%). Other researchers also found a significantly higher incidence of peg-shaped lateral incisors in patients with a palatally displaced maxillary canine (Becker *et al.*, 1981). Various authors support the genetic theory as they found palatally displaced canines occurring simultaneously with peg-shaped maxillary lateral incisors (Peck *et al.*, 1994; Zilberman *et al.*, 1990; Baccetti, 1998).

4. Crowding- As mentioned earlier, the maxillary canine is the last tooth to erupt in the maxillary arch thus their position in the dental arch depends on the availability of space (Becktor *et al.*, 2005). The lack of space may be due to the early loss of the primary maxillary molars (Hitchin, 1956; Fastlicht, 1954).

Crowding may be a factor in the labial displacement of the maxillary canines, but not in the palatal displacement of maxillary canines (Thilander and Jakobsson, 1968). They found the greatest amount of crowding to be near the labially situated maxillary canine. Developmentally, the maxillary canine is labially positioned. Hence, if the maxillary canine remains unerupted due to arch length deficiency, the maxillary canine can only be placed on the labial side (Thilander and Jakobsson, 1968).

5. Excessive Space- Jacoby (1983), Becker (1984) and Brin *et al.* (1986), further suggested that the explanation for the palatal displacement of the maxillary canine could have been the presence of excessive space in the maxillary canine area. This allows the maxillary canine to move palatally through the bone and find a place behind the buds of other teeth.

Other Factors- Brin *et al.* (1993) suggested that trauma to the maxillary lateral incisor causes shortness of the root at an early stage of development, which brings about the palatal displacement of the maxillary canine. They explained that trauma might cause movement of the maxillary lateral incisor or conduction movement of the permanent maxillary canine itself. Alternatively, trauma could possibly cause dilaceration of the root of the affected primary tooth, which can possibly

lead to an abnormal developmental position of the permanent tooth germ (Andreasen, 1981).

Kettle (1958) went on to list another aetiologic possibility, namely dentigerous cysts, that could equally deflect the path of eruption of the permanent maxillary canine. Becker *et al.* (1981) suggested hypopituitarism, cleidocranial dysostosis and cleft lip and palate as additional factors predisposing to the palatal displacement of the maxillary canines.

2.3 Sequelae of maxillary canine ectopia

Ectopic teeth can cause root resorption of adjacent teeth, impaction, migration of adjacent teeth, loss of arch length and formation of dentigerous cysts.

The most important sequela of an ectopic maxillary canine is root resorption of adjacent teeth (Litsas and Acar, 2011). Although the maxillary lateral incisor is most commonly affected by the ectopic eruption of maxillary canine, there is also evidence of central incisor root resorption (Arens, 1995; Algerban *et al.*, 2009; Sameshima and Sinclair, 2001). The first premolar was rarely resorbed (Postletwaite, 1989; Walker *et al.*, 2005).

Root resorption of maxillary lateral incisors by palatally displaced ectopic maxillary canines frequently occurred between 11-12 years (Ericson and Kuroi, 1988b) and rarely started after 14 years of age (Houston *et al.*, 1992). In a study conducted by Ericson and Kuroi (2000), 9% of the maxillary central incisors resorbed adjacent to an ectopic maxillary canine and 38% of the maxillary lateral incisors had resorbed adjacent to an ectopic

maxillary canine. About 60% of the resorption of maxillary central and maxillary lateral incisors involved the middle and apical thirds of the root adjacent to an ectopic maxillary canine.

Abnormal eruption paths within the dentoalveolar process may result in impaction of the permanent maxillary canine. Non-erupted or partly erupted maxillary canines may increase the risk of infection and can compromise the lifespan of adjacent teeth by root resorption as mentioned earlier (Power and Short, 1993). Rimes *et al.* (1997) stated that the lateral incisor often produced a low-grade pain and had insignificant mobility, although up to two-thirds of the root may have been destroyed. This pathological condition is often realized late (mean age of 12.5 years).

Another complication is the expansion of dental follicles that results from the accumulation of fluid between the tooth crown and epithelial components, which may contribute later to the formation of cysts (Edamatsu *et al.*, 2005). Dentigerous cysts are odontogenic lesions that arise from the follicle of unerupted or embedded teeth (Avitia *et al.*, 2007). The maxillary canines are the teeth most commonly affected (Ishikawa, 1982).

2.4 Dental age vs. chronological age

Dental age is significant for the early identification of the developing ectopic maxillary canine and for its timeous management. Dental and chronologic ages are poorly correlated (Proffit, 1986). Poor correlations between the two suggest that dental age is an independent measurement for biological age and should be measured separately (Leurs *et al.*, 2002). Dental age

is relevant when monitoring the mixed dentition to assess the need for interceptive orthodontic treatment (Duterloo, 1991; Moyers, 1988).

A combination of the assessment of the stages of the crown and root formation, tooth eruption and resorption of primary teeth reduces the error of dental age calculation during the mixed dentition phase (Ul-Hamid *et al.*, 2004; Proffit *et al.*, 2007). There are numerous methods for estimating dental age described in the literature (Demirjian *et al.*, 1973; Nolla, 1960; Cameriere *et al.*, 2006; Haavikko, 1970; Proffit, 1986; Garn *et al.*, 1959 and Moorrees *et al.*, 1963). For the purpose of this study, the Proffit method of age estimation (refer to section 2.1) is used since it is widely used and has been shown to be highly accurate despite its relative simplicity (Elgamri, 2016).

2.5 Radiographic markers of maxillary canine ectopia

As the permanent maxillary canines are palpable from 1 to 1.5 years before they emerge, the absence of the canine bulge after the age of 10 years is a good indication that the tooth is displaced from its normal position (Jacoby, 1983; Ericson and Kurol, 1986b). In this study, patients could not be clinically examined. Radiographic assessment was thus used.

As mentioned earlier in Chapter 1, the position of the ectopic maxillary canine gauged radiographically is instrumental in helping the dentist make good decisions during treatment planning. Key criteria must be carefully assessed.

Early radiographic predictors of maxillary canine ectopia

(Hudson *et al.*, 2010) include:

- Rotated maxillary lateral incisors
- Non-resorption of the primary maxillary canines
- Overlap between the cusp tip of permanent maxillary canine and root of permanent maxillary lateral incisor
- Angulation of maxillary canines greater than 25° and 30° to the mid-sagittal plane
- Size of the maxillary and mandibular canines in relation to the right and left sides
- Presence of developmental anomalies

2.5.1 Rotated maxillary lateral incisors

Not much research has been done on rotation of the maxillary lateral incisors. However, a study conducted by Liuk *et al.* (2013), showed that the maxillary lateral incisors were more mesiolabially rotated by 11.7° in the presence of palatally displaced canines. The present study hopes to determine whether a rotated maxillary lateral incisor can actually cause an ectopic eruption of the permanent maxillary canine.

Tooth rotation is defined as “distinct mesiolingual or distolingual displacement of the tooth around its longitudinal axis” (Baccetti, 1998). Maxillary lateral incisor rotation can be unilateral or bilateral (Baccetti, 1998). The presence of rotation of the maxillary lateral incisor may lead to root resorption of the maxillary lateral incisor (Kuroi, 2002; Hudson *et al.*, 2009).

On a panoramic radiograph, it is challenging for a practitioner to identify maxillary lateral incisor rotation clearly. Hence, for the

purposes of this study, the normal morphology of the maxillary lateral incisor is used as a guide to determine the presence of rotations.

Radiographically, when the maxillary lateral incisor is not rotated, the incisal edge of the crown is straight and parallel to the occlusal plane. The relatively distinct feature is the presence of both ridges i.e. the mesial marginal ridge and the distal marginal ridge (Nelson and Ash, 2010). Usually, the mesial and distal outlines of the crown make a straight drop downward from the incisal angles to the contact areas. The deep V-shaped lingual fossa can also be clearly seen.

If the maxillary lateral incisor is rotated, only one of the ridges would be visible and the V-shaped lingual fossa would be absent. The curvature of the cervical line is distinct in the direction of the incisal edge when the maxillary lateral incisor is rotated (Nelson and Ash, 2010).

2.5.2 Non-resorption of primary maxillary canines

External root resorption occurs at the apical and cervical regions, and it causes a smooth resorption pattern, resulting in blunting of the root apex (White and Pharoah, 2010). When external root resorption involves the lateral aspects of roots, it causes an irregular resorption pattern where, one side is resorbed more than the other (White and Pharoah, 2010). This can occur unilaterally or bilaterally (Peck *et al.*, 1994).

Resorption of primary maxillary canines should have begun by dental age 10 and have completely resorbed by dental age 12

(Van der Linden and Duterloo, 1976) as discussed earlier in section 2.1.

In the present study, a tooth was considered resorbed if there was:

1. An overlap of the crown of the permanent maxillary canine over the root of the adjacent maxillary central or lateral incisor (Ericson and Kurol, 1987b).
2. A space is evident between the crown of the permanent maxillary canine and the resorbing root of the primary maxillary canine.
3. The root contour was uneven in resorbed parts of the root (Ericson and Kurol, 1987b).

Lappin (1951) put forward non-resorption of the root of the primary maxillary canine as a possible cause for maxillary canine ectopia. In support of Lappin's (1951) theory, various studies have shown the subsequent eruption of the displaced maxillary canines, following the extraction of non-resorbed primary maxillary canines (Howard, 1967; Ericson and Kurol, 1988a; Lindauer *et al.*, 1992; Power and Short, 1993).

Ericson *et al.* (2002) however suggested that root resorption of the primary maxillary canines was merely a consequence of maxillary canine ectopia rather than a cause of it. As part of the eruptive mechanism of the permanent maxillary canine, the active pressure exerted during the phase of eruption, the various cellular changes and the actual physical contact between the adjacent primary teeth and the permanent maxillary canine, brings about root resorption of the primary maxillary canine.

Becker (1998) considered another situation to contradict Lappin's (1951) theory. He suggested that the erupting permanent maxillary canine provides the stimulus for the resorption of the roots of the primary maxillary canine and that a portion of the root far from the permanent canine may be unaffected by this process, thus bringing about non-resorption of the primary maxillary canine.

2.5.3 Degree of overlap of the permanent maxillary canine cusp tip and maxillary lateral incisor root

Cusp tip location of the maxillary canine on a panoramic radiograph is a significantly accurate indicator of potential unerupted ectopic maxillary canines (Warford *et al.*, 2003).

The amount of overlap determines the outcome of the interceptive treatment. A positive outcome of interceptive treatment decreases if the erupting maxillary canine overlaps more than half of the root of the maxillary lateral incisor at dental age 11 (Ericson and Kuroi, 1988b; Power and Short, 1993).

An overlap between the crown of the erupting maxillary canine and the permanent maxillary lateral incisor may be considered normal prior to the maxillary lateral incisor reaching Nolla stage 9 (Fernandez *et al.*, 1998). After Nolla stage 9 (refer to page 9), the maxillary canine was considered to be potentially ectopic if there was an overlap.

Ericson and Kuroi (1988a) suggested a method to locate the

unerupted maxillary canine cusp tip relative to the maxillary lateral incisor root using one of four sectors (Lindauer *et al.*, 1992):

- Sector 1 was the area distal to the distal heights of contour of the maxillary lateral incisor crown and root i.e. there is no overlap of the maxillary canine cusp tip over the root of the maxillary lateral incisor.
- Sector 2 was mesial to sector 1 but distal to a line bisecting the mesiodistal dimension of the maxillary lateral incisor along the long axis of the tooth i.e. the cusp tip of the permanent maxillary canine lies distal to the pulp chamber of the root of the maxillary lateral incisor.
- Sector 3 was mesial to sector 2 but distal to the mesial heights of contour of the maxillary lateral incisor crown and root i.e. the cusp tip of the permanent maxillary canine lies mesial to the pulp chamber of the root of the maxillary lateral incisor.
- Sector 4 included all areas mesial to sector 3 i.e. there is no overlap of the cusp tip of the permanent maxillary canine on the root of the maxillary lateral incisor. However, the cusp tip of the permanent maxillary canines lies mesial to the root of the maxillary lateral incisor.

The sector method used to gauge maxillary canine displacement and predict the non-eruption of the maxillary canine was found to have the highest odds of non-eruption of the maxillary canine occurring in sectors 3 and 4 (Warford *et al.*, 2003).

Lindauer *et al.* (1992) found that 78% of cases with non-erupted maxillary canines exhibited overlapping over the root of the maxillary lateral incisors in sectors 2, 3 and 4.

Baccetti *et al.* (2008) modified Ericson and Kurol's classification (1988a) and measured the medial crown position of the maxillary canine through sectors 1 to 5:

- Sector 1 corresponded to the primary maxillary canine (present or absent).
- Sector 2 was the area from the distal aspect of the maxillary lateral incisor to the midline of the maxillary lateral incisor.
- Sector 3 was the area from the midline of the maxillary lateral incisor to the distal aspect of the maxillary central incisor.
- Sector 4 corresponded to the area from the distal side of the maxillary central incisor to the midline of the central incisor.
- Sector 5 was designated to the area from the midline of the central incisor to the midline of the maxillary arch.

Baccetti's modification showed a high rate of reproducibility (0.94). Both methods gave accurate results.

For the purposes of this study, Ericson and Kurol's (1988a) original method was used to evaluate the degree of overlap of

the permanent maxillary canine cusp tip to the root of the maxillary lateral incisor. However, Sectors 3 corresponded to the maxillary canine cusp tip that lay directly over the pulp chamber and sector 4 was all areas mesial to the pulp chamber. Therefore, four positions were noted i.e. no overlap, distal to the pulp chamber, on the pulp chamber and mesial to the pulp chamber.

2.5.4 Angulation of the maxillary canines

Angulation of the maxillary canines to the mid-sagittal plane appears to be less significant than the amount of overlap between the cusp tip of the maxillary canine and the root of the maxillary lateral incisor (Warford *et al.*, 2003).

When the maxillary canine has an angulation greater than 30° (age not mentioned) it suggests that the maxillary canine has a greater tendency to become impacted (Power and Short, 1993).

A favourable inclination for the maxillary canine in the arch is no more than 30° to the mid-sagittal plane (Power and Short, 1993). The internal angle is measured between the long axis of the maxillary canine and the midline (Ericson and Kuroi, 1988a). Landmarks on the panoramic radiograph such as the intermaxillary suture, anterior nasal spine, nasal septum and internasal suture, demarcates the midline (Sajjani and King, 2012).

2.5.5 Maxillary and mandibular canine enlargement

An enlarged radiographic image of a maxillary/mandibular canine in comparison to its opposite number and surrounding teeth

indicates palatal positioning of the tooth on the panoramic radiograph (Hudson *et al.*, 2009; Mason *et al.*, 2001; Duterloo, 1991).

Palatally displaced maxillary canines have been studied by several authors but all the cases in the various studies clinically and radiographically verified the palatal positioning of the maxillary canine (Becker *et al.*, 1984 and 1981; Baccetti, 1998a; Nagpal *et al.*, 2009; Shapira and Kuftinec, 1998; Liuk *et al.*, 2013; Ericson and Kurol, 1988a; Peck *et al.*, 1994). Very few studies have examined ectopic mandibular canines and their possible role in identifying maxillary canine ectopia.

2.6 Developmental anomalies

2.6.1 Congenitally missing teeth

By definition, congenitally missing teeth are those that fail to erupt into the oral cavity and also remain invisible on radiographs (Pemberton *et al.*, 2005).

Congenitally missing teeth can also be referred to as hypodontia, oligodontia or anodontia. Identifying and counting the teeth present may diagnose missing teeth (White and Pharoah, 2010; Endo *et al.*, 2006).

2.6.1.1 Congenitally missing maxillary lateral incisors

Several authors have suggested that congenitally missing maxillary lateral incisors can cause the permanent maxillary canine to become ectopically placed (Becker, 1998; Becker *et*

al., 1981; Nanda, 1983; Brin *et al.*, 1986; Peck *et al.*, 1996; Miller, 1963 and Bass, 1967).

Late development of the lateral incisor has been discussed earlier (refer to section 2.2). Clinicians should look for signs of late development before the maxillary lateral incisors are considered congenitally missing. Late development of the maxillary lateral incisor can be identified on the panoramic radiograph, by meticulously assessing the roots of the mandibular lateral incisors i.e. the mandibular lateral incisors have erupted, half the root of the permanent maxillary canine has formed (dental age 10) and there is still no sign of the maxillary lateral incisor bud.

When the permanent maxillary lateral incisors are missing, the developing permanent maxillary canines need to be monitored as the root of the primary maxillary lateral incisor may not be large enough to guide the maxillary canine, thus resulting in maxillary canine ectopia (Becker *et al.*, 1981). The maxillary canines may then occupy the space of the congenitally missing maxillary lateral incisors and the primary maxillary canines may be retained (Nanda, 1983).

2.6.1.2 Aplasia of premolars

A few studies have shown that aplasia of premolars can cause ectopic eruption of the permanent maxillary canines (Baccetti, 1998a; Bjerklin *et al.*, 1992).

The development of teeth may vary markedly between individuals. Since premolars show high variability in the initiation of calcification (White and Pharoah, 2010; Wisth *et al.*, 1974;

Nik-Hussein, 1989; Arte and Pirinen, 2004), they are only considered congenitally missing after the dental age of 7 to avoid any false positive diagnosis (Goya *et al.*, 2008). Others may erupt as late as a year after the contralateral tooth (White and Pharoah, 2010).

Aplasia of premolars could possibly create arch length discrepancies (Kokich, 2005), making it difficult for the maxillary canine to erupt into its normal position.

2.6.2 Peg-shaped maxillary lateral incisors

Peg-shaped maxillary lateral incisors have been suggested as an aetiological factor for ectopic maxillary canines (refer to section 2.2). Studies have shown that there is a higher prevalence of palatally displaced ectopic maxillary canines in cases with peg-shaped maxillary lateral incisors (Becker *et al.*, 1984 and 1981). Baccetti (1998a), found a prevalence of 34% of peg-shaped maxillary lateral incisors in his study.

Miller (1963) assumed that a peg-shaped lateral incisor would develop a root of more or less normal root length. He justified that this, in turn, would provide the necessary guidance to the maxillary canine. Hence, peg-shaped maxillary lateral incisors could not be an aetiological factor of maxillary canine ectopia. However, Becker (1998) disregarded Miller's (1963) concept. He stated that peg-shaped maxillary lateral incisors develop much later than normal maxillary lateral incisors. As the roots of the peg-shaped maxillary lateral incisors are rudimentarily formed, they cannot provide guidance for the developing maxillary canine, therefore displacing the maxillary canine out of its

normal trajectory.

From clinical observations, Becker *et al.* (1981) suggested that the delay in the development of the peg-shaped maxillary lateral incisors could be as late as 3 years, as opposed to calcification of normal maxillary lateral incisors beginning at 10-12 months.

The dimensions of maxillary lateral incisors are classified using the criteria established by Becker *et al.* (1981). They are either peg-shaped when the mesiodistal width was greatest at the cervical margin or small when the mesiodistal width was equal to or smaller than that of its mandibular counterpart. The remaining permanent teeth may have a slightly smaller mesiodistal size in the presence of peg-shaped lateral incisors (Neville *et al.*, 2009).

2.6.3 Infraocclusion of primary molars

Baccetti (1998a), Bjerklin *et al.* (1992) and Shalish *et al.* (2010) have suggested that infraocclusion of primary molars can cause ectopic eruption of the maxillary canines.

Infraocclusion describes the position of a tooth that fails to maintain its occlusal relationship to adjacent and opposing teeth (Winter, 2001). Although most infraoccluded primary molars reach the plane of occlusion, they descend below the plane of occlusion during growth and development of the jaw (Winter, 2001; Kurol and Thilander, 1984).

Infraoccluded primary molar teeth are often referred to as ankylosed molars and rarely “secondary retention” (Raghoobar *et al.*, 1991). Secondary retention occurs when the primary

molar stops erupting after emergence (Raghoobar *et al.*, 1991) and becomes submerged below the occlusal plane.

Based on the infraoccluded tooth's relationship with the surrounding hard and soft tissues, infraocclusion may be classified as being slight, moderate or severe (Winter, 2001; Ekim and Hatibovic-Kofman, 2001).

Infraocclusion of primary molars was diagnosed when the distance between the affected teeth and the occlusal plane was more than 1mm (Baccetti, 1998). It can also be diagnosed by a "step" in the occlusal plane and the marginal bone contour slopes toward the ankylosed primary molar from the levels of the adjacent teeth (Kurol and Olson, 1991; Rygh and Reitan, 1963).

Posterior teeth are more frequently affected than anterior teeth, with the mandibular first primary molars being most commonly affected (Hudson *et al.*, 2007). There appears to be an equal gender distribution (Winter, 2001; Brown, 1981; Kurol, 2002).

The condition may occur unilaterally or bilaterally (Ekim and Hatibovic-Kofman, 2001). Becker and Karnei-R'em (1992), suggested that unilateral infraocclusion could cause adjacent teeth on the affected side to tilt around a centre of rotation, towards the infraoccluded teeth.

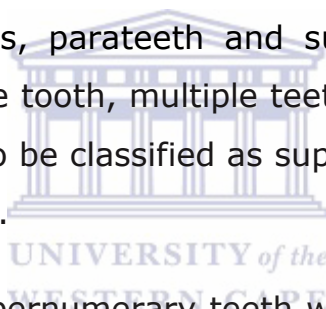
In addition, a shift in the midline towards the affected side occurs due to the crossing of the otherwise parallel transseptal fibres (Becker, 1992).

2.6.4 Supernumerary teeth

Not much research has been done on supernumerary teeth and the connection it may have with ectopic maxillary canines. Baccetti (1998a) found that supernumerary teeth did not have any association with palatally displaced maxillary canines.

Supernumerary teeth are defined as those in excess when compared to the normal series. They form as a result of excess dental lamina in the jaw. The tooth or teeth that develop may be morphologically normal or abnormal (Shah *et al.*, 2008).

Supernumerary teeth are also known as hyperdontia, distodens, mesiodens, peridens, parateeth and supplemental teeth. They may involve a single tooth, multiple teeth or the entire dentition. Microdonts may also be classified as supernumerary teeth (White and Pharoah, 2010).



The presence of supernumerary teeth within the dental arch can cause delayed eruption of teeth (Peedikayil, 2011; Mitchell and Bennett, 1992), crowding or spacing, displacement of adjacent teeth and ectopic eruption of teeth, which further leads to non-eruption of teeth.

A mesiodens can prevent eruption, delay eruption of permanent maxillary central incisors (Moraes *et al.*, 2004) or cause an ectopic eruption of a central incisor. Less frequently, a mesiodens can cause dilaceration or resorption of the permanent central incisor's root (Gardiner, 1961; Primosch, 1981; Russell and Folwarczna, 2003).

Occasionally, the distorted image of a supernumerary tooth lying outside the focal trough (i.e. in the hard palate) may be easily

missed, particularly in the anterior segment (Duterloo, 1991). On panoramic radiographs, they may appear normal, smaller in size compared to adjacent teeth or grossly deformed. Therefore, panoramic radiographs should be thoroughly assessed for supernumerary teeth (White and Pharoah, 2010).

2.6.5 Taurodontism

Nagpal *et al.* (2009) showed significant associations between taurodontism and palatally displaced canines (26.66%).

Taurodontism is defined as a change in the shape of the tooth, where the body of the tooth is enlarged, and the roots are reduced in size (Manjunatha and Kovvuru, 2010). Single or multiple teeth may be affected (White and Pharoah, 2010).

Normal teeth have been misdiagnosed as taurodonts, because of a subjective classification made from panoramic radiographs (Durr *et al.*, 1980), which relies purely on the experience and judgments of the examiner (Manjunatha and Kovvuru, 2010). The present study guarded against this subjective classification by recognizing the following measures suggested by Manjunatha and Kovvuru (2010):

1. The tooth assumes a rectangular shape rather than tapering towards the roots.
2. The pulp chamber is extremely elongated with a greater apico-occlusal height than normal.
3. The pulp chamber lacks the usual constriction at the cervical region.

The furcation of multirouted teeth is placed more apically and the dimensions of the crown are normal (Manjunatha and

Kovvuru, 2010). In 1977, Feichtinger and Rossiwall stated: “the distance from the bifurcation or trifurcation of the root to the cemento-enamel junction should be greater than the occluso-cervical distance for a taurodontic tooth.”

Taurodontism may occur in the permanent or primary dentition (Yordanova et al., 2011). It is often seen in molars and less frequently in premolars.

2.6.6 Dilaceration

Researchers have not previously studied the sequelae of dilaceration and the impact it could possibly have on the position of the permanent maxillary canines. As mentioned earlier in the guidance theory, the root of the maxillary lateral incisor plays a role in the final position of the permanent maxillary canine in the arch. Applying the role of guidance theory in the case of a dilacerated maxillary lateral incisor root, whether the permanent maxillary canine can be guided into an undesirable location or not is uncertain.

Dilaceration is a disturbance in tooth formation that produces a sharp bend in the tooth, anywhere in the crown or the root (White and Pharoah, 2010). The anomaly often occurs in maxillary incisors and one or more teeth may be affected (Goaz and White, 1982).

The cause of dilaceration is debatable. However, a strong association exists with trauma occurring in the primary dentition (Brin *et al.*, 1984). An impact to the primary roots at the time of trauma may cause displacement of the permanent successors (Andreasen, 1981). This is due to the close relationship between

the root of the primary tooth and crown of the permanent tooth (Andreasen and Ravn, 1971; Smith and Rapp, 1980).

Roots with mesial or distal dilaceration are distinctly visible on a radiograph. However, White and Pharoah (2010) suggested that if the roots are dilacerated buccally or lingually, the central radiographic beam passes parallel to the deflected part of the root producing a typical bull's eye appearance i.e. a circular or oval radiopaque area with a central radiolucency (the apical foramen and root canal).

2.6.7 Ectopic eruption of permanent first molars

Ectopic eruption of first permanent molar refers to first permanent molars which are hindered from complete eruption by the adjacent primary molar (Baccetti, 1998). On the panoramic radiograph, the permanent first molar is seen to have a strong mesial inclination and is located under the distal part of the second primary molar (McSherry, 1998). The distal surface of the primary molar is resorbed in this scenario (Kurol and Bjerklin, 1982; Kurol and Bjerklin, 1986; Mc Sherry, 1998). Self-correction can occur at 7 years of age (Kurol, 2002). The permanent molar may then either erupt into normal occlusion (Kurol and Bjerklin, 1982; Kurol and Bjerklin, 1986).

Bjerklin *et al.* (1992) suggested that there is a statistically significant association between ectopic first molars and ectopic maxillary canines.

An interesting long-term study by Becktor *et al.* (2005) showed that 23.3% of the 30 patients examined (chronological age 8-15 years), had ectopic eruption of the permanent first maxillary

molar and root resorption of the second primary molar. This took place prior to root resorption of the maxillary lateral incisors caused by ectopic maxillary canines. Hence, the ectopic first molars could possibly be used as an early risk factor for the prediction of maxillary canine ectopia (Becktor *et al.*, 2005).



Chapter 3

Materials and Methods

3.1 Null hypothesis

There is no association between potentially ectopic maxillary canines and other dental anomalies that can be detected using panoramic radiographs.

3.2 Study design

An analytical, descriptive, cross-sectional study was carried out to establish the prevalence of maxillary canine ectopia using random mixed dentition panoramic radiographs from the Paediatric Dentistry department.

3.3 Sample

After consulting with the statistician, a minimum sample size of 200 panoramic radiographs was decided upon. The panoramic radiographs were taken between 2011 and 2014. All mixed dentition panoramic radiographs of children between dental ages 8-12 years were used. The total sample size obtained was 574 mixed dentition panoramic radiographs.

3.3.1 Inclusion criteria

1. Patients with no previous history of orthodontic treatment.
2. Only good quality dental panoramic radiographs were used.
3. Only mixed dentition panoramic radiographs were used.

3.3.2 Exclusion criteria

1. Patients with cleft lip and palate.
2. Patients with syndromes.
3. Panoramic radiographs with only primary or only permanent dentitions.

3.4 Inter/intra-examiner variability

The primary researcher completed a pilot study using 20 panoramic radiographs. These were re-examined 2 weeks after the first examination to assess the reproducibility of diagnoses. A second examiner assessed the same 20 panoramic radiographs and where discrepancies existed, a consensus was reached after discussion.

Although the Kappa coefficient was initially calculated for the variable that showed occasional disagreement, the statistician felt that a sensitivity and specificity test was more appropriate for the purposes of analyzing the intra-examiner variability. A sensitivity test shows the percentage of patients with the anomaly, who are correctly identified as having the anomaly i.e. true positive. A specificity test shows the percentage of patients without the anomaly, who are correctly identified as not having the anomaly i.e. true negative.

Maxillary canine enlargement showed occasional disagreement. The sensitivity test for this anomaly resulted in a score of 1.00 (100%), suggesting that the researcher has identified all cases where patients had maxillary canine enlargement. The specificity test resulted in a score of 0.73, suggesting that the researcher

identified maxillary canine enlargement 27% of the time where the patient did not actually have maxillary canine enlargement.

Once similar readings were obtained, and no errors were found during the pilot study, the sample of 574 panoramic radiographs was evaluated in the same manner over a period of several weeks. The same sample of 574 radiographs was assessed a second time to ensure the primary researcher obtained accurate results. A second examiner selected a random sample from these panoramic radiographs to verify the results.

3.5 Data collection

The presence of potentially ectopic maxillary canines was assessed first. Secondary to these cases, various developmental anomalies were identified.

3.5.1 Radiographic markers for maxillary canine ectopia

1. Rotated permanent maxillary lateral incisors
2. Non-resorption of primary maxillary canine roots from dental age 10 and above
3. The degree of overlap of the permanent maxillary canine cusp tip in relation to the pulp chamber of the root of permanent maxillary lateral incisor was noted from dental age 10 and above i.e.
 - Distal to the pulp chamber
 - On the pulp chamber
 - Mesial to the pulp chamber
4. Angulation of permanent maxillary canines more than 30° to the mid-sagittal plane

5. Enlarged permanent maxillary and mandibular canines (comparison of right and left sides) was measured on the panoramic radiograph using a ruler after ensuring the permanent first molars (comparison of right and left sides) were not enlarged on the panoramic radiograph.

The presence and/or absence of the following developmental anomalies was also recorded:

- Congenitally missing teeth (excluding 3rd molars)
- Aplasia of premolars
- Peg-shaped permanent maxillary lateral incisors (where the incisal width was shorter than the cervical width)
- Infraocclusion of permanent first molars (diagnosed by a “step” in the occlusal plane)
- Supernumerary teeth
- Taurodontism
- Dilaceration
- Ectopic eruption of permanent first molars

The results obtained were coded accordingly (refer to Appendix A) and transferred to a Microsoft Excel spreadsheet.

3.6 Data processing and analysis

Pearson’s correlation coefficient was used to determine the degree to which two variables are associated. For a correlation coefficient to be statistically significant, its absolute value must exceed 0.0834. This indicates an association. The Chi-square test of independence and Fisher exact test were also used to determine whether two categorical variables are dependent or independent. A p-value of <0.05 indicates that the variables have a significant association.

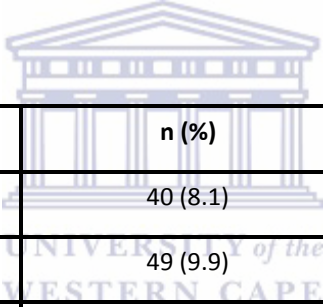
Chapter 4

Results

4.1 Prevalence of potentially ectopic maxillary canines

According to the selected markers identified in this study sample (dental age 8-12 years), the prevalence of potentially ectopic maxillary canines at Tygerberg Oral Health Centre is 85.9% (493/574).

Table 4.1.1: Dental age vs. the prevalence of potentially ectopic maxillary canines.



Dental Age	n (%)	Total n (%)
8	40 (8.1)	89 (18.1)
9	49 (9.9)	
10	211 (42.8)	404 (81.9)
11	133 (27)	
12	60 (12.2)	
	Total	493

Table 4.1.2: Prevalence of each radiographic marker for potentially ectopic maxillary canines (n=493).

Radiographic Markers	n (%)
Rotated maxillary lateral incisor	405 (82.2)
Non-resorption of maxillary primary canines	258 (52.3)
Overlap between the cusp tip of the permanent maxillary canine and the root of the permanent maxillary lateral incisor	103 (20.9)
Angulation of the permanent maxillary canine $\geq 30^{\circ}$ to the mid-sagittal plane	23 (4.7)
Maxillary Canine Enlargement	64 (13)
Mandibular Canine Enlargement	50 (10.1)

Table 4.1.3: Prevalence of each radiographic marker at various dental ages.

Dental Age	Total n	n (%)					
		Rotated Maxillary Lateral Incisors	Non-resorption of primary canines	Overlap	Angulated maxillary canines	Mx. Enlarged	Mnd. Enlarged
8	40	39 (97.5)	N	N	2 (5)	6 (15)	5 (12.5)
9	49	47 (95.9)	N	N	2 (4.1)	6 (12.2)	3 (6.1)
10	211	159 (75.3)	176 (83.4)	56 (26.5)	9 (4.3)	28 (13.2)	20 (9.5)
11	133	103 (77.4)	72 (54.1)	33 (24.8)	8 (6)	18 (13.5)	16 (12)
12	60	57 (95)	10 (16.7)	14 (23.3)	2 (3.3)	6 (10)	6 (10)
Total	493						

***N**= Normal observation at this age

4.2 Radiographic markers and their comparisons

Table 4.2.1: Occurrence of the other radiographic markers when the primary marker (grey block) already exists at dental age < 10 years (n=89).

n (%)					
Rotated maxillary lateral incisors	Non-resorption of primary canines	Overlap	Angulated maxillary canines	Mx. Enlarged	Mnd. Enlarged
86 (96.6)	N	N	4 (4.7)	9 (10.4)	7 (8.1)
N	0	N	N	N	N
N	N	0	N	N	N
4 (100)	N	N	4 (4.5)	0	0
9 (75)	N	N	0	12 (13.5)	6 (50)
7 (87.5)	N	N	0	6 (75)	8 (9)

***N**= Normal observation at this age

Interpretation: The primary marker is identified using a grey block and indicates the sample being tested. The various markers in the columns (secondary markers) are then compared to the grey block.

Table 4.2.2: Occurrence of the other radiographic markers when the primary marker (grey block) already exists at dental age ≥ 10 years (n=404).

n (%)					
Rotated maxillary lateral incisors	Non-resorption of primary canines	Overlap	Angulated maxillary canines	Mx. Enlarged	Mnd. Enlarged
319 (79)	183 (57.4)	84 (26.3)	13 (4.1)	37 (11.6)	26 (8.2)
183 (70.9)	258 (63.9)	67 (25.97)	17 (6.6)	25 (9.7)	24 (9.3)
84 (81.5)	67 (65)	103 (25.5)	13 (12.6)	16 (15.5)	10 (9.7)
13 (68.4)	17 (89.5)	13 (68.4)	19 (4.7)	0	0
37 (71.2)	25 (48.1)	16 (30.8)	0	52 (12.9)	25 (48.1)
26 (61.9)	24 (57.1)	10 (23.8)	0	25 (59.5)	42 (10.4)

Interpretation: Refer to the interpretation given under Table 4.2.1

Table 4.2.3: Dental age vs. simultaneous occurrence of rotated maxillary lateral incisors and non-resorption of primary maxillary canines.

Dental Age (n)	n (%)
10 (211)	126 (59.7)
11 (133)	48 (36.1)
12 (60)	9 (15)

Table 4.2.4: Extent of overlap of the maxillary canine cusp tip over the root of the maxillary lateral incisor at ≥ 10 years (Total n=404).

n (%)									
No Overlap	Distal to pulp chamber			On the pulp chamber			Mesial to pulp chamber		
	RHS	LHS	BOTH	RHS	LHS	BOTH	RHS	LHS	BOTH
301 (74.5)	32 (7.9)	25 (6.2)	14 (3.5)	12 (2.97)	7 (1.7)	2 (0.49)	5 (1.2)	5 (1.2)	1 (0.2)
Total n (%)	103 (25.5)								




Table 4.2.5: Extent of overlap when rotated maxillary lateral incisors and non-resorption of primary canines existed simultaneously at various dental ages.

Dental Age	Total n	No Overlap	n (%)								
			Distal			Pulp			Mesial		
			RHS	LHS	BOTH	RHS	LHS	BOTH	RHS	LHS	BOTH
10	126	91 (72.2)	10 (7.9)	4 (3.2)	7 (5.6)	7 (5.6)	2 (1.6)	1 (0.79)	1 (0.79)	2 (1.6)	1 (0.79)
11	48	33 (68.8)	6 (12.5)	4 (8.3)	2 (4.2)	0	1 (2.1)	1 (2.1)	1 (2.1)	0	0
12	9	7 (77.8)	1 (11.1)	1 (11.1)	0	0	0	0	0	0	0

Table 4.2.6: Prevalence of technical error on a panoramic radiograph in cases with maxillary/mandibular canine enlargement (n=493).

	Total n (%)
No Technical Error	95 (19.3)
Presence of Technical Error	398 (80.7)

Table 4.2.7: Maxillary lateral incisors that reached Nolla Stage 9 vs dental age.

Dental Age (n)	n (%)
8 (40)	0
9 (49)	0
10 (211)	151 (71.6)
11 (133)	125 (93.98)
12 (60)	57 (95)



4.3 Developmental Anomalies

In this study sample, the prevalence of the selected developmental anomalies occurring in all age groups with a potentially ectopic maxillary canine was 19.3% (n=95).

Table 4.3.1: Prevalence of developmental anomalies in potentially ectopic maxillary canines (n=493).

Developmental Anomalies	In Potentially Ectopic Maxillary Canine Cases n (%)
No Developmental Anomalies	398 (80.7)
Congenitally Missing Teeth	6 (1.2)
Aplasia of Premolars	12 (2.4)
Peg-Shaped Maxillary Lateral Incisors	7 (1.4)
Infraocclusion of Primary Molars	22 (4.5)
Supernumerary Teeth	32 (6.5)
Taurodontism	7 (1.4)
Dilaceration	17 (3.4)
Ectopic Molars	0

Table 4.3.2: Presence or absence of developmental anomalies vs selected radiographic markers.

Developmental Anomalies	n (%)					
	Rotated Laterals (n=405)	Non-resorption of primary canines (n=258)	Overlap (n=103)	Angulation (n=23)	Mx. Enlarged (n=64)	Mnd. Enlarged (n=50)
No Developmental Anomalies	333 (82)	209 (81)	80 (77.6)	18 (78)	51 (79.7)	43 (86)
Congenitally Missing Teeth	2 (0.5)	5 (1.9)	0	1 (4.3)	0	0
Aplasia of Premolars	10 (2.5)	7 (2.7)	2 (1.9)	0	2 (3.1)	0
Peg-Shaped Maxillary Lateral Incisors	3 (0.7)	5 (1.9)	2 (1.9)	0	2 (3.1)	1(2)
Infraocclusion of primary molars	17 (4.2)	14 (5.4)	3 (2.9)	1 (4.3)	3 (4.7)	1(2)
Supernumerary Teeth	24 (5.9)	16 (6.2)	9 (8.7)	2 (8.7)	5 (7.8)	3 (6)
Taurodontism	6 (1.5)	3 (1.2)	2 (1.9)	0	2 (3.1)	1(2)
Dilaceration	14 (3.5)	5 (1.9)	4 (3.8)	2 (8.7)	1 (1.6)	1(2)
Ectopic Molars	0	0	0	0	0	0

Chapter 5

Discussion of Results

5.1 Prevalence of potentially ectopic maxillary canines

The present study showed that 86% of the panoramic radiographs examined exhibited signs of potentially ectopic canines, according to the markers studied. The prevalence of potentially ectopic maxillary canines may not necessarily reflect the prevalence of actual maxillary canine ectopia in the general population. This high prevalence may be due to numerous limitations and other possible reasons, in that:

- All cases that presented with one or more of the prescribed radiographic markers were reported (Table 4.1.2). The diagnostic definition of these radiographic markers may have influenced the high prevalence. When recording the various markers, an error taking a measurement on a panoramic radiograph can either make the anomaly present or absent. This study did not clinically examine patients. This was a crucial limitation affecting the prevalence figure, as the absence of the maxillary canine bulge is the primary indication for ectopic maxillary canines (Fernandez *et al.*, 1998).
- In addition, the primary maxillary canine could not be clinically examined for mobility in identified cases of non-resorbed primary maxillary canines. More accurate readings may have been obtained for resorption of the primary maxillary canines if additional radiographs such as

periapical radiographs were used along with panoramic radiographs to detect them. This additional examination could have reduced the prevalence of non-resorbed primary maxillary canines.

- The examined panoramic radiographs were of patients, who presented at the Paediatric Dentistry Department of the Tygerberg Oral Health Centre. The fact that the Tygerberg Oral Health Centre is a referral institution may also have resulted in the higher prevalence figure.

Table 4.1.1 shows the distribution of potentially ectopic maxillary canines through various dental ages between 8-12 years. More than 80% of the potentially ectopic maxillary canines were present when dental age was 10 years and above. Potentially ectopic maxillary canines seem to become less prevalent from dental age 10 to 12. The maxillary canine should erupt into the arch at dental age 12 (Proffit *et al.*, 2007). Hence, the decrease in the number of potentially ectopic maxillary canine correlates with the normal eruption of the permanent maxillary canine. If this study had conducted a clinical examination of the maxillary canine buccal bulge at dental age 10 and found that the bulge was palpable, the study could have ruled out the possibility of maxillary canine ectopia and considered that case normal. This highlights that clinicians should be aware of how crucial it is to clinically examine the child and not only assess them radiographically.

Various researchers use different terms to describe the developmental status of the permanent maxillary canine i.e. ectopic, displaced, impacted. Each of these terms should be

carefully used as they have different definitions. This factor made it difficult to compare the present study to other studies. In this study, ectopic maxillary canine as such was not identified, rather this study used radiographic markers to predict potentially ectopic maxillary canines prior to the eruption of the permanent maxillary canine. Long-term follow up of the patients was not conducted, therefore this study could not determine whether the maxillary canine truly became ectopic.

When comparing this study to others, Ericson and Kuroi's (1986b) study recorded a prevalence of 1.7% for ectopic maxillary canines in 505 children between dental ages 8-12 years. The present study looked at the same age group. The authors recorded the maxillary canine's position in relation to the root of the maxillary lateral incisor and the dental arch (buccal, central, palatal or palatal tendency). They also studied the relationship between the relative position of the maxillary canine and the maturity of the maxillary canine. Unlike the present study, they could identify unerupted maxillary canines through clinical examinations as well as additional radiographs, like tomography and periapical radiographs. Moreover, a long-term follow-up study (2.5 to 3 years) was conducted, enabling them to assess the final eruption status of the maxillary canines.

Thilander and Jakobsson (1968) examined dental casts and radiographs. They recorded a prevalence of 37% for unerupted maxillary canines at the initial examination (mean chronological age of 11.5 years). In the present study, the prevalence of potentially ectopic maxillary canines at dental age 12 was 12% (Table 4.1.1). Differences in values may be because Thilander and Jakobsson (1968) did not use all the radiographic markers

that were noted in the present study but more importantly, the present study used dental age and not chronological age. Studies have shown that dental age can have a difference of roughly 4 to 5 years from the actual chronological age (Hurme, 1949; Taranger, 1976). Davidson and Rodd (2001) found that the difference between dental age and chronological age was most evident in 8 to 12-year-old children. For children above 9.5 years, the dental age estimates were within +/-2 years of the chronological age (Nykanen *et al.*, 1998).

Thilander and Jakobsson (1968) also recorded an enlarged follicular space, the position of the unerupted canine (buccal or palatal), non-resorption of primary canines and relative spacing. The present study shared one marker (non-resorption of primary maxillary canines) in common with the study of Thilander and Jakobsson (1968). If only the shared marker was considered, the prevalence of potentially ectopic maxillary canines in the present study would be 16.7% at dental age 12 years (Table 4.1.3) compared to Thilander and Jakobsson (1968) who recorded non-resorption of primary maxillary canines as 67% (chronological age 12 years).

5.1.1 Limitations

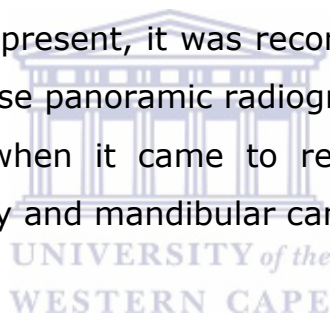
Apart from the limitations that influenced the high prevalence of potentially ectopic maxillary canines, additional limitations of this study include:

1. Chronological age was not recorded and therefore, could not be compared with dental age.
2. Gender and ethnicity of the child was not recorded.

3. Space analysis of the dental arches was not performed to identify if crowding or spacing had a role in the outcome of the results.

4. The technique of taking the panoramic radiographs was not standardised. A single technician did not take the radiographs and rather the radiographs were obtained from the existing records of the Paediatric Department.

5. Maxillary and mandibular canine enlargement (which denotes the palatal/lingual displacement of the canine) were the only readings that could have been affected by technical errors of the panoramic radiograph. For these two radiographic markers, if a technical error was present, it was recorded in the results with a 'T' where, $T=0$. These panoramic radiographs were only removed from the sample when it came to recording the size of the permanent maxillary and mandibular canines.



Nineteen percent of the panoramic radiographs in this study were free of technical errors (Table 4.2.6). Schiff *et al.* (1986), studied the technical errors in panoramic radiographs and found that only 20% of the films were error free. The technical error can occur due to improper positioning of the patient through the midsagittal plane. When the midsagittal plane of the head is not centered, the first molars are unequally magnified. The image farthest from the film is magnified (Langland *et al.*, 1989).

6. A follow-up study was not conducted. This study could therefore not determine the actual number of potentially ectopic maxillary canines that erupted into their normal position in the arch.

5.2 Radiographic Markers

The present study looked at six markers as possible indicators of potential canine ectopia (Table 4.1.2). Of the 493 potentially ectopic maxillary canine cases, only two cases recorded 5 markers (all except angulation) occurring simultaneously. One case occurred at dental age 10 and the other case occurred at dental age 11.

5.2.1 Rotated maxillary lateral incisors

Rotation of the maxillary lateral incisors recorded from a panoramic radiograph can only become a reliable clinical marker if it can be accurately diagnosed. Noting the morphology from a panoramic radiograph becomes subjective, especially when minor deviations to the normal morphology exist as in the case of maxillary lateral incisors. Since no clinical examinations were conducted in this study to provide additional insight as to whether the rotation existed clinically, the accuracy of this marker to predict maxillary canine ectopia becomes questionable. No other studies have examined the prevalence of rotated maxillary lateral incisors with respect to ectopic maxillary canines and hence the findings of this study could not be compared.

Rotated maxillary lateral incisors was the most commonly found radiographic marker compared to the other radiographic markers within the entire sample (Table 4.1.2). The diagnostic criteria for recognizing rotated lateral incisors was strict, in that it considered all rotations that deviated from the normal radiological morphology of the maxillary lateral incisors (as described in section 2.5.1).

At dental age 9, rotated maxillary lateral incisors occurred 96% of the time (Table 4.1.3). This finding is linked to the ugly duckling stage, where the maxillary canine is up-righting and bringing about the tipping of the permanent maxillary lateral incisors (Broadbent, 1937). This tipping could translate to prominent rotation of the maxillary lateral incisors in cases of severe crowding.

Unlike Proffit *et al.* (2007) who used dental age only, Broadbent used a combination of chronological age and recorded the dental age of the child using Bolton's standard of calcification. Broadbent (1937) stated that the shedding of the primary incisors and the eruption of their successors (6 years) marks the beginning of the ugly duckling stages, which reaches its maximum at about 10 years (Broadbent, 1941). During dental age 9, the general practitioners can monitor the amount of tipping of the rotated maxillary lateral incisor. At this age, if the tipping is prominent enough to cause rotation of the maxillary lateral incisors, practitioners can be positive of an ectopically erupting maxillary canine.

Furthermore, Shapira and Kuftinec (1998) suggested that palatally displaced canines could cause distal tipping of the maxillary lateral incisors and even cause rotation. According to Nagpal *et al.* (2009), any rotation of the maxillary lateral incisor would guide the permanent maxillary canine more labially or palatally, depending on the direction of rotation. This is linked to the guidance theory (mentioned in section 2.1). Hence, if the maxillary lateral incisor is itself abnormally positioned or rotated, the maxillary canine will follow this abnormal path and will be displaced in the same direction of the rotation. Non-resorption of

the primary maxillary canines, supernumerary teeth (Winzar, 1967) and aplasia of premolars have also been reported as a cause for rotation of the maxillary lateral incisors (Baccetti, 1998). These three anomalies cause arch-length discrepancies. Vermeulen *et al.* (2012) suggested that rotated maxillary lateral incisors can occur in crowded situations or in a spaced arch.

When dental age was 10 years and above, non-resorption of primary maxillary canines occurred approximately 57% of the time when rotated maxillary lateral incisors was the primary marker. Rotated maxillary lateral incisors occurred more than 70% of the time when non-resorption of the primary canines was the primary marker (Table 4.2.2). This suggests that when the primary maxillary canine has not begun resorbing past dental age 10, it causes crowding of the upper arch. This in turn brings about the rotation of the maxillary lateral incisors. When further tested, rotated maxillary lateral incisors showed no statistically significant relationship with non-resorption of primary canines (p-value of 0.86). No other studies conducted a similar examination of these two markers so a comparison could not be drawn.

Table 4.2.3 shows the exact distribution of this combination within various dental age groups. Although this is not a long-term study of one patient, this combination of rotated maxillary lateral incisors and non-resorption of primary maxillary canines decreased roughly by half as it moved from one dental age group to the next. This finding probably relates to the eruption of the maxillary canine where, at dental age 10 the temporarily rotated lateral incisors and non-resorption of the primary maxillary canine may be due to the maxillary canine movements

during the 'Ugly duckling stage'. At dental age 12, this self-corrected along with the active eruption of the permanent maxillary canine into the arch.

When dental age was 10 years and above, overlap (all types) occurred 26% of the time when rotated lateral incisors was the primary marker and more than 80% cases had rotated maxillary lateral incisors when overlap (all types) was the primary marker (Table 4.2.2).

Rotated maxillary lateral incisors showed a statistically significant association with distal overlap when dental age was 10 years and above (p-value of < 0.005) but it failed to show a statistically significant association with overlap over the pulp chamber and mesially overlapping cases (p-values of > 0.05). When a rotated maxillary lateral incisor existed, the probability test showed that the maxillary canine cusp tip would be positioned distal to the root of the maxillary lateral incisor 16.5% of the time. The test further showed that when a distal overlap existed, rotation of the maxillary lateral incisors occurred 83.9% of the time. This finding suggests that ectopic maxillary canines that are overlapping the root of the maxillary lateral incisor are more likely to cause the rotation of the maxillary lateral incisor. Clinicians should be aware of the high probability of the rotation of the maxillary lateral incisors occurring when distal overlap exists. Hence if rotation of the maxillary lateral incisors already exists by dental age 9, clinicians can take timeous interceptive measures and explore the possibility of ectopia by monitoring the progress of the maxillary canines.

In both dental age groups, more than 4% of the cases had angulated maxillary canines greater than 30° when rotated

maxillary lateral incisors was the primary marker (Table 4.2.1 and 4.2.2 respectively). All cases with angulated maxillary canines greater than 30° exhibited rotated maxillary lateral incisors when dental age was less than 10 years but only approximately 70% had rotated maxillary lateral incisors when dental age was 10 years and above (Table 4.2.1 and 4.2.2 respectively).

No statistically significant relationship (p-value of 0.72) was found between rotated maxillary lateral incisors and angulation greater than 30° of the maxillary canines. Other researchers have not studied the relationship of angulation of the maxillary canine and rotated maxillary lateral incisors so this study could not be compared. However, this study suggests that a maxillary canine with an angulation greater than 30° on its own is less likely to cause a rotation of the maxillary lateral incisor. Nonetheless the chance of rotation occurring increases, if the permanent maxillary canine both overlaps the root of the maxillary lateral incisor and had an angulation of greater than 30° . Further studies may be needed to understand the connection between these radiographic markers.

Maxillary canine enlargement occurred in approximately 10% of the cases in both dental age groups when rotated maxillary lateral incisors was the primary marker (Tables 4.2.1 and 4.2.2 respectively). Rotated maxillary lateral incisors showed no statistically significant relationship with maxillary canine enlargement (p-value of > 0.05). No other research has examined the relationship between these two markers. Hence, the current study could not be compared. Further studies may be

required to understand the association between these two radiographic markers.

In both dental age groups, mandibular canine enlargement occurred approximately 8% of the time when rotated maxillary lateral incisors existed as the primary marker. When dental age was less than 10 years, rotated maxillary lateral incisors occurred 88% of the time when mandibular canine enlargement existed as the primary marker and around 60% of the time when dental age was 10 years and above (Tables 4.2.1 and 4.2.2 respectively).

Rotated maxillary lateral incisors showed no statistically significant relationships with mandibular canine enlargement (p-value of > 0.05). No other studies have examined the relationship between these two markers for this study to compare its findings. However, this study suggests that mandibular canine ectopia in conjunction with a rotated maxillary lateral incisor could possibly indicate an underlying ectopic maxillary canine. Clinicians failing to palpate the buccal canine bulge and identifying both these markers on the panoramic radiograph as early as dental age 9, can be aware of the likelihood of an ectopic maxillary canine.

During a discussion with the supervisors of this study, they suggested that a distolabial rotation of the maxillary lateral incisor could possibly mean that the permanent maxillary canine was palatally displaced and a mesial rotation of the maxillary lateral incisor could probably mean that the permanent maxillary canine was labially placed. This could not be determined by the current study. Future studies are encouraged to look at the direction of the rotation of maxillary lateral incisors and its

possible association with palatal or labial maxillary canine ectopia.

Summary

Presence of Potentially Ectopic Maxillary Canine	
When Dental Age < 10	<ul style="list-style-type: none"> • If the mandibular canine is lingually placed and the maxillary lateral incisors are rotated. • If the maxillary canine has an angulation greater than 30⁰ along with overlap.
When Dental Age ≥ 10	<ul style="list-style-type: none"> • Resorption of the primary canine has not begun. No mobility of the primary canine. • Buccal canine bulge is not palpable and the maxillary lateral incisors are rotated.

5.2.2 Non-resorption of primary maxillary canines

The non-resorption of primary maxillary canine roots was the second most prominent radiographic marker after rotated maxillary lateral incisors (Table 4.1.2). As mentioned earlier in section 5.1, Thilander and Jakobsson (1968) recorded the prevalence of non-resorbed primary maxillary canines but only at the chronological age of 12 years.

The presence of a non-resorbed primary maxillary canine prior to dental age 10 is normal according to Duterloo (1991). Therefore, it was recorded as a normal observation in the results when dental age was less than 10 years (Table 4.1.3). Whenever non-resorption of the primary canines was being tested either as the primary marker or as the secondary marker, it was marked as a normal observation (with a 'N') even though it may have been

present on the panoramic radiograph (Table 4.2.1).

A high number of cases of non-resorption of primary canines at dental age 10 have been noted (Table 4.1.3). Proffit *et al.* (2007) and Duterloo (1991) suggested that resorption of the apical third of the root of the primary maxillary canines should have taken place at dental age 10. Since this is not evident from the results obtained from the current study, it suggests one of two conclusions i.e. 1) a potentially ectopic maxillary canine is present and has not resorbed the root of the primary canine or, 2) the minor resorption of the primary maxillary canine was not clearly visible from the panoramic radiograph contributing to the high prevalence of non-resorbed primary maxillary canines.

Between dental age groups 10-12 years, there is a decline in the prevalence of non-resorbed primary canines. As the permanent maxillary canine actively erupts during dental age 10-12, the resorption of the root of the primary maxillary canine should occur at the same time. Duterloo (1991) also stated that resorption of the primary maxillary canine should take place at this age. Therefore, it is normal to find a decline in the number of non-resorbed primary maxillary canines from dental age 10 to 12 years.

In addition, the present study recorded no resorption of the permanent maxillary central incisors or maxillary lateral incisors in the presence of potentially ectopic maxillary canines. This is contrary to studies by Arens (1995), Algerban *et al.*'s (2009) and Sameshima and Sinclair's (2001), which found that central incisor root resorption occurs in the presence of maxillary canine ectopia. A computed tomography study conducted by Ericson and Kurol (2000) found that 48% of the permanent maxillary

incisors showed resorption in children between 9 and 15 years of age presenting with ectopic maxillary canines (38% in maxillary lateral incisors and 9% in central incisors). Among the resorbed lateral incisors, 31% had slight resorption, 9% had moderate resorption and severe resorption with pulpal involvement was evident in 60% of cases. In the case of resorbed central incisors, 36% had slight resorption, 21% had moderate resorption and 43% had severe resorption with pulpal involvement. About 60% of the resorptions involved the middle and apical thirds (tip of the apex not included). Resorptions of the maxillary incisors can be found as early as 10 years of age but occurs most often between 11-12 years (Ericson and Kuroi, 1987b).

The fundamental problem is that root resorption is difficult to see on a panoramic radiograph as it is two-dimensional and root resorption in the 3rd dimension cannot be identified (Mason *et al.*, 2001). Standard radiographic techniques tend to detect more advanced stages of resorption rather than the early palatal or labial resorption (Rimes *et al.*, 1997). It is also difficult to detect root resorption on panoramic radiographs because of the overlapping of the permanent maxillary canine crown over the root of the maxillary central incisors, maxillary lateral incisors (Falahat *et al.*, 2008) or primary maxillary canines. No supplementary clinical examinations were done to check for the buccal canine bulges, the mobility of the maxillary incisors, lateral incisors or the primary maxillary canines and no additional periapical radiographs were taken to evaluate this further. The results of the present study may thus not be completely accurate.

When the dental age was 10 years and above, 26% of the cases had overlap (all types) when non-resorbed primary maxillary canines was the primary marker and 65% had non-resorption of primary canines where overlap (all types) was the primary marker (Table 4.2.2).

Non-resorption of the primary maxillary canines showed a statistically significant association with distal overlap (p-value of < 0.001) and overlap over the pulp chamber (p-value of 0.003). After conducting a probability test, non-resorption of the primary canines showed that it was more likely to occur when a distal overlap (63% chance), or an overlap over the pulp chamber of the root of the maxillary lateral incisor existed (76% chance). The probability test further found that when non-resorption of the primary canine existed, there was 19.8% chance for distal overlap or only a 6% chance for overlap over the pulp chamber to occur. The above findings suggest that non-resorption of the primary canines is more a consequence of potentially ectopic maxillary canine rather than a cause.

Shapira and Kuftinec (1998) and Lappin (1951) suggested that non-resorbed primary maxillary canines caused maxillary canine ectopia as it was an obstacle in the path of eruption of the maxillary canine. On the contrary, Thilander and Jakobsson (1968) and Ericson *et al.* (2002), stated that the primary maxillary canine was a consequence of maxillary canine ectopia. Thilander and Jakobsson's (1968) study showed the presence of non-resorbed primary maxillary canines at the first examination (mean age 11.5 years), but fewer cases were recorded by the third examination (mean age 12.9 years). In these cases, they also found that 67.6% of the maxillary canines had erupted.

Ericson *et al.*'s (2002) study can be used to support Thilander and Jakobsson's (1968) findings as they said the eruptive forces and the cellular changes during active eruption of the maxillary canines brings about the resorption of the primary maxillary canines.

However, non-resorption of primary canines did not show a statistically significant association with mesial overlap (p-value of 0.21) when dental age was 10 years and above. This may have resulted due to the dental age at which mesial overlap is being identified. If non-resorption of primary canines and mesial overlap were studied in an older age group, the results may have been different. Mesial overlap is perhaps an extreme situation at dental ages 8-12 years but this needs to be further investigated.

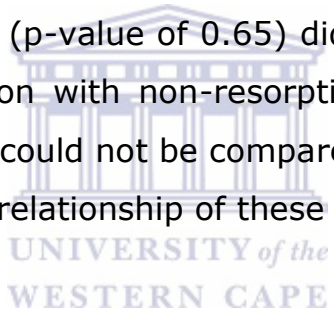
When dental age was 10 years and above, 7% of the cases had angulated maxillary canines greater than 30° when non-resorption of the primary maxillary canine was the primary marker. Ninety percent of the cases had non-resorption of primary canines when angulated maxillary canines greater than 30° was the primary marker (Table 4.2.2).

Non-resorption of primary maxillary canines showed a statistically significant association with angulated maxillary canines greater than 30° (p-value of 0.004). The probability test showed that non-resorption of the primary canines was more likely to occur when the maxillary canines had an angulation greater than 30° (74% chance). The probability test further showed that when non-resorption of the primary canine exists, there was only a 7% chance for the angulation of the maxillary canines to be greater than 30° . This is an additional result that suggests that non-resorption of the primary maxillary canines is

caused by an ectopically erupting maxillary canine and is not a cause of it.

When dental age was 10 years and above, both maxillary canine enlargement and mandibular canine enlargement were identified in approximately 9% of cases when non-resorbed primary maxillary canine was the primary marker (Table 4.2.2). Non-resorbed primary maxillary canines occurred 48% of the time when maxillary canine enlargement was the primary marker and approximately 60% of the time when enlarged mandibular canine was the primary marker (Table 4.2.2).

Maxillary canine enlargement (p-value of 0.32) and mandibular canine enlargement (p-value of 0.65) did not show a statistically significant association with non-resorption of primary maxillary canines. This result could not be compared since no other studies have examined the relationship of these anomalies.



Summary

Presence of Potentially Ectopic Maxillary Canine	
When Dental Age < 10	<ul style="list-style-type: none"> • If the mandibular canine was lingually displaced, then it was less likely that the primary maxillary canine would resorb at a later stage
When Dental Age ≥ 10	<ul style="list-style-type: none"> • If resorption of the primary canine has not begun and no mobility of primary maxillary canine is found on clinical examination. • Radiograph shows distal or pulpal overlap of the maxillary canine cusp tip over the root of the maxillary lateral incisor. Mesial overlap may be seen in extreme cases or after dental age 12. • When non-resorbed primary canines exist, angulation of the maxillary canine is highly likely to be greater than 30°.

5.2.3 Degree of overlap of the permanent maxillary canine cusp tip and maxillary lateral incisor root

According to Fernandez *et al.* (1998), any overlap of the permanent maxillary canine is to be considered normal prior to the permanent maxillary lateral incisor reaching Nolla Stage 9. To accommodate for this, the prevalence of overlap of the maxillary canine cusp tip over the root of the maxillary lateral incisor was recorded as normal prior to dental age 10 years (Table 4.1.3). Whenever overlap was tested as either a primary or secondary marker, it was recorded as a normal observation (with a 'N') even though it may have been present on the panoramic radiograph (Table 4.2.1).

Table 4.2.7 shows the dental age distribution of the maxillary lateral incisor at Nolla Stage 9. One should expect all the maxillary lateral incisors to have full developed by dental age 12. In three cases at dental age 12, the maxillary lateral incisors did not reach Nolla stage 9 but were close to reaching this stage. The primary researcher of this study may have made an error when recording the dental age. Therefore, this study disregards the possible role of delayed development in these three cases.

Approximately 20% of the potentially ectopic maxillary canine cases showed overlap (all types) (Table 4.1.2) and the prevalence in various age groups is shown in Table 4.1.3. Chalakal *et al.* (2011) found a prevalence of 73% for overlap (all types). Differences were seen due to variations in criteria when selecting the sample. Chalakal *et al.* (2011) used children between the chronological ages of 10-12 years. The authors also

clinically examined cases where only cases with unilateral palpable maxillary canine bulges were included in the study. This increased the accuracy of their results.

Of the potentially ectopic maxillary canines in this study, 75% showed no overlap when dental age was 10 years and above (Table 4.2.4). In this study, only 2.6% of the potentially ectopic maxillary canines mesially overlapped the root of the maxillary lateral incisor when dental age was 10 years and above (Table 4.2.4). Chalakkal *et al.* (2011) found that 30% of the maxillary canines were positioned mesial to the root of the maxillary lateral incisors between chronological ages 10-12 years. The reasons for the difference have already been mentioned earlier.

Warford *et al.* (2003) found that degree of overlap was a significant predictor of maxillary canine impaction compared to angulation of the maxillary canine. This was only possible because they had the impaction status of the maxillary canines, allowing them to run a logistic regression test between the two predictive markers. Since this study could not determine the impaction status of the maxillary canines, their statement could not be verified. However, as the severity of overlap increased, potentially ectopic maxillary canines became less prevalent (Table 4.2.4). This suggests that an absence of the buccal canine bulge upon clinical examination (dental age \geq 10 years) and identifying the degree of overlap on the panoramic radiograph could act as a good predictor of ectopic maxillary canines.

In this study, when rotated maxillary lateral incisors and non-resorption of primary canines occurred together, 28% cases displayed overlap at dental age 10 (Table 4.2.5). In addition, approximately 31% cases displayed overlap at dental age 11 and

22% cases displayed overlap at dental age 12 (Table 4.2.5). In all these cases (dental ages 10-12 years), the maxillary canine cusp tip lay on the distal aspect of the root of the maxillary lateral incisor and it occurred on the right-hand side (Table 4.2.5). No other studies have examined the relationship among these three radiographic markers to draw a comparison. When the buccal canine bulge cannot be palpated in a child between dental age 10-12 years and the primary maxillary canines are not mobile, clinicians should take a panoramic radiograph. If the three radiographic markers are present, this could indicate potential maxillary canine ectopia.

When dental age was 10 years and above, angulated maxillary canines greater than 30° was recorded approximately 13% of the time when overlap (all types) was the primary marker (Table 4.2.2). When maxillary canines with an angulation greater than 30° was the primary marker, approximately 70% had overlap (all types) when dental age was 10 years and above (Table 4.2.2).

When dental age was 10 years and above, a statistically significant association was found between angulated maxillary canines greater than 30° and distal overlap (p-value of < 0.001). The result of the probability test showed that angulated maxillary canines greater than 30° were more likely (39% chance) to cause the maxillary canine cusp tip to be positioned distal to the root of the maxillary lateral incisor. When there is an existing distal overlap, angulation of the maxillary canine was less likely to become greater than 30° (11% chance).

In addition, when dental age was 10 years and above, angulation greater than 30° of the maxillary canine showed a statistically significant association with overlap over the pulp chamber of the

maxillary lateral incisor root (p-value of 0.014). When the maxillary canines had an angulation greater than 30° , the probability test showed that there was a 13% chance for the maxillary canine cusp tip to overlap the pulp chamber of the root of the maxillary lateral incisor. The test further showed that when an overlap exists over the pulp chamber, the probability for the maxillary canines to have an angulation greater than 30° was 14%.

When dental age was 10 years and above, a statistically significant association (p-value of 0.015) was also found between angulated maxillary canines greater than 30° and mesial overlap. When the maxillary canine had an angulation greater than 30° , the probability test found that there was a small chance (8.7%) for the maxillary canine cusp tip to be positioned mesial to the maxillary lateral incisor root. The probability of the maxillary canine to have an angulation greater than 30° doubled to 18% when a mesial overlap existed. This result suggests that once the maxillary canine has mesially overlapped the root of the maxillary lateral incisor there is a greater chance for the maxillary canine to be angulated greater than 30° .

Although angulation showed a statistically significant association with overlap (all types), the statistical results above suggest that the marker did not add significantly to the prediction of ectopic maxillary canine when compared to overlap as a marker. Most of the maxillary canines positioned over the pulp chamber or mesial to the root of the maxillary lateral incisor will become impacted. Hence, the small increase that angle contributes is not clinically significant. Only for the maxillary canines positioned distal to the

root of the maxillary lateral incisor would angulation have potential significance in predicting impaction, confirming the work of Warford *et al.* (2003).

When dental age was 10 years and above, maxillary canine enlargement occurred 16% of the time when overlap (all types) was the primary marker and overlap (all types) occurred 31% of the time when maxillary canine enlargement was the primary marker (Table 4.2.2). Maxillary canine enlargement resulted in no statistically significant association with distal overlap (p-value of 0.21), overlap over the pulp chamber (p-value of 0.64), and/or mesial overlap (p-value of 0.45). Other studies are yet to examine the relationship between these two radiographic markers. This study however, suggests that when the maxillary canine is palatally displaced and the maxillary canine bulge is not palpable by dental age 10, the maxillary canine is likely to overlap the root of the adjacent maxillary lateral incisor to some extent. As the dental age of the patient increases, the extent of the overlap may worsen. Therefore, if clinicians spot an enlarged maxillary canine on the panoramic radiograph after confirming no change in the size of the permanent first molars, they should be aware of the likelihood of a developing ectopic maxillary canine.

When dental age was 10 years and above, overlap (all types) occurred approximately 20% of the time when enlarged mandibular canines was the primary marker and mandibular canine enlargement was recorded 10% of the time when overlap (all types) was the primary marker (Table 4.2.2).

Mandibular canine enlargement did not show a statistically significant association with distal overlap or overlap over the

pulp chamber of the root of the maxillary lateral incisor (p-values were > 0.05). However, mandibular canine enlargement showed a statistically significant association with the mesial overlap of the maxillary canine cusp tip over the root of the maxillary lateral incisor (p-value of 0.027). When a mandibular canine is lingually displaced, the probability test showed that there is only a 6% chance that the maxillary canine cusp tip would be positioned mesial to the root of the maxillary lateral incisor. It was more likely (27%) for the mandibular canine to become lingually displaced when the maxillary canine was positioned mesial to the maxillary lateral incisor root. This result suggests that if there is an ectopically positioned maxillary canine there is a chance that an ectopic mandibular canine also exists.

Clinicians who spot an enlarged mandibular canine on a panoramic radiograph i.e. a lingually displaced mandibular canine, can be aware of the possibility for the maxillary canine to also become ectopic. Since mandibular canines develop earlier than the maxillary canines, clinicians can take timeous interceptive measures if need be. Further investigations may be needed to reveal a clear link between mandibular canine ectopia and maxillary canine ectopia.

Summary

Presence of Potentially Ectopic Maxillary Canine	
When Dental Age < 10	<ul style="list-style-type: none"> • If the mandibular canine is lingually placed there is a chance that the maxillary canine cusp tip will overlap the root of the adjacent lateral incisor at a later stage.
When Dental Age ≥ 10	<ul style="list-style-type: none"> • If on clinical examination the buccal canine bulge is not palpable, rotated maxillary lateral incisors exist, and there is no mobility of the primary canines. • Radiographically, the primary canines have not begun resorbing and the maxillary canine overlaps the adjacent lateral incisor.

5.2.4 Angulation of the maxillary canines

According to Table 4.1.2, 5% of the maxillary canines had an angulation greater than 30° maxillary canines. In this study, the prevalence of angulated maxillary canines was similar through the various dental ages (Table 4.1.3). This may be due to the low prevalence of this marker in the current sample. Fleming *et al.* (2009) found a prevalence of 52% for maxillary canines with an angulation greater than 30°. The reason for the difference in prevalence was because Fleming *et al.* (2009) used patients with a mean age of 14.8 years, who had one or more palatally displaced canines. By the age of 14 years, these palatally displaced maxillary canines were considered to be impacted and so these teeth tend to keep moving in the wrong direction.

Warford *et al.* (2003), studied unerupted canines of children with a chronological age of less than 12 years. He recorded the

degree of angulation in the various sectors I- IV (mentioned in the literature review section 2.4.3) and determined the probability of unerupted canines based on sector and angulation measurements. Only in sector II would angulation have potential significance in predicting impaction. The results of this study could not be compared to Warford *et al.*'s study (2003) since no clinical examinations were conducted to find the impaction status of the maxillary canines.

Of the angulated maxillary canines between dental ages 8-12 years, zero cases exhibited maxillary canine enlargement and mandibular canine enlargement (Tables 4.2.1 and 4.2.2 respectively). This may have been due to the low prevalence of the angulation marker within the current sample. No statistically significant associations were found between angulation and maxillary canine enlargement/ mandibular canine enlargement (p-values of 0.08 and 0.13 respectively). No other research has studied the connection between angulation and maxillary canine enlargement or mandibular canine enlargement. However, this study suggests that a larger sample may show new links between these radiographic markers.

5.2.5 Maxillary and mandibular canine enlargement

As mentioned previously in Chapter 3, the intra-examiner variability during the assessment of enlarged maxillary canines showed occasional disagreement. However, this can be expected considering that the size of the permanent maxillary canine can vary depending on where the permanent maxillary canine was positioned within the alveolar ridge at the time the radiograph

was taken. In addition, the magnification factor at the time of taking the radiograph could possibly have also played a role.

Thirteen percent of the potentially ectopic canines had maxillary canine enlargement (Table 4.1.2). The prevalence of maxillary canine enlargement was highest at dental age 8 (Table 4.1.3). This finding can be considered normal as it may have occurred due to the initial position of the maxillary canine high in the maxilla above the root of the maxillary lateral incisor (Moss, 1972) causing it to be magnified on the panoramic radiograph. Other studies have not noted the prevalence of maxillary canine enlargement but have noted palatally displaced maxillary canines.

Of the potentially ectopic cases, mandibular canine enlargement occurred in 10% of the cases (Table 4.1.2). Other studies have not noted the prevalence of mandibular canine enlargements.

In both dental age groups, mandibular canine enlargement occurred in approximately 50% of the cases were enlarged maxillary canines existed as the primary marker (Tables 4.2.1 and 4.2.2 respectively). When dental age was less than 10 years, maxillary canine enlargement occurred in 75% cases were mandibular canine enlargement existed as the primary marker and this was roughly 60% when dental age was 10 years and above (Tables 4.2.1 and 4.2.2 respectively).

Maxillary canine enlargement demonstrated a statistically significant relationship with mandibular canine enlargement (p-value of <0.00001). After conducting a probability test, maxillary canine enlargement was more likely (62%) to occur when mandibular canine enlargement existed. When maxillary canine

enlargement existed, there was only a 48% chance that mandibular canine enlargement also occurred. Maxillary canine enlargement on the panoramic radiograph denotes the palatal displacement of the maxillary canine (Hudson *et al.*, 2009; Mason *et al.*, 2001 and Duterloo, 1991). This study suggests that when mandibular canine ectopia occurs, maxillary canine ectopia has a greater chance of occurring concurrently.

As the mandibular canines develop earlier than the maxillary canines (Nelson and Ash, 2010), mandibular canine enlargement can perhaps then act as a predictor of the developing maxillary canine ectopia.

Summary

Presence of Potentially Ectopic Maxillary Canine	
When Dental Age < 10	<ul style="list-style-type: none"> • If the mandibular canine is lingually placed it is highly likely to find a palatally displaced maxillary canine.
When Dental Age ≥ 10	<ul style="list-style-type: none"> • On clinical examination, the buccal canine bulge is not palpable and the mandibular canine is lingually placed. • Radiographically, the maxillary canine is enlarged suggesting that it is palatally placed.

5.3 Developmental anomalies as predictors of ectopic maxillary canines

In the present study, 19% of potentially ectopic maxillary canines occurred with developmental anomalies (Table 4.3.1).

The low prevalence of developmental anomalies in the present study may be due to the genetic factors governing these various anomalies i.e. ethnicity/hereditary factors. Sorenson *et al.* (2009) stated that maxillary canine ectopia may also occur in dentitions without any dental deviations. Ooshima *et al.* (1996) and Baccetti (1998a) suggested that studying one anomaly could predict another. The reciprocal associations found by Baccetti (1998a) was not seen in the present study. He found reciprocal associations between aplasia of premolars, peg-shaped lateral incisors and infraocclusion of primary molars.

5.3.1 Congenitally missing teeth

In this study, 6 potentially ectopic maxillary canine cases had congenitally missing teeth (Table 4.3.1). Congenitally missing teeth (in general) occurred in 5 cases with non-resorption of the primary maxillary canines. However, they did not occur with overlap (all types) and maxillary/ mandibular canine enlargement (Table 4.3.2).

This study found six cases (1%) with congenitally missing maxillary lateral incisors in the presence of potentially ectopic maxillary canines. Brin *et al.* (1986) and Becker *et al.* (1981) found 5.5% of congenitally missing maxillary lateral incisors occurring with palatally displaced maxillary canines. Of the six cases that had congenitally missing maxillary lateral incisors, 5 cases also had non-resorption of the primary maxillary canines. Nanda (1983) suggested that non-resorbed primary canines were likely to occur when there is a congenitally missing lateral incisor.

No statistically significant associations were found between

congenitally missing lateral incisors and each of the radiographic markers separately (p-values were all > 0.05). Peck *et al.* (1996) found no statistical significance in the frequency of missing maxillary lateral incisors in association with palatally displaced maxillary canines. However, several authors have previously noted that absence of maxillary lateral incisors occurred frequently among cases with palatally displaced canines (Miller, 1963; Bass, 1967). The authors emphasized Broadbent's original 1941 observation where, the absence of a maxillary lateral incisor deprives the erupting permanent maxillary canine of the normal guidance provided by the root of the maxillary lateral incisor. This in turn leads to the high occurrence of palatally displaced canines. In this study, the low number of cases having a congenitally missing maxillary lateral incisor may have accounted for the difference in findings. Further investigations of the congenitally missing maxillary lateral incisors using a bigger sample size may reveal new associations with maxillary canine ectopia.

Summary

Presence of Potentially Ectopic Maxillary Canine	
When Dental Age < 10	<ul style="list-style-type: none"> • If the mandibular lateral incisors have fully erupted and there is no sign of the maxillary lateral incisor buds radiographically, the maxillary lateral incisors could potentially be congenitally missing. This requires the monitoring of the permanent maxillary canines. • If the contralateral maxillary lateral incisor has erupted and there is no sign of the maxillary lateral incisor buds radiographically, the maxillary lateral incisor could potentially be congenitally missing.
When Dental Age ≥ 10	<ul style="list-style-type: none"> • Clinically there is no mobility of the primary canines and radiographically the primary maxillary canines have not begun to resorb. • There is still no sign of the maxillary lateral incisors radiographically.

5.3.2 Aplasia of premolars

In this study, aplasia of premolars was seen in 10 cases with rotated maxillary lateral incisors (Table 4.3.2). Aplasia of premolars did not occur with angulated maxillary canines greater than 30° and mandibular canine enlargement (Table 4.3.2).

When each radiographic marker was looked at separately, the

Chi-square independence test revealed no statistically significant associations with aplasia of premolars (p-values were all > 0.05). The true relationship of this anomaly to potentially ectopic maxillary canine remains unknown and whether it can be used to predict maxillary canine ectopia remains uncertain. Further studies may be needed to clarify the relationship between aplasia of premolars and maxillary canine ectopia.

This study did not find the significant inverse relationship that Baccetti (1998b) found between the maxillary lateral incisor rotation and aplasia of premolars. The difference in findings may be due to the low prevalence of aplasia of premolars within the selected sample size.

5.3.3 Peg-shaped maxillary lateral incisors

Within potentially ectopic maxillary canines, peg-shaped maxillary lateral incisors occurred 1% of the time (Table 4.3.1). In the present study, peg-shaped maxillary lateral incisors did not occur simultaneously with angulated maxillary canines greater than 30°. Peg-shaped maxillary lateral incisors occurred in 5 cases with non-resorption of primary canines (Table 4.3.2).

A statistically significant association was found between peg-shaped maxillary lateral incisors and rotated maxillary lateral incisors. The Chi-square independence test resulted in a p-value of 0.01. The probability test showed that there was only a 0.74% chance for peg-shaped maxillary lateral incisors to occur when a rotated maxillary lateral incisor existed. On the other hand, there was a 33% chance for a rotated maxillary lateral incisor to occur in the presence of a peg-shaped maxillary lateral incisors. This result suggests that peg-shaped maxillary lateral incisors could

possibly be used to identify rotated maxillary lateral incisors. In addition, this result could possibly suggest that rotated maxillary lateral incisors could look like they are peg-shaped lateral incisors because of the severity of the rotation. However, this would need to be further tested to verify this.

A statistically significant association was also found between peg-shaped maxillary lateral incisor and mesial overlap of the maxillary canine cusp tip over the root of the maxillary lateral incisor (p-value of 0.043). The above result supports the work of several authors, who have reported the high incidence of peg-shaped maxillary lateral incisors in children with ectopic maxillary canines (Becker, 1998; Baccetti, 1998; Peck *et al.*, 1996; Zilberman *et al.*, 1990; Brin *et al.*, 1986). They suggested that the displacement of the maxillary canine was due to the insufficient guidance provided by the small root of the peg-shaped maxillary lateral incisor.

All other radiographic markers showed no statistically significant association with peg-shaped maxillary lateral incisors (p-values were all > 0.05). Other studies have also demonstrated no or weak associations between peg-shaped maxillary lateral incisors and the failure of eruption of the maxillary canine (Mossey *et al.*, 1994; Brenchley and Oliver, 1997).

Summary

Presence of Potentially Ectopic Maxillary Canine	
When Dental Age < 10	<ul style="list-style-type: none"> • The presence of peg-shaped maxillary lateral incisors increases the chance of the lateral incisor rotating. This combination requires monitoring of the progress of the permanent maxillary canine. • If peg-shaped lateral incisors exist, the permanent maxillary canine could overlap the root of the adjacent lateral incisor at a later stage.
When Dental Age ≥ 10	<ul style="list-style-type: none"> • If peg-shaped lateral incisors are present, there is no sign of the buccal canine bulge clinically and rotated lateral incisors exist. • Radiographically, the maxillary canine cusp tip is overlapping the root of the adjacent lateral incisor.

5.3.4 Infraocclusion of the primary molars

Infraocclusion of the primary molars was present 5% of the time in potentially ectopic maxillary canine cases (Table 4.3.1). Infraocclusion of the primary molars occurred in 17 cases with rotated maxillary lateral incisors (Table 4.3.2).

No statistically significant associations were found between infraocclusion of primary molars and all other radiographic markers (p-values were all > 0.05). Studies conducted by Baccetti (1998a), Bjerklin *et al.* (1992) and Shalish *et al.* (2010), showed significant associations between infraocclusion of

primary molars and displaced maxillary canines. The difference in the results could possibly be due to the low prevalence of infraoccluded primary molars within the sample. Further investigations may be required using a bigger sample size, which may reveal different associations.

5.3.5 Supernumerary teeth

Of all the developmental anomalies in the present study, supernumerary teeth occurred with potentially ectopic maxillary canines in 32 cases (Table 4.3.1), where they were located in the central incisor region in 22 cases.

Supernumerary teeth occurred in 9 cases when overlap was present (Table 4.3.2). Of the 9 cases, 5 cases showed distal overlap of the maxillary canine cusp tip to the root of the maxillary lateral incisor, 3 cases overlapped the pulp chamber and 1 case had mesial overlap. In addition, seven of these cases showed non-resorption of the primary maxillary canines of which, six cases occurred at dental age 10 and one case occurred at dental age 11.

Sixteen cases had supernumerary teeth and non-resorption of primary maxillary canines occurring simultaneously. Thirteen cases were recorded at dental age 10 and 3 cases at dental age 11. Gomes *et al.* (2008) also found that supernumerary teeth occur commonly between ages 9-10 years and noted non-resorption of the primary maxillary canines to occurring simultaneously.

No statistically significant association was found between supernumerary teeth and various radiographic markers (p-values were all > 0.05). The present study agrees with Baccetti's

(1998) statement where he stated that “supernumerary teeth were separate pathologic entities.” According to Baccetti’s (1998) study, the group with supernumerary teeth did not show any significant associations with palatally displaced maxillary canines.

Summary

Presence of Potentially Ectopic Maxillary Canine	
When Dental Age < 10	<ul style="list-style-type: none"> • If a supernumerary tooth is present in the region of the maxillary canine, the permanent maxillary canine needs to be monitored for ectopic placement at a later stage.
When Dental Age ≥ 10	<ul style="list-style-type: none"> • Buccal canine bulge is not palpable and there is no mobility of the primary canines clinically. • Radiographically, no resorption of the primary canine has occurred and a supernumerary tooth is present clinically or radiographically.

5.3.6 Taurodontism

Taurodontism occurred 1.4% of the time with potentially ectopic maxillary canines (Table 4.3.1). Taurodontism occurred in 6 cases with rotated maxillary lateral incisors and in zero cases with angulated maxillary canines greater than 30⁰ (Table 4.3.2).

Taurodontism showed no statistically significant association with potentially ectopic maxillary canines determined by the 6 radiographic markers. The Chi-square independence test

revealed a p-value of 0.48. Nagpal *et al.* (2009), proposed a statistically significant relationship between maxillary canine ectopia and taurodontism. However, in the present study taurodontism showed a statistically significant association with angulation (p-value of 0.0049). When the angulation of the maxillary canine was greater than 30° , the probability test found that there was a 22% chance of taurodontism occurring. There was only a 9% chance of angulation of the maxillary canine being greater than 30° when taurodontism existed. When clinicians identify taurodontism prior to dental age 10, they should be aware of the possibility of angulation of the maxillary canines to be greater than 30° . This enables them to take timeous interceptive measures by monitoring the movement of the maxillary canine.



Summary

Presence of Potentially Ectopic Maxillary Canine	
When Dental Age < 10	<ul style="list-style-type: none"> • If taurodontism is present, there is a chance that the permanent maxillary canine will have an angulation greater than 30° at a later stage.
When Dental Age ≥ 10	<ul style="list-style-type: none"> • The buccal canine bulge is not palpable clinically. • Radiographically taurodontism is present and angulation of the maxillary canine is greater than 30°.

5.3.7 Dilaceration

In the present study, the prevalence of dilacerated maxillary lateral incisors was 3% in the presence of potentially ectopic maxillary canines. Dilaceration occurred in 14 cases with rotated maxillary lateral incisors (Table 4.3.2).

In a sample size of 480 Chohayeb (1983), reported that distolabial dilaceration occurred in 52% of the maxillary lateral incisors. He disregarded angles less than 20° when recording dilaceration. The maxillary lateral incisors have a normal anatomical distal curvature (Ingle, 1985) for which, the exact degree of angulation is unknown. This result is therefore still questionable, because the normal anatomical curvature could have been 30° or more and these cases may have been included as an anomaly when Chohayeb (1983) was recording the prevalence of dilaceration, thus, bringing about the high prevalence of dilaceration of the maxillary lateral incisors.

The data reported by Chohayeb (1983) is not consistent with Malcic *et al.*'s (2006) results, where the prevalence of dilaceration for the lateral incisors was 1.43% in a sample size of 488 on panoramic radiographs and 7% on periapical radiographs. They recorded all dilacerations greater than or equal to 90° , which is a strict criterion compared to Chohayeb's (1983) criteria. One may now question if a dilaceration of 45° is normal or abnormal. As mentioned earlier in section 2.5.7, no literature has specified the normal anatomical angle for dilaceration, which is why researchers have various criteria.

Hamasha *et al.* (2002) reported a prevalence of 1.2% in a sample size of 812 for dilaceration in the maxillary lateral

incisors on periapical radiographs. They also recorded all dilacerations 90° and above. However, compared to Malcic *et al.*'s study (2006), they found a lower prevalence for dilaceration using periapical radiographs. The present study uses panoramic radiographs to identify dilacerations. Hence, Hamasha *et al.*'s (2002) prevalence could not be compared with the present study.

In the present study, no statistically significant association was found between dilaceration and potentially ectopic maxillary canines determined by the 6 radiographic markers. The Chi-square independence test resulted in a p-value of 0.24. No other studies have been conducted in the past to investigate the relationship between dilaceration and ectopic maxillary canines.

Dilaceration showed a statistically significant association with non-resorption of primary maxillary canines (p-value is 0.03). When non-resorbed primary maxillary canines existed, the probability test showed that there was a 29% chance of dilaceration occurring. There was only a 2% chance for non-resorption of the primary maxillary canines to occur when dilaceration existed.

Dilaceration did not show a statistically significant association with all other radiographic markers (p-values > 0.05). No other studies have examined the connection between dilaceration and the various radiographic markers.

More cases of dilaceration were found in the posterior segment compared to the anterior segment in the present study. A total of 3 premolars and 14 molars had dilaceration, whereas only 4 central incisors and 2 lateral incisors had dilaceration. This was

consistent with studies conducted by Malcic *et al.* (2006) and Hamasha *et al.* (2002).

5.3.8 Ectopic molars

In the present study, no ectopic first molars were recorded in the presence of potentially ectopic maxillary canines (Table 4.3.1). The diagnosis of an ectopic first molar is usually done before the eruption of these teeth, usually between 5 to 7 years of age. Since the current study only used panoramic radiographs from dental age 8 years and above, it could not detect any ectopic first molars. The only way to determine if a first molar had ectopically erupted, was to identify the presence of resorption in the distobuccal root of the second primary molar (Becktor *et al.*, 2005; Barberia-Leache *et al.*, 2005).

The present study did not find any statistically significant associations with the various radiographic markers (p-values were all > 0.05). This study supports the findings of Baccetti's study (1998). However, Bjerklin *et al.* (1992) found a statistically significant association between ectopic maxillary canines and ectopic molars. Reasons for the difference in findings have already been discussed above.

Chapter 6

Conclusion and Recommendations

6.1 Conclusion

This study focused on examining the radiographic markers that could possibly be used to predict potentially ectopic maxillary canines before their eruption. These were the statistically significant relationships found between the radiographic markers:

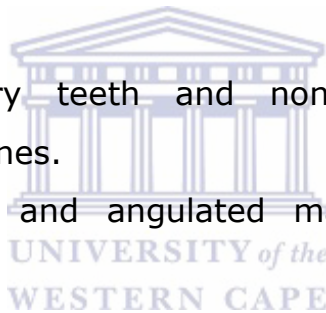
1. Rotated maxillary lateral incisors and distal overlap of the maxillary canine cusp tip over the root of the maxillary lateral incisor.
2. Non-resorption of primary maxillary canines and distal overlap of the maxillary canine cusp tip over the root of the maxillary lateral incisor, overlap over the pulp chamber of the maxillary lateral incisor and angulated maxillary canines greater than 30⁰.
3. Maxillary canine enlargement and mandibular canine enlargement.
4. Mandibular canine enlargement and mesial overlap of the maxillary canine cusp tip over the root of the maxillary lateral incisor.

The most notable of the above findings is the relationship between maxillary canine enlargement and mandibular canine enlargement. Since mandibular canines develop earlier than maxillary canines, the finding indicates that clinicians can

potentially intercept ectopic maxillary canines upon finding a developing ectopic mandibular canine.

Apart from the above findings, this study also examined the relationship between developmental anomalies and potentially ectopic maxillary canines as indicated by 6 radiographic markers. The following anomalies showed a statistically significant relationship with individual radiographic markers:

1. Peg-shaped maxillary lateral incisors and mesial overlap of the maxillary canine cusp tip over the root of the maxillary lateral incisor and rotated maxillary lateral incisors
2. Root dilaceration and non-resorption of primary maxillary canines.
3. Supernumerary teeth and non-resorption of primary maxillary canines.
4. Taurodontism and angulated maxillary canines greater than 30°.



Thus, clinicians aware of these associations can use these developmental anomalies as indicators of potentially ectopic maxillary canines. This allows timeous interception and potentially circumvents long and complex surgical treatments at later stages. In addition, the secondary effects of such treatment could be eliminated.

Unlike other studies, congenitally missing laterals, infraocclusion of primary molars, supernumerary teeth, ectopic molars, and aplasia of premolars did not have a statistically significant association with the various radiographic markers determining potentially ectopic maxillary canines. The difference in results

could be explained by a low prevalence of these anomalies in the sample.

6.2 Clinical Considerations and Recommendations

Presence of a potentially ectopic maxillary canine when dental age < 10 years
<p>If the mandibular canine is lingually placed, then it is likely that:</p> <ol style="list-style-type: none">1) Rotation of the maxillary lateral incisor is present.2) Non-resorption of the primary maxillary canine occurs later.3) The maxillary canine cusp tip will overlap the root of the adjacent lateral incisor at a later stage.4) The maxillary canine becomes palatally displaced.
<p>If the mandibular lateral incisors have fully erupted and there is no sign of the maxillary lateral incisor buds radiographically, the maxillary lateral incisors could potentially be congenitally missing. This requires the monitoring of the permanent maxillary canines. This also applies if the contralateral maxillary lateral incisor has erupted.</p>
<p>If peg-shaped maxillary lateral incisors exist, maxillary lateral incisors may rotate. In which case, the progress of the permanent maxillary canine should be monitored as the maxillary canine could overlap the root of the adjacent lateral incisor at a later stage.</p>
<p>If taurodontism is present, there is a chance that the permanent maxillary canine will have an angulation greater than 30° at a later stage. Clinicians, should monitor the permanent canine in this scenario.</p>


**Presence of a potentially ectopic maxillary canine
When Dental Age \geq 10**

If the following clinical findings are found a supplementary radiograph is advised:

- 1) Buccal canine bulge is not palpable
- 2) No mobility of the primary canine.
- 3) Maxillary lateral incisors are rotated.

Radiographically:

- 1) The primary canines have not begun resorbing,
- 2) Rotation of the maxillary lateral incisors is confirmed,
- 3) The maxillary canine overlaps the root of the adjacent maxillary lateral incisor and may also have an angulation greater than 30° .



Based on the results of this study, a long-term cohort study should be conducted to determine the impact of various developmental anomalies on maxillary canine ectopia (as opposed to potential ectopia). Importance must be given to the clinical examination of the buccal maxillary canine bulges. This should be conducted between dental ages 9-11 years to establish the presence or absence of the maxillary canine bud. The absence of the maxillary canine bulge would require the clinician to further investigate during the late mixed dentition period, using panoramic radiographs to diagnose maxillary canine ectopia. These investigations may expose different associations.

In addition, recording the chronological age, dental age, gender, ethnicity and conducting a space analysis is recommended to support treatment plans.



References

Alqerban A, Jacobs R, Souza PC, Willems G. In-vitro comparison of 2 cone-beam computed tomography systems and panoramic imaging for detecting simulated canine impaction-induced external root resorption in maxillary lateral incisors. *Am J Orthod Dentofac Orthop* 2009; 136 (6): 764-765.

American Academy of Pediatric Dentistry Reference manual Clinical Guidelines. In: Guideline on management of the developing dentition and occlusion in pediatric dentistry. 2001; 36(6): 251-263. Accessed on: 13/08/2015. Available online at: www.aapd.org/media/Policies_Guidelines/G_DevelopDentition.pdf

Andreasen GF. A review of the approaches to treatment of impacted maxillary cuspids. *Int J Oral Surg* 1971; 31: 479-484.

Andreasen JO. Traumatic injuries of the teeth. 2nd edition. W.B Saunders, Copenhagen, Munksgaard 1981. Chapter 9. Page 273.

Andreasen JO and Ravn JJ. The effect of traumatic injuries to primary teeth on their permanent successors. A clinical and radiographic follow-up study of 213 teeth. *Scand J Dent Res* 1971; 79 (4): 219-283.

Arens DE: An alternative treatment for severely resorbed maxillary lateral incisor: A sequela of ectopic eruption. *J Endod* 1995; 21 (2): 95-100.

Arte S, Pirinen S. Hypodontia. Orphanet Encyclopedia May 2004. Accessed on: 16/08/2015. Available online at: <https://www.orpha.net/data/patho/GB/uk-hypodontia.pdf>

Avitia S, Hamilton JS, Osborne RF. Dentigerous cyst presenting as orbital proptosis. *Ear Nose Throat J* 2007; 86 (1): 23-4.

Baccetti T. A controlled study of associated dental anomalies. *Angle Orthod* 1998a; 68 (3): 267-274. Accessed on: 09/07/2013. Available online at:<http://www.angle.org/doi/pdf/10.1043/0003-3219%281998%29068%3C0267%3AACSOAD%3E2.3.CO%3B2>

Baccetti T. Tooth rotation associated with aplasia of nonadjacent teeth. *Angle Orthod* 1998b; 68(5): 471-474. Accessed on: 28/11/2015. Available online at: <http://www.angle.org/doi/pdf/10.1043/00033219%281998%29068%3C0471%3ATRAWAO%3E2.3.CO%3B2>

Baccetti T, Leonardi M, Armi P. A randomized clinical study of two interceptive approaches to palatally displaced canines. *Euro J Orthod* 2008; 30(4): 381-385. Accessed on: 05/07/2014. Available online at: <http://ejo.oxfordjournals.org/content/eortho/30/4/381.full.pdf>

Barberia-Leache E, Suarez-Clus MC, Seavedra-Ontiveros D. Ectopic eruption of the maxillary first permanent molar: Characteristics and Occurrence in growing children. *Angle Orthod*. 2005; 75(4): Pages 610-615. Accessed on: 18/09/2015. Available online at: [http://www.angle.org/doi/pdf/10.1043/00033219\(2005\)75%5B610%3AEEOTMF%5D2.0.CO%3B2](http://www.angle.org/doi/pdf/10.1043/00033219(2005)75%5B610%3AEEOTMF%5D2.0.CO%3B2)

Bass TB. Observations on the misplaced upper canine tooth. *The Dental Practitioner and Dental Record*. 1967; 18: 25-33.

Becker A: Etiology of maxillary canine impactions. Am J Orthod 1984; 86 (5): 437-438.

Becker A. The effects of infraocclusion: Part 3. Dental arch length and the midline. Am J Orthod Dentofac Orthop 1992; 102 (5): 427-433.

Becker A. Palatally impacted canines: In: Orthodontic treatment of impacted teeth. Martin Dunitz Ltd. 1998; Chapter 6, Pages 85-101.

Becker A, Chaushu S. Dental age in maxillary canine ectopia. Am J Orthod Dentofac Orthop. 2000; 117(6): 657-662.

Becker A, Karnei-R'em RM. The effects of infraocclusion: Part 1. Tilting of the adjacent teeth and local space loss. Am J Orthod Dentofac Orthop. 1992; 102 (3): 256-64.

Becker A, Smith P, Behar R. The incidence of anomalous maxillary lateral incisors in relation to palatally displaced cuspids. Angle Orthod. 1981; 51 (1): 24-29. Accessed on: 15/07/2014. Available online at:
<http://www.angle.org/doi/pdf/10.1043/00033219%281981%29051%3C0024%3ATIOAML%3E2.0.CO%3B2>

Becker A, Zilbermann Y, Tsur B. Root length of lateral incisors adjacent to palatally displaced maxillary cuspids. Angle Orthod 1984; 54 (3): 218-225. Accessed on: 14/08/2015. Available online at:
<http://www.angle.org/doi/pdf/10.1043/00033219%281984%29054%3C0218%3ARLOLIA%3E2.0.CO%3B2>

Becktor KB, Steiniche K and Kjaer I. Association between ectopic eruption of maxillary canines and first molars. *Eur J Orthod* 2005; 27 (2): 186-189. Accessed on: 23/08/2014. Available online at:

<http://ejo.oxfordjournals.org/content/eortho/27/2/186.full.pdf>

Bjerklin K and Ericson S. How a computerized tomography (CT) examination changed the treatment plans of 80 children with retained and ectopically positioned maxillary canines. *Angle Orthod* 2006; 76: 43-51. Accessed on: 02/04/2017. Available online at:

<http://www.angle.org/doi/pdf/10.1043/00033219%282006%29076%5B0043%3AHACTEC%5D2.0.CO%3B2?code=angf-site>

Bjerklin K, Kuroi J, Valentin J. Ectopic eruption of maxillary first permanent molars and association with other tooth and developmental disturbances. *Eur J Orthod* November 1992; 14: 369-375. Accessed on: 12/09/2014. Available online at: http://www.researchgate.net/profile/Jack_Valentin/publication/21758788_Ectopic_eruption_of_maxillary_first_permanent_molars_and_association_with_other_tooth_and_developmental_disturbances/links/0046351aca514522bd000000.pdf

Brenchley Z, Oliver RG. Morphology of anterior teeth associated with displaced canines. *British J Orthod* 1997; 24 (1): 41-45.

Brin I, Becker A, Shalhav M. Position of the maxillary permanent canine in relation to anomalous or missing lateral incisors: a population study. *Eur J Orthod* 1986; 8 (1): 12-16.

Brin I, Fuks A, Bassat YB, Zilberman Y. Trauma to primary incisors and its effect on the permanent successors. *Pediatric Dent* 1984; 6(2): 78-82.

Brin I, Solomon Y, Zilbermann Y. Trauma as a possible etiologic factor in maxillary canine impaction. *Am J Orthod Dentofac Orthop* 1993; 104: 132-137.

Broadbent BH. The face of the normal child. *Angle Orthod.* 1937; 7(4): Pages 183-208. Accessed on: 26/09/2014. Available online at:[http://www.angle.org/doi/pdf/10.1043/00033219\(1937\)007%3C0183:TFOTNC%3E2.0.CO%3B2](http://www.angle.org/doi/pdf/10.1043/00033219(1937)007%3C0183:TFOTNC%3E2.0.CO%3B2)

Broadbent BH. Ontogenic development of occlusion. *Ang Orthod* 1941; 11: 223-241. Accessed on: 20/08/14. Available online at: [http://www.angle.org/doi/pdf/10.1043/00033219\(1941\)011%3C0223%3AODOO%3E2.0.CO%3B2](http://www.angle.org/doi/pdf/10.1043/00033219(1941)011%3C0223%3AODOO%3E2.0.CO%3B2)

Brown ID. Some further observations on submerging deciduous molars. *Br J Orthod* 1981; 8: 99-107.

Cameriere R, Ferrante L, Cingolani M. Age estimation in children by measurement of open apices in teeth. *Int J Legal Med* 2006; 120 (1): 49-52.

Chalakkal P, Thomas AM and Chopra S. Displacement, location, and angulation of unerupted permanent maxillary canines and absence of canine bulge in children. *Am J Orthod Dentofac Orthop* 2011; 139 (3): 345-350.

Chohayeb AA. Dilaceration of permanent upper lateral incisors: Frequency, direction and endodontic treatment implications. *Oral Surg Oral Med Oral Path* 1983; 55: 519-20.

Chu FC, Li TK, Lui VK, Newsome PR, Chow RL, Cheung LK. Prevalence of impacted teeth and associated pathologies- a radiographic study of the Hong Kong Chinese population. Hong Kong Med J 2003; 9(3):158-163. Accessed on 02/04/2017.

Available online at:

<https://hub.hku.hk/bitstream/10722/44552/1/80571.pdf?accept=1>

Coulter J, Richardson A. Normal eruption of the maxillary canine quantified in three dimensions. Eur J Orthod 1997; 19: 171-183.

Davidson LE, Rodd HD. Interrelationship between dental age and chronological age in Somali children. Community Dent Health. 2001; March 18(1): Pages 27-30. Accessed on: 14/08/2016.

Available online at: http://www.dentalage.co.uk/wp-content/uploads/2014/09/davidson_le__rodd_hr_2001_somali_daa.pdf



Demirjian A, Goldstein H, Tanner JM. A new system of dental age assessment. Hum Biol 1973; 45: 211-227.

Dewel BF. The upper cuspid: its development and impaction. Angle Orthod 1949; 19:79-90. Accessed on: 26/08/2014. Available online at:<http://www.angle.org/doi/pdf/10.1043/0003-3219%281949%29019%3C0079%3ATUCIDA%3E2.0.CO%3B2>

Durr DP, Campos CA, Ayers CS. Clinical significance of taurodontism. J Am Dent Assoc 1980; 100(3): 378-381.

Duterloo HS. Development and chronology of the dentition and Abnormalities of dentitional development. In: An atlas of dentition in childhood, orthodontic diagnosis and panoramic radiology. Wolfe Publishing Limited, England, 1991: 69-96, 129-196.

Edamatsu M, Kumamoto H, Ooya K, Echigo S. Apoptosis related factors in the epithelial components of dental follicles and dentigerous cysts associated with impacted third molars of the mandible. Oral Surg Oral Med Oral Path Oral Radio 2005; 99 (1): 17-23.

Ekim SL, Hatibovic-Kofman S. A treatment decision-making model for infraoccluded primary molars. Int J Ped Dent 2001; 11: 340-346.

Elgamri AIEG. A comparison of the dental age estimation methods of Phillips and Proffit in a sample of South African children at the Tygerberg Dental Faculty. 2016. February.

Endo T, Ozoe R, Kubota M, Akiyama M, Shimooka S. A survey of hypodontia in Japanese orthodontics patients. Am J Orthod Dentofac Orthop 2006; 129: 29-35.

Ericson S, Bjerklin K, Falahat B. Does the canine dental follicle cause resorption of permanent incisor roots? A computed tomographic study of erupting maxillary canines. Angle Orthod. 2002; 72(2): Pages 95-104. Accessed on: 16/10/16. Available online at:

<http://www.angle.org/doi/pdf/10.1043/00033219%282002%29072%3C0095%3ADTCDFC%3E2.0.CO%3B2>

Ericson S, Kurol J. Radiographic assessment of maxillary canine eruption in children with clinical signs of eruption disturbance. *Eur J Orthod* 1986a; 8: 133-140.

Ericson S, Kurol J. Longitudinal study and analysis of clinical supervision of maxillary canine eruption. *Community Dent Oral Epidemiol* 1986b; 14: 172-76.

Ericson S, Kurol J. Radiographic examination of ectopically erupting maxillary canines. *Am J Orthod Dentofac Orthop* 1987a; 91: 483-492.

Ericson S, Kurol J. Incisor Resorption caused by maxillary cuspid. A radiographic study. *Ang Orthod* 1987b; 57: 332-346. Accessed on: 22/11/2014. Available online at:
<http://www.angle.org/doi/pdf/10.1043/00033219%281987%29057%3C0332%3AIRCBMC%3E2.0.CO%3B2>

Ericson S, Kurol J. Early treatment of palatally erupting maxillary canines by extraction of the primary canines. *Eur J Orthod* 1988a; 10: 283-295.

Ericson S, Kurol J. Resorption of maxillary lateral incisors caused by ectopic eruption of the canines. A clinical and radiographic analysis of predisposing factors. *Am J Orthod Dentofac Orthop* 1988b; 94: 503-513.

Ericson S, Kurol J. Resorption of incisors after ectopic eruption of maxillary canines: A CT-study. *Angle Orthod* 2000; 70: 415-423. Accessed on: 15/04/2014. Available online at:
<http://www.angle.org/doi/pdf/10.1043/00033219%282000%29070%3C0415%3AROIAEE%3E2.0.CO%3B2>

Falahat B, Ericson S, D'Amico RM, Bjerklin K. Incisor root resorption due to ectopic maxillary canines: A long-term radiographic follow-up. *Angle Orthod* 2008; 78 (5): 778-785.

Accessed on: 21/10/2014. Available online at:

<http://www.angle.org/doi/pdf/10.2319/071007-320.1>

Fastlicht S. Treatment of impacted canines. *Am J Orthod* 1954; 40: 891.

Feichtinger C, Rossiwall B. Taurodontism in human sex chromosome aneuploidy. *Arch Oral Biol* 1977; 22: 327-329.

Fernandez E, Bravo LA, Canteras M. Eruption of the permanent upper canine: A radiological study. *Am J Orthod Dentofac Orthop* 1998; 113: 414-420.

Fleming PS, Scott P, Heideri N, DiBiase AT. Influence of radiographic position of ectopic canines on the duration of Orthodontic treatment. *Angle Orthod*. 2009; 79(3): Pages 442-446. Accessed on: 16/10/2015. Available online at:

<http://www.angle.org/doi/pdf/10.2319/042708-238.1>

Gardiner J. Supernumerary teeth. *Dent. Pract. Dent. Rec.* 1961; 12: 63-73.

Garn SM, Lewis AB, Polacheck DL. Variability of tooth formation. *J Dent Research* 1959; 38(1): 135-147.

Goaz PW, White SC. Dental Anomalies. In: *Oral radiology principles and interpretation*. CV Mosby, London 1982; Pages 336-393.

Gomes CDO, Drummond SN, Jham BC, Abdo EN and Mesquita RA. A survey of 460 supernumerary teeth in Brazilian children

and adolescents. *Int J Paediatric Dent.* 2008; 18(2): Pages 98-106.

Goya HA, Tanaka S, Maeda T, Akimoto Y. An orthopantomographic study of hypodontia in permanent teeth of Japanese pediatric patients. *Journal of Oral Science* 2008; 50(2): 143-150.

Guttal KS, Naikmasur VG, Bhargava P, Bathi RJ. Frequency of Developmental Dental Anomalies in the Indian Population. *Eur J Dent* 2010; 4(3):263-269.

Hamasha AA, Al-Khateeb T, Darwazeh A. Prevalence of dilaceration in Jordanian adults. *Int Endod J* 2002; 35: 910-912.

Haavikko K. The formation and alveolar and clinical eruption of permanent teeth. An orthopantomographic study. *Proc Finn Dent Soc* 1970; 66: 103-170.

Hitchin AD. The impacted maxillary canine. *Br Dent J* 1956; 100: 1-14.

Houston WJB, Stephens CD, Tulley WJ. A textbook of Orthodontics, 2nd edn. Bristol: Wright; 1992. Page 187.

Howard RD. The unerupted incisor. A study of the postoperative eruptive history of incisors delayed in their eruption by supernumerary teeth. *Dent Pract Dent Rec* 1967; 17: 332-41.

Hudson APG, Harris AMP, Morkel JA, Amra I. Infraocclusion of primary molars: a review of the literature. *SADJ.* 2007; 62: 114-122.

Hudson APG, Harris AMP, Mohamed N. The mixed dentition pantomogram: A valuable dental development assessment tool for the dentist. SADJ. 2009; 64 (10): 480-483. Accessed on: 12/10/2013. Available online at: <http://repository.uwc.ac.za/xmlui/bitstream/handle/10566/416/HudsonPantomogram2009.pdf?sequence=4>

Hudson APG, Harris AMP, Mohamed N. Maxillary canine management in the pre-adolescent: A guideline for general practitioners. SADJ. 2010; 65 (8): 366-370. Accessed on: 21/11/2013. Available online at: <http://repository.uwc.ac.za/bitstream/handle/10566/417/HudsonMaxillaryCanine2010.pdf?sequence=4&isAllowed=y>

Hurme VO. Ranges in normalcy in the eruption of permanent teeth. J Dent Child. 1949; 16: Page 11.

Ingle JJ. Endodontics. 3rd edition. Lea and Febiger. Philadelphia, 1985. Pages 120-121.

Isaacson KG, Thom AR. Guidelines for the use of radiographs in clinical orthodontics. 2nd edition. British Orthod Society 2001, London.

Ishikawa G. Oral Pathology 2. Kyoto Nagasueshoten Co; 1982. pp. 379-81.

Jacoby H. The etiology of maxillary canine impactions. Am J Orthod 1983; 83: 125-132.

Kettle MA. Treatment of the unerupted maxillary canine. Transactions of the British Society for the study of Orthodontics. 1957. Pages 74-84.

Kettle MA. Treatment of the unerupted maxillary canine. *Dent Practit Dent Rec* 1958; 8: 245-255.

Kokich V. Early management of congenitally missing teeth. *Semin Orthod* 2005; 11: 146–151. Accessed on: 23/09/2014.
Available online at:

<http://www.kokichorthodontics.com/assets/uploads/docs/Article132f.pdf>

Kramer RM, Williams AC. The incidence of impacted teeth. *Oral Surg Oral Med Oral Pathol.* 1970; 29: Pages 237-241.

Kurol J. Early treatment of tooth-eruption disturbances. *Am J Orthod Dentofac Orthop* 2002; 121:588-589.

Kurol J, Bjerklin K. Resorption of maxillary second primary molars caused by ectopic eruption of the maxillary first permanent molar: A longitudinal and histological study. *J Dent Child* 1982; 49: 273-279.

Kurol J, Bjerklin K. Ectopic eruption of maxillary first permanent molars: A review. *J Dent Child* 1986; 53: 209-214.

Kurol J, Ericson S, Andreason JO. The impacted maxillary canine. In Andreason JO, Petersson JK, Laskin DM, eds. *Textbook and color atlas of tooth impactions.* 1997 Mosby, Copenhagen, Denmark; Pages 124-164.

Kurol J, Thilander B. Infrocclusion of primary molars and the effect on occlusal development, a longitudinal study. *Eur J Orthod* 1984; 6:277-293.

Kurol J, Olson L. Ankylosis of primary molars-a future periodontal threat to the first permanent molars? *Eur Orthod Soc* 1991; 13 (5): 404-409.

Langland OE, Langlais RP, McDavid WD, DelBalso AM. Troubleshooting Errors in Panoramic Techniques. In: Panoramic Radiology. 2nd Edition. Lea and Febiger. 1989, Philadelphia; Pages 224, 245-246.

Lappin M. Practical management of the impacted maxillary cuspid. Am J Orthod Dentofac Orthop 1951; 37: 769-78.

Leifert S and Jonas I. Dental anomalies as a micro symptom of palatal canine displacement. J Orofac Orthop. 2003; 64: Pages 108-120.

Leurs IH, Wattel E, Aartman IH, Eddy E, Prah-Andersen B. Dental age in Dutch children. Eur J Orthod. 2002; 27: 309-314.

Lindauer SJ, Rubenstein LK, Hang WM, Andersen WC, Isaacson RJ. Canine impaction identified early with panoramic radiographs. JADA. 1992; 123 (3): 91-7.

Litsas G, Acar A. A Review of Early Displaced Maxillary Canines: Etiology, Diagnosis and Interceptive Treatment. The Open Dentistry Journal 2011; 5: 39-47. Accessed on: 17/11/2014.

Available online at:

<http://www.ncbi.nlm.nih.gov/pmc/articles/PMC3091288/pdf/TODENTJ-5-39.pdf>

Liuk IW, Olive RJ, Griffin M, Monsour P. Associations between palatally displaced canines and maxillary lateral incisors. Am J Orthod Dentofac Orthop 2013; 143 (5): 622-632.

Lo R and Moyers RE. Studies in the etiology and prevention of malocclusion: I. The sequence of eruption of the permanent dentition. Am J Orthod 1953; 39(6): 460-467.


Malcic A, Jukic S, Brzovic V, Miletic I, Pelivan I, Anic I. Prevalence of root dilaceration in adult dental patients in Croatia. *Oral Surg Oral Med Oral Pathol Oral Radiol Endod* 2006; 102: 104-9.

Manjunatha BS, Kovvuru SK. Taurodontism–A Review on its etiology, prevalence and clinical considerations. *J Clin Exp Dent*. 2010; 2(4): 187-190. Accessed on: 28/11/2014. Available online at:<http://www.medicinaoral.com/odo/volumenes/v2i4/jcedv2i4p187.pdf>

Mason C, Papadakou P, Roberts GJ. The radiographic localization of impacted maxillary canines: a comparison of methods. *Eur J Orthod*. 2001; 23(1): 25-34. Accessed on: 19/11/2014.

Available online at:

<http://ejo.oxfordjournals.org/content/eortho/23/1/25.full.pdf>

McSherry PF. The ectopic maxillary canine: A review. *Br J Orthod* 1998; 25: 209-16. 

Mead SV. Incidence of impacted teeth. *Int J Orthod* 1930; 16: 885.

Mercuri E, Cassetta M, Cavallini C, Vicari D, Leonardi R, Barbato E. Dental anomalies and clinical features in patients with maxillary canine impaction: A retrospective study. *Angle Orthod*. 2013; 83: 22-28. Accessed on: 21/11/2014. Available online at: <http://www.angle.org/doi/pdf/10.2319/021712-149.1>

Miller BH. The influence of congenitally missing teeth on the eruption of the upper canine. *Dent Practit* 1963; 13: 497-504.

Mitchell L and Bennett TG. Supernumerary teeth causing delayed eruption: A retrospective study. *Br J Orthod* 1992; 19: 41-46.

Montelius GA. Impacted teeth, a comparative study of Chinese and Caucasian dentitions. J Dent Res. 1932; 12: Pages 931-938.

Moorrees CFA, Fanning EA and Hunt EE. Age variation of formation stages for ten permanent teeth. J Dent Research 1963; 42:1490-1502.

Moraes RS, Farinhas JA, Gleiser R, Primo LG. Delayed eruption of maxillary permanent central incisors as a consequence of mesiodens: a surgical re-treatment approach. J Clin Pediatr Dent 2004; 28 (3): 195-198.

Mosby CV. Contemporary Orthodontics. The later stages of development. St. Louis 1986; 69-72.

Moss JP. The unerupted canine. Dent Practit 1972; 22: 241-248.

Mossey PA, Campbell HM, Luffingham JK. The palatal canine and the adjacent lateral incisor: A study of a West of Scotland population. Br J Orthod 1994; 21: 169-174.

Moyers RE. Etiology of Malocclusion and Adolescent Treatment. In: Handbook of Orthodontics. 4th ed. Year Book Medical Publishers Inc, Chicago 1988: 140-164, 387, 432-471.

Moyers RE, Van der Linden FPGM, Riolo ML, McNamara JA Jr. Standards of human occlusal development. In: Monograph No. 5, Craniofacial growth series. Center for Human Growth and Development. University of Michigan, Ann Arbor; 1976.

Nagpal A, Pai KM, Sharma G. Palatal and labially impacted maxillary canine associated dental anomalies: A comparative study. *J Contemp Dent Pract* 2009; 10 (4): 1-11. Accessed on: 06/05/2016. Available online at: http://www.jaypeejournals.com/eJournals/ShowText.aspx?ID=1984&Type=FREE&TYP=TOP&IN=_eJournals/images/JPLOGO.gif&IID=167&isPDF=YES

Nanda SK. The developmental basis of occlusion and malocclusion. Events in the life cycle of each permanent tooth. Quintessence Publishing Company, Chicago 1983; Pages 81-158.

Nelson SJ, Ash MM. 1. The permanent canines: maxillary and mandibular 2. The permanent maxillary incisors. In: Wheeler's Dental Anatomy, Physiology and Occlusion. 9th edition. Saunders Elsevier Inc, printed in China 2010: Pages 31, 107-111, 125.

Neville BW, Damm DD, Allen CM, Bouquot JE. Abnormalities of teeth. In: Oral and maxillofacial pathology. 3rd edition. Saunders an imprint of Elsevier. St Louis. Published in India. 2009; Page 83.

Newcomb MR. The recognition and interception of aberrant canine eruption. *Angle Orthod* 1959; 29 (3): 161-168. Accessed on: 12/10/2015. Available online at: <http://www.angle.org/doi/pdf/10.1043/0003-3219%281959%29029%3C0161%3ARAIIOAC%3E2.0.CO%3B2>

Nik-Hussein NN. Hypodontia in the permanent dentition: A study of its prevalence in Malaysian children. *Aus Orthod J* 1989; 11: 93-95.

Nolla CM. The development of permanent teeth. *J Dent Child* 1960; 27: 254.

Noyes FB. A textbook of dental histology and embryology including laboratory directions. 4th edition. Kimpton, London 1930; Page 370.

Nykanen R, Espeland L, Kvaal SI, Krogstad O. Validity of the Demirjian method for dental age estimation when applied to Norwegian children. *Acta Odontol Scand*. 1998; Aug 56(4): Pages 238-244. Accessed on: 15/09/2016. Available online at: http://www.dentalage.co.uk/wpcontent/uploads/2014/09/nykanen_r_et_al_1998_daa_demirjian_norwegian_children.pdf

Nystrom M, Ranta R, Kataja M and Silvola H. Comparisons of dental maturity between the rural community of Kuhmo in North Eastern Finland and the city of Helsinki. *Community Dent Oral Epidemiol* 1988; 16(4): 215-257. Accessed on 02/04/2017. Available online at: http://www.dentalage.co.uk/wpcontent/uploads/2014/09/nystrom_m_et_al_1988_dent_mat_finland.pdf

Ooshima T, Ishida R, Mishima K and Sobue S. The prevalence of developmental anomalies of teeth and their association with tooth size in the primary and permanent dentitions of 1650 Japanese children. *Int J Paediatr Dent* 1996; 6: 87-94.

Paul RK and Raju AS. The ectopic maxillary canine: An orthodontist prospective. *Int J Orthod*. 2013. Accessed on: 24/09/2015. Available online at: www.ijoonline.net/journal/2013_1/2013_1_33.pdf

Patti A, Perrier D'Arc G. Diagnostic Examinations. In: Clinical success in early Orthodontic treatment. Quintessence Books, Paris, 2005. Pages 33-52.

Peck S, Peck L, Kataja M. The palatally displaced canine as a dental anomaly of genetic origin. *Ang Orthod* 1994; 64 (4): 249-256. Accessed on: 18/09/2014. Available online at: [http://www.angle.org/doi/pdf/10.1043/0003-3219\(1994\)064%3C0250%3ATPDCAA%3E2.0.CO%3B2](http://www.angle.org/doi/pdf/10.1043/0003-3219(1994)064%3C0250%3ATPDCAA%3E2.0.CO%3B2)

Peck S, Peck L, Kataja M. Site specificity of tooth maxillary agenesis in subjects with canines malpositions. *Angle Orthod*. 1996; 66: Pages 473-476. Accessed on: 09/08/2016. Accessed on: 25/08/2016. Available online at: <http://www.angle.org/doi/pdf/10.1043/0003-3219%281996%29066%3C0473%3ASSOTAI%3E2.3.CO%3B2>

Peedikayil FC. Delayed tooth eruption. *Journal of dentistry* 2011; 1 (4): 81-86. Accessed on: 12/08/2016. Available online at: www.ejournalofdentistry.com/articles/e-jod7b953303c6-ad2f-4096-811e-5044838bcab7.pdf

Pemberton TJ, Das P, Patel PI. Hypodontia: genetics and future perspectives. *Braz J Oral Sci* 2005; 4: 695-706. Accessed on: 11/09/2015. Available online at: <http://bioline.org.br/request?os05011>

Pirinen S, Arte S and Apajalathi S. Palatal displacement of canine is genetic and related to congenital absence of teeth. *Journal of Dental Research*. 1996; 75(10): Pages 1742-1746. Accessed on: 03/08/2016. Available online at: DOI: 10.1177/00220345960750100601

Postletwaite KM. Resorption of premolar roots by ectopic canines. *British Dent J* 1989; 167: 397-398.

Power SM, Short MB. An investigation into the response of palatally displaced canines to the removal of deciduous canines and an assessment of factors contributing to favourable eruption. *Br J Orthod* 1993; 20: 217- 23.

Primosch RE. Anterior, teeth-assessment and surgical intervention in children. *Pediatr Dent* 1981; 3: 204–215.

Proffit WR. The later stages of development. In: *Contemporary Orthodontics*. St Louis, Mosby 1986: 63-94.

Proffit WR, Fields HW and Sarver DM. The later stages of development. In: *Contemporary Orthodontics*. Mosby Elsevier 2007: Pages 63-94.

Raghoobar GM, Boering G, Vissink A. Clinical, radiographic and histological characteristics of secondary retention of permanent molars. *J Dent* 1991; 19: 164-170.

Rayne J. The unerupted maxillary canine. *Dent Pract* 1969; 19:194-203.

Rimes RJ, Mitchell CNT, Willmot DR. Maxillary incisor root resorption in relation to the ectopic canine: A review of 26 patients. *Eur J Orthod* 1997; 19: 79-84.

Russell K.A., Folwarczna M.A. Mesiodens-diagnosis and management of a common supernumerary tooth. *J Can Dent Assoc* 2003; 69: 362–366. Accessed on: 12/10/2015. Available online at:<http://www.cda-adc.ca/jcda/vol-69/issue-6/362.pdf>

Rygh P, Reitan K. Changes in the supporting tissues of submerged deciduous molars with and without permanent successors. In: Transactions of the European Orthodontic Society 1963; 9: 171-184.

Sajnani AK. Permanent maxillary canines-review of eruption pattern and local etiological factors leading to impaction. J Investigative and Clinical Dentistry 2015; 6: 1-7. Accessed on: 10/01/2016. Available online at: <http://onlinelibrary.wiley.com/doi/10.1111/jicd.12067/epdf>

Sajnani AK, King NM. Early prediction of maxillary canine impaction from panoramic radiographs. Am J Orthod Dentofac Orthop 2012; 142 (1): 45-51.

Sameshima GT, Sinclair PM. Predicting and preventing root resorption: Parts I and II. Am J Orthod 2001; 119: 511-515. Part II. Accessed on: 15/09/2015. Available online at: http://www.researchgate.net/profile/Peter_Sinclair2/publication/11994349_Predicting_and_preventing_root_resorption_Part_II._Treatment_factors/links/09e4150ee4d3e2a11c000000.pdf

Schiff T, D'Ambrosio J, Glass BJ, Langlais RP and McDavid WD. Common positioning and technical errors in panoramic radiography. JADA 1986; 113: 422-426.

Schour I, Massler M. Development of human dentition. J Am Dent Association 1941; 28: 1153-1160.

Shah A, Gill DS, Tredwin C, Naini FB. Diagnosis and Management of Supernumerary Teeth. Dent Update 2008; 35: 510-520. Accessed on: 17/11/2014. Available online at: http://www.orthodontics4u.co.uk/dentist_information/supernumerary%20teeth.pdf

Shalish M, Peck S, Wasserstein A, Peck L. Increased occurrence of dental anomalies associated with infraocclusion of deciduous molars. Angle Orthod 2010; 80: 440-5. Accessed on: 23/08/2015. Available online at: <http://www.angle.org/doi/pdf/10.2319/062609-358.1>

Shapira Y, Kuftinec MM. Early diagnosis and interception of potential maxillary canine impaction. JADA. 1998; 129 (10): 1450-1454.

Smith RJ and Rapp R. A cephalometric study of the developmental relationship between primary and permanent maxillary central incisor teeth. J Dent Child 1980; 47: 36-41.

Sorensen HB, Artmann L, Larsen HJ, Kjaer I. Radiographic assessment of dental anomalies in patients with ectopic maxillary canines. Int J Paed Dent 2009; 19: 108-114.

Suri L, Gagri E, Vastardis H. Delayed tooth eruption: pathogenesis, diagnosis and treatment. A literature overview. Am J Ortho Dentofac Orthop 2004; 126: 432-445.

Svinhufvud E, Myllarniemi S, Norio R. Dominant inheritance of tooth malpositions and their association to hypodontia. Clin Genetics 1988; 34: 373-381.

Thilander B, Jakobsson SO. Local factors in impaction of maxillary canines. Acta Odontol Scand 1968; 26: 145-168.

Ul-Hamid W, Firdos T, Asad S. Co-relation between the dental age and the chronological age. *Pakistan Oral Dent J* 2004; 24 (2): 171-180. Accessed on: 10/01/2015. Available online at: http://www.podj.com.pk/PODJ/Vol.%2024%20%282%29%20%28Dec.%202004%29/24_2_171-180.pdf

Van der Linden PGM, Duterloo HS. *Development of the Human Dentition: An Atlas*. Harper and Row, New York, 1976; 75-212.

Walker L, Enciso R, Mah J. Three-dimensional localization of maxillary canines with cone-beam computed tomography. *Am J Orthod Dentofac Orthop* 2005; 128: 418-423.

Warford JH, Grandhi RK, Tira DE. Prediction of maxillary canine impaction using sectors and angular measurement. *Am J Orthod Dentofac Orthop* 2003; 124 (6): 651-655.

White SC, Pharaoh MJ. *Oral radiology: Principles and interpretation*. 6th edition. Mosby Elsevier publication, printed in China 2010; Pages 295-304.

Winter GB. Anomalies of tooth formation and eruption. In: Welbury, RR (ed). *Paed Dent* 2nd edition. Oxford medical publications 2001; 296-297.

Wellbury RR, Kilpatrick NM. History, Examination and treatment planning. In: *Paediatric Dent*. 2nd Edition. Oxford University Press, New York. 2001. Pages 37-50.

Winzar CF. Rotated anterior teeth. *Australian Dent J*. 1967; 12(5): Pages 417-420.

Wisth PJ, Thunold K, Böe OE. Frequency of hypodontia in relation to tooth size and dental arch width. *Acta Odontol Scand* 1974; 32: 201-206.

Yordanova M, Yordanova S, Tomov G. Orthodontic problems in patients with hypodontia and taurodontism of permanent molars. *Journal of IMAB-Annual Proceeding (Scientific Papers)* 2011; 17 (2): 109-113. Accessed on: 05/10/2015. Available online at: <http://www.journal-imab-bg.org/issue/2011/book2/vol17b2p109-113.pdf>

Zilberman Y, Cohen B, Becker A. Familial trends in palatal canines, anomalous lateral incisors, and related phenomena. *Eur J Orthod* 1990; 12: 135-139.



Appendix A

Codes for Data Capture Sheet

A. Radiographic Markers

1. Is maxillary lateral incisor rotation present?

Position	Code
If maxillary lateral incisor is missing	X
No Rotation	0
Right	1
Left	2
Both	3

Where X/0= Absent and 1/2/3= Present

2. Is non-resorption of the primary maxillary canines evident?

Position	Code
If dental age < 10 and non-resorption is present	N
Resorption is present	0
Right	1
Left	2
Both	3

Where N/0= Absent and 1/2/3= Present

3. What is the degree of overlap of the maxillary canine cusp tip on the root of the maxillary lateral incisor on the RHS?

Position	Code
If maxillary lateral incisor is missing	X
If dental age < 10 and overlap is present	N
No overlap	0
Distal to the pulp chamber	1
On the pulp chamber	2
Mesial to the pulp chamber	3

Where X/N/0= Absent and 1/2/3= Present

4. What is the degree of overlap of the maxillary canine cusp tip on the root of the maxillary lateral incisor on the LHS?

Position	Code
If maxillary lateral incisor is missing	X
If dental age < 10 and overlap is present	N
No Overlap	0
Distal to the pulp chamber	1
On the pulp chamber	2
Mesial to the pulp chamber	3

Where X/N/0=Absent and 1/2/3= Present

5. Is the angulation of the maxillary canines more than 30° to the mid-sagittal plane?

Position	Code
Angulation of maxillary canine is less than 30°	0
Right	1
Left	2
Both	3

Where 0= Absent and 1/2/3= Present

6. Are the maxillary canines enlarged?

Position	Code
Rotated Canine	N/A
Molar is larger in size on one side compared to the other side	T
No enlargement	0
Right	1
Left	2
Both	3

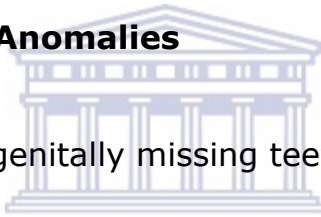Where N/A /T/0= Absent and 1/2/3= Present

7. Are the mandibular canines enlarged?

Position	Code
Rotated Canine	N/A
Molar is larger in size on one side compared to the other side	T
No enlargement	0
Right	1
Left	2
Both	3

Where N/A /T/0= Absent and 1/2/3= Present

B. Developmental Anomalies



1. Are there congenitally missing teeth on the RHS?

Tooth Involved	Code		
	YES	NO	EXTRACTED
Central	1	0	E
Lateral	1	0	E
Canine	1	0	E
Premolar	1	0	E
Molar	1	0	E

Where 0/E= Absent and 1=Present

2. Are there congenitally missing teeth on the LHS?

Tooth Involved	Code		
	YES	NO	EXTRACTED
Central	1	0	E
Lateral	1	0	E
Canine	1	0	E
Premolar	1	0	E
Molar	1	0	E

Where E/0= Absent and 1= Present

3. Is aplasia of premolars present?

Quadrant	Code	
	YES	NO
1	1	0
2	1	0
3	1	0
4	1	0

Where 0= Absent and 1= Present

4. Are peg-shaped maxillary lateral incisors present?

Position	Code
Maxillary lateral incisors are missing	N/A
No peg-shaped maxillary lateral incisors	0
Right	1
Left	2
Both	3

Where N/A /0= Absent and 1/2/3= Present

5. Is infraocclusion of the primary molars present?

Quadrant	Code		
	YES	NO	EXTRACTED
1	1	0	E
2	1	0	E
3	1	0	E
4	1	0	E

Where E/0 = Absent and 1= Present

6. Is supernumerary teeth present on the RHS?

Tooth Position	Code	
	YES	NO
Central	1	0
Lateral	1	0
Canine	1	0
Premolar	1	0
Molar	1	0

Where 0= Absent and 1= Present

7. Is supernumerary teeth present on the LHS?

Tooth Position	Code	
	YES	NO
Central	1	0
Lateral	1	0
Canine	1	0
Premolar	1	0
Molar	1	0

Where 0= Absent and 1= Present

8. Is taurodontism (not tooth specific) present?

Result	Code
No	0
Yes	1

Where 0=Absent and 1= Present

9. Is dilaceration present on the RHS?

Tooth involved	Code	
	YES	NO
Central	1	0
Lateral	1	0
Canine	1	0
Premolar	1	0
Molar	1	0

Where 0= Absent and 1= Present

10. Is dilaceration present on the LHS?

Tooth involved	Code	
	YES	NO
Central	1	0
Lateral	1	0
Canine	1	0
Premolar	1	0
Molar	1	0

Where 0= Absent and 1= Present

11. Are ectopic first molars present?

Quadrant	Code		
	YES	NO	EXTRACTED
1	1	0	E
2	1	0	E
3	1	0	E
4	1	0	E

Where E/0= Absent and 1= Present

C. Other

1. Is root resorption of the maxillary central incisors evident?

Position	Code
No root resorption is seen	0
Right	1
Left	2
Both	3

Where 0= Absent and 1/2/3= Present

2. Is root resorption of the maxillary lateral incisors evident?

Position	Code
Maxillary Lateral incisors are missing	X
No root resorption is seen	0
Right	1
Left	2
Both	3

Where X/0= Absent and 1/2/3= Present