

**A RETROSPECTIVE ANALYSIS OF THE NON-ODONTOGENIC  
MALIGNANCIES OF THE JAWS USING PANORAMIC RADIOGRAPHY**

ZARAH YAKOOB

2445710



A minithesis submitted in partial fulfilment of the requirements for the degree of  
Magister Scientiae in the Department of Maxillofacial Radiology of Dentistry,  
University of the Western Cape.

Supervisor: Prof. Mohamed Ebrahim Parker

November 2013

# **A retrospective analysis of the non-odontogenic malignancies of the jaws using panoramic radiography**

## KEYWORDS

Non-odontogenic

Malignancy

Panoramic

Mandible

Maxilla

Diagnosis

Squamous cell carcinoma

Bone invasion

Radiolucent

Trends



## ABSTRACT

**Introduction:** The oral and maxillofacial region is an anatomical site where a wide range of neoplastic conditions and lesions can occur each with varying degrees of destruction. Features seen on radiographs aid in the diagnosis and can greatly influence the treatment plan.

**Aim:** The aim of this study was to report on the frequency of and radiographic features of non-odontogenic malignancies of the jaws as seen on panoramic images, stored in the radiological archives over an eleven year period.

**Methodology:** A retrospective quantitative descriptive study design of the jaws was carried out. In each case the type of non-odontogenic malignancy, and the features of bone destruction, including anatomical site/s, the border of the lesion and the nature of the lesion, was recorded from the panoramic images. This gives an indication of the destructive potential and to some degree the extent of bone destruction these lesions may produce.

**Results:** 58 cases in total were found. There was 1 case of a malignant ameloblastoma (1,72%), 6 cases of osteosarcoma (10,34%), 1 case of chondrosarcoma (1,72%) and 50 cases of oral squamous cell carcinoma (OSCC) (86,21%). The mandibular body was the most common anatomical location where the malignant lesions occurred. 55 out of 58 (94,83%) lesions had an irregular border radiographically. 50 out of 58 (86,21%) lesions were radiolucent in nature. The year 2010 had the highest number of cases (31,03%), with no rising trends found over the ten years.

**Conclusion:** Non odontogenic malignancies presented more commonly in the jaws and oral cavity. The most common non odontogenic malignancy found at the Tygerberg Dental Hospital was the OSCC with secondary bone invasion. Although panoramic imaging is a good screening tool for bone invasion from OSCC, it may not be as accurate as CT in early cases. Imaging alone cannot be used for the detection of bone invasion, but as an adjunct to clinical factors. It can be concluded that imaging may aid in the diagnosis for primary jaw tumours such as osteosarcomas and

chondrosarcomas, however in OSCC it is more of a prognostic tool and useful in aiding in the treatment planning of the patient.

November 2013



## DECLARATION

I declare that *A retrospective analysis of the non-odontogenic malignancies of the jaws using panoramic radiography* is my own work, that it has not been submitted for any degree or examination in any other university, and that all sources I have used or quoted have been indicated and acknowledged by complete references.

Zarah Yakoob

November 2013

Signed .....



## LIST OF TABLES AND FIGURES

### **Tables**

- Table 1. Radiographic classification of malignant neoplasms (Larheim and Westerson 2006)
- Table 2. Cross-tabulation between the diagnosis and anatomical location
- Table 3. Frequency (%) of malignant lesions over a ten year period between 2002 to 2012
- Table 4. Comparison (%) between the nature and diagnosis of lesions

### **Figures**

- Figure 1. Graph indicating the frequency of cases over an eleven year period from 2002 to 2012
- Figure 2. Graph indicating the frequency of cases occurring in the jaws at different anatomical locations
- Figure 3. Pie graph indicating the percentage of lesions occurring in each year from 2002 to 2012
- Figure 4. Bar graph indicating the number of cases occurring in the right maxillary region for the year 2010 and the remaining years combined
- Figure 5. Pie graph representing the percentages of osteosarcomas vs. OSCC that had a mixed radiographic appearance
- Figure 6. Malignant ameloblastoma of the mandible
- Figure 7. OSCC with bone invasion in the anterior mandible
- Figure 8. Osteosarcoma of the left angle of the mandible (superior border) with a radiolucent appearance
- Figure 9. Osteosarcoma of the left maxilla with the classic mixed radiographic appearance
- Figure 10. OSCC with an unusual regular well demarcated border in the left mandibular body
- Figure 11. Extensive bone invasion to the mandible from the buccal mucosa

## CONTENTS

Title Page	
Keywords	i
Abstract	ii
Declaration	iv
List of tables and illustrations	v
1. INTRODUCTION	1
2. LITERATURE REVIEW	2
2.1 Diagnostic imaging and its importance	2
2.2 Panoramic radiography as a diagnostic tool	2
3. AIMS AND OBJECTIVES	7
4. MATERIALS AND METHODS	8
4.1 Study design	8
4.2 Study population	8
4.3 Data collection	9
4.5 Data processing and analysis	9
5. RESULTS	11
6. DISCUSSION	17
6.1 Frequency	17
6.2 Anatomical location	19
6.3 Borders and nature of lesions	21
6.4 Trends over the ten year period	27
6.5 Limitation and future recommendations	27



7.	CONCLUSION	29
8.	REFERENCES	30
9.	APPENDICES	
	9.1. Ethics approval form	34
	9.2. Data collection spreadsheet	35
	9.3. Key for data collection	36





## 1. INTRODUCTION

The oral and maxillofacial region is an anatomical site where a wide range of neoplastic conditions and lesions can occur each with varying degrees of destructive potential. This site includes the jaws, oral cavity and the associated soft tissues. Tumours of the jaws and in particular the mandible are generally more common than those occurring in the mid facial region (Riaz and Warriach 2011). Jaw tumours can broadly be classified originating either from odontogenic or non-odontogenic sources. These can be further divided into benign and malignant lesions. Features seen on radiographs aid in the diagnosis and may have a bearing on the treatment plan. The focus of this study was on malignant non-odontogenic tumours affecting the jaws.



## 2. LITERATURE REVIEW

### 2.1 Diagnostic imaging and its importance

Early detection and diagnosis of any malignancy is a vital part of the prognosis of the patient as it may be curable. Making a precise diagnosis on a radiograph can be challenging, as many tumours share a similar clinical and radiographic appearance. The clinical history, physical examination and laboratory findings, together with diagnostic imaging all aid in formulating a diagnosis. Diagnostic imaging does not always provide an exact diagnosis, but it may point to working diagnosis as well as aid in the surgical intervention needs (Dunfee *et al.* 2006). Correct interpretation of diagnostic images is important, as it may strongly support a final diagnosis and subsequently aids in the management of the patient (Theodorou *et al.* 2003). More often than not, malignant neoplastic lesions have some degree of bone invasion and radiography plays an important role in assessing the extent thereof (Lloyd and McHugh 2010).

### 2.2 Panoramic radiography as a diagnostic tool

Although advanced diagnostic imaging techniques, such as computed tomography, cone beam tomography and magnetic resonance imaging can provide additional important diagnostic information regarding tumours, routine radiography is still employed as the fundamental and initial assessment for any suspected pathology in the orofacial region in most parts of the world, especially in Africa. With regards to the jaws and in particular the mandible, panoramic radiography is still a popular and valuable diagnostic tool used in dentistry today (Choi, W.J. 2011). Since its introduction to dentistry, panoramic radiography provided a simple and readily available extra-oral procedure where the entire maxilla and mandible can be seen on a single film. On this single film the jaws, maxillary sinuses, the full dentition, the temporomandibular joints and adjacent structures can be seen as a two dimensional view.

Kurubayashi and Sasaki (2003) carried out a study in Tokyo, comparing panoramic radiography and computed tomography as tools for assessing the dimensions of

radiolucent lesions in the jaws. They concluded that panoramic radiography is more accurate for those lesions with well-defined margins and that computed tomography showed more detail in those lesions with invasive and infiltrative features, with special reference to the oral squamous cell carcinoma (OSCC). Although this may hold true, advanced imaging is not routinely performed and often not the initial choice of imaging, as with panoramic radiography. Panoramic radiography is also more affordable and requires less radiation when compared to medical CT. Therefore advanced imaging should only supplement the initial radiographic evaluation where necessary, and it is then imperative to give a detailed description of all pathology seen in the entire field of view, especially when a malignant lesion is suspected.

Another study in Japan (Nakayama, E. 2009) compared different imaging techniques and the accuracy thereof for the inferior and superior extent of bone invasion, with particular reference to carcinomas of the mandible. They concluded that the diagnostic value of panoramic radiography is equivalent to that of computed tomography when detecting bone invasion into the mandibular canal and that panoramic radiography is more readily available and more economical. Hence the present study is to be carried out using panoramic radiography as it is the initial imaging modality of choice at the University of the Western Cape in providing diagnostic information at an affordable cost for the attending patients.

Non-odontogenic tumours can be defined as those tumours where the cellular composition does not form dental tissues, teeth or tooth-like structures. These tumours may however affect adjacent teeth secondarily, due to the close proximity of teeth in the jaws (Theodorou *et al.* 2003). There are numerous classification systems available with regards to malignant neoplasms of the jaws, most of them being based on the histopathology of the lesions.

Larheim and Westesson (2006) radiographically classified malignant neoplasm as those causing bone destruction and those causing bone deposition, as this is the principle difference seen on radiographs. Their classification is presented in Table 1. Unlike the benign variants, malignant neoplasms of the jaws are relatively uncommon in most parts of the world. Oral cancer and cancer of the oropharynx is the sixth most common malignancy worldwide and are more common than primary central bone malignancies. Squamous cell carcinoma accounts for one of the most common

malignant lesions of the jaws, although there is some geographical variation in this, ranging from 1-2% in Europe to 50% in India (Subhashraj *et al.* 2009).

Table 1. Radiographic classification of malignant neoplasms (Larheim and Westesson 2006).

CLASSIFICATION: NON-ODONTOGENIC MALIGNANT NEOPLASMS	
<u>Bone destructive Tumours</u>	<u>Bone destructive and bone forming tumours</u>
Squamous cell carcinoma	Osteosarcoma
Non-Hodgkin's lymphoma	Chondrosarcoma
Multiple myeloma	Ewing's sarcoma
Leukaemia	

Malignant jaw tumours can either be central or secondary jaw lesions. The central types are those tumours that originate from the jaw bone itself and secondary tumours are those that originate from the oral cavity and affect the jawbone secondarily by infiltration. The latter is usually the case with oral squamous cell carcinomas and metastases from other parts of the body. There is a variant of squamous cell carcinoma known as the primary intra-osseous squamous cell carcinoma. Rare in occurrence, this malignancy is generally believed to originate from odontogenic origin (Lin *et al.* 2005). Despite any infrequent occurrence, correct diagnosis of any malignant lesion has serious prognostic implications. Often these lesions present with clinical signs that are highly suggestive of intrabony malignant lesions. Common clinical signs that may be present are pain, loose teeth, paraesthesia, and rapidly growing swellings of the face. Often only one of these clinical signs may be present at the time of diagnosis. Radiographically, malignant lesions of the jaws typically present as an ill-defined radiolucency. However, the radiographic appearances of malignancies vary even within malignancies of similar origin. Factors to consider when looking at a radiograph of a suspected malignant lesion include, the location of the lesion, pattern of bone destruction, bony expansion, periosteal reactions, and the association with adjacent structures and whether there is any soft tissue involvement

(Theodorou *et al.* 2003). A thorough analysis of any or all of these characteristics may aid in the differentiation of one lesion from one another.

Oral cancer in particular is a serious and continuously growing problem and together with oropharyngeal cancer makes up the sixth most common type of cancer worldwide (Warnakulasuriya, 2009).

The most common non-odontogenic malignant neoplasm reported in Africa is the squamous cell carcinoma (Kushraj *et al.* 2011). Squamous cell carcinoma is defined as a malignant epithelial neoplasm exhibiting squamous differentiation as characterized by formation of keratin and/or presence of intercellular bridges and intercellular keratin fibres. The degree of bone destruction is directly related to the extent of bone invasion from the adjacent soft tissue. The radiographic presentation is highly beneficial in that it will guide the surgeon to determine the amount of bone removal that is needed for the treatment of such a malignant lesion.

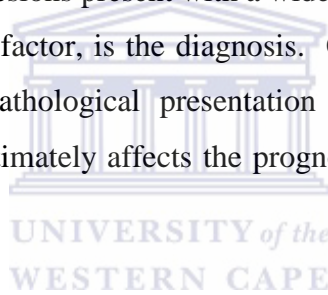
A study done in Tanzania and Uganda analysed the prevalence of oral maxillofacial neoplastic lesions, and found that malignant neoplasms dominated with a prevalence of 67.28% (Kamulegeya and Kalyanyama 2008). This figure is high compared to other parts of the worlds. However, Kaposi's sarcoma constituted 32.64% of the total percentage, which has a strong association with HIV. HIV has a higher prevalence in Africa when compared to the USA and Europe, and for this reason the results of this study could be influenced by these factors. The study population used for this study encompassed both benign and malignant lesions in their inclusion criteria. In this study the jaws as well as associated soft tissues were analysed for sites of frequency.

Another study carried out in Nigeria, analysed the pattern of malignancies seen in the head and neck region (Amusa *et al.* 2004). They found the greatest percentage of malignant neoplasms originated in the oral cavity of which 84,3% of those lesions where from the jaws. Burkitt's lymphoma showed the highest percentage overall and squamous cell carcinoma predominated in the older age group of the sample population. Similar results were obtained in other studies from the African continent. Their study population of 313 was large, as not only the jaws were analysed, but rather the entire maxillofacial region.

In the USA, Theodorou *et al.* (2003) carried out a study that reviewed the literature regarding the radiographic presentation of both benign and malignant non-odontogenic tumours. They used both computed tomography and panoramic radiography as a diagnostic medium, but they emphasised the importance of correctly interpreting the initial imaging evaluation using panoramic radiography.

Whilst there is extensive literature available with regards to the prevalence of non-odontogenic and odontogenic neoplasm's of the head and neck in Europe and Asia, very few studies used the radiographic records as part of their methods for their studies. This is a key element in the diagnosis and treatment planning these lesions, and therefore more research in this field is required.

Non-odontogenic malignant lesions present with a wide variety of characteristics. One of, if not the most important factor, is the diagnosis. Clinical features together with the radiographic and histopathological presentation all guide the clinician to a definitive diagnosis. This ultimately affects the prognosis as it guides the necessary treatment plan.



Whilst there are numerous studies that have been carried out world wide on the prevalence of malignant jaw lesions, few have been done which focuses on the radiographic appearance, particularly with regard to non-odontogenic malignant lesions within the jaw bones and oral cavity. To my knowledge no such study has been carried out in the Western Cape or South Africa, and therefore this geographical area required further investigation.

### **3. AIMS AND OBJECTIVES**


#### **Aim**

The aim of this study was to report on the frequency and radiographic features seen in non-odontogenic malignancies of the jaws as seen on the panoramic images stored in the archives of the Faculty of Dentistry, Tygerberg over a eleven year period.

#### **Objectives**

To determine:

- the frequency of the different types of non-odontogenic malignancies over the ten year period.
- the frequency of the various types of non-odontogenic malignancies per annum.
- the features and patterns of bone destruction present in each case.



## 4. MATERIALS AND METHODS

### 4.1 Study Design

This was a retrospective quantitative descriptive study of the jaws designed to study the radiographic features of non-odontogenic malignancies during the period of January 2002 to December 2012.

### 4.2 Study population

The study population for this study was drawn manually by selecting the radiographs from the records of patients that have already been diagnosed and confirmed by histopathological and clinical findings prior to the commencement of this study. The radiographs that were studied were obtained from the radiology archives in the department of diagnostics and radiology at the Dental Faculty of the University of the Western Cape, Tygerberg.

#### Inclusion Criteria

- Patients with a histologically confirmed diagnosis of a malignancy classified as a tumour arising from non-odontogenic tissue.
- Recorded the radiological involvement of the mandible or maxilla where present.
- Non-odontogenic malignancies of both primary or secondary origin as recorded in the oral cavity.
- Odontogenic malignancy was considered if less than three in frequency.

#### Exclusion Criteria

- Those diagnoses that was inconclusive, either due to an inadequate biopsy specimen or insufficient clinical data.
- Any non-odontogenic malignant lesion that arose in the nose, paranasal sinuses, orbits, salivary glands, lymph nodes and bone marrow.
- Malignant lesions seen on any radiograph other than a panoramic radiograph.
- A panoramic radiograph with poor or insufficient diagnostic quality.



#### 4.3 Data Collection

All data collected was recorded and captured on a Microsoft Excel 2011® spreadsheet. (Appendix 2) The data spreadsheet was based on the objectives set out for this study.

The type of non-odontogenic malignancy, and the features of bone destruction, including anatomical site/s, the border of the lesion and the nature of the lesion were recorded for each case. This gave an indication of the destructive potential and to some degree the extent of bone destruction these lesions produced.

#### 4.4 Data Processing and analysis

Only panoramic radiographs stored in patient's records were used for data analysis. All radiographs used in this study were viewed on a light-reflecting radiograph viewing box in an enclosed room with no light entry. This was done to standardise the setting for analysing the radiographs.

All the data that was collected was entered onto a Microsoft Excel 2011® spreadsheet. Each case was numbered on the spreadsheet, with a corresponding number on the radiograph itself. Each selected patient record had a folder number to which an individual record number was allocated. This index data set was kept separate and used to ensure confidentiality as well as a cross-reference for the researcher.

The diagnoses of each lesion was recorded on the spreadsheet. In lesions with bony changes, the anatomical locations within the maxilla and mandible were recorded. For the purpose of this study the study area was divided into categories, namely: (i) anterior mandible extending from the 33 to 43 regions, and when no teeth are present the anterior region was recorded as the area between the two mental foramina; (ii) the mandibular body region, extending from the canine region to the angle of the mandible, for both left and right. In the maxilla, the categories were divided into left and right maxilla. The third variable that was recorded was the border of the lesion, being either regular or irregular. The fourth variable recorded was the nature of the lesion, whether there was bone destruction or deposition. (Appendix 3)

The statistical programme used to analyse the data was the Epi Info®. All variables were analysed to calculate the relative frequency of the different types on non-odontogenic malignancies, the relative frequency of features seen on the radiographs and the incidence of the malignancies for each of the eleven years.

### Limitations

The limitation of this study was that, as this was a retrospective study, there could be no standardisation of the radiographic quality, as different panoramic machines were used with a variation of radiation exposure factors for each case at the time the radiographs were taken.

### Ethical Consideration

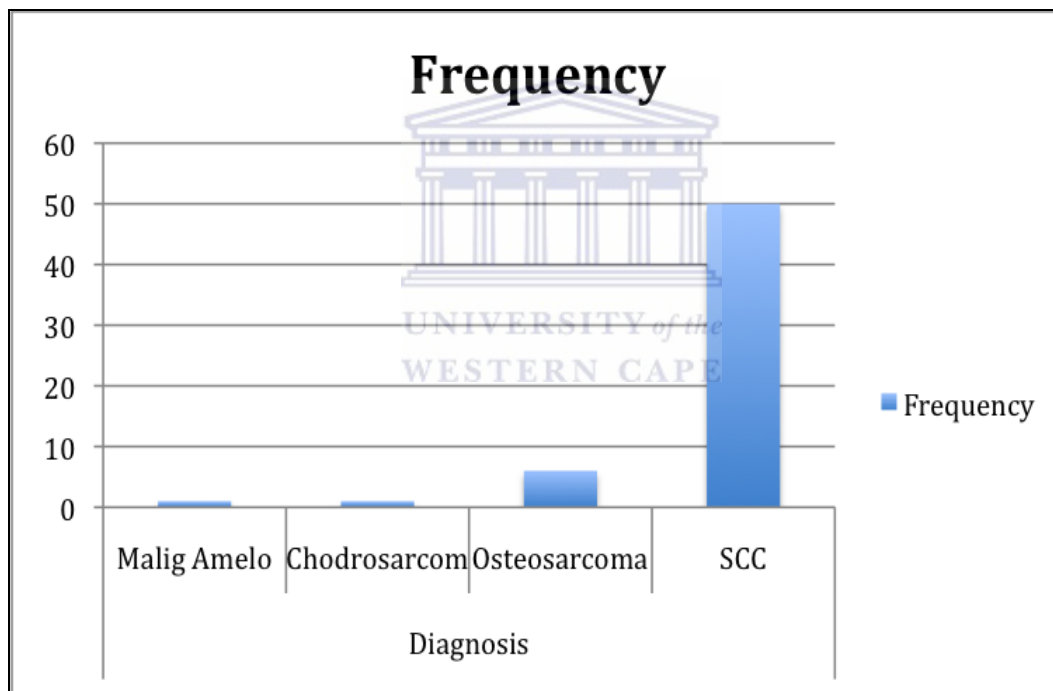
As this was a retrospective study, there was no direct contact with any of the patients. Only the records and radiographs were used in this study, no names or personal details were used. Patient confidentiality was maintained by the creation of an index data set that linked the patient folder number to the allocated record number. This research proposal was submitted to the Dental Faculty and Senate Research Ethics Committee of the University Western Cape and was subsequently approved (Appendix 1).

## 5. RESULTS

In this study, 58 cases were obtained that met the inclusion criteria for the study. Only one case of an odontogenic malignancy was found and was added to the data set to determine the epidemiology of jaw malignancies that presented in this study population.

Of the 58 cases, there were 6 cases of osteosarcomas, 1 chondrosarcoma, 50 squamous cell carcinoma (SCC), and 1 primary malignant ameloblastoma. (Fig. 1) The percentage values were 10,34% for osteosarcoma, 1,72% for chondrosarcoma, 86,21% for SCC and 1,72% for primary malignant ameloblastoma.

Figure 1. Graph indicating the frequency of cases over an eleven year period

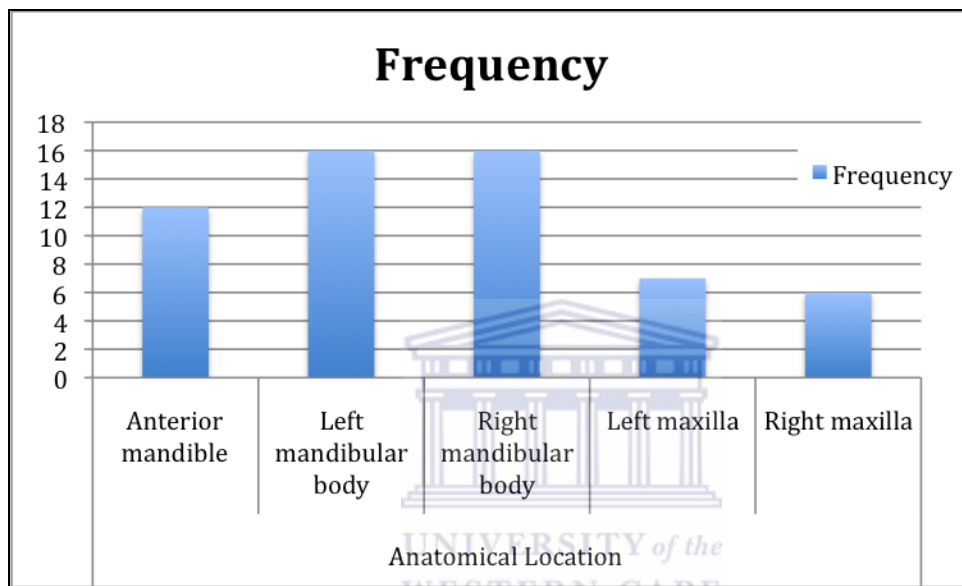


Of the 58 cases, only one case showed no bone change. The diagnosis for this case with no bone change was SCC. Thus the overall percentage of bone changes in the study population was 98,28%.

When the location of lesions were analysed, one case presented with no bone change. With regards to the remaining 57 cases, 12 presented in the mandibular anterior

region, 16 in the left mandibular body, 16 in the right mandibular body, 7 in the left maxilla and 6 in the right maxilla. (Fig. 2) The percentages were 20,69%, 27,59%, 27,59%, 12,07% and 10,34% respectively.

Figure 2. Graph indicating the frequency of cases occurring in the jaws at different anatomical locations



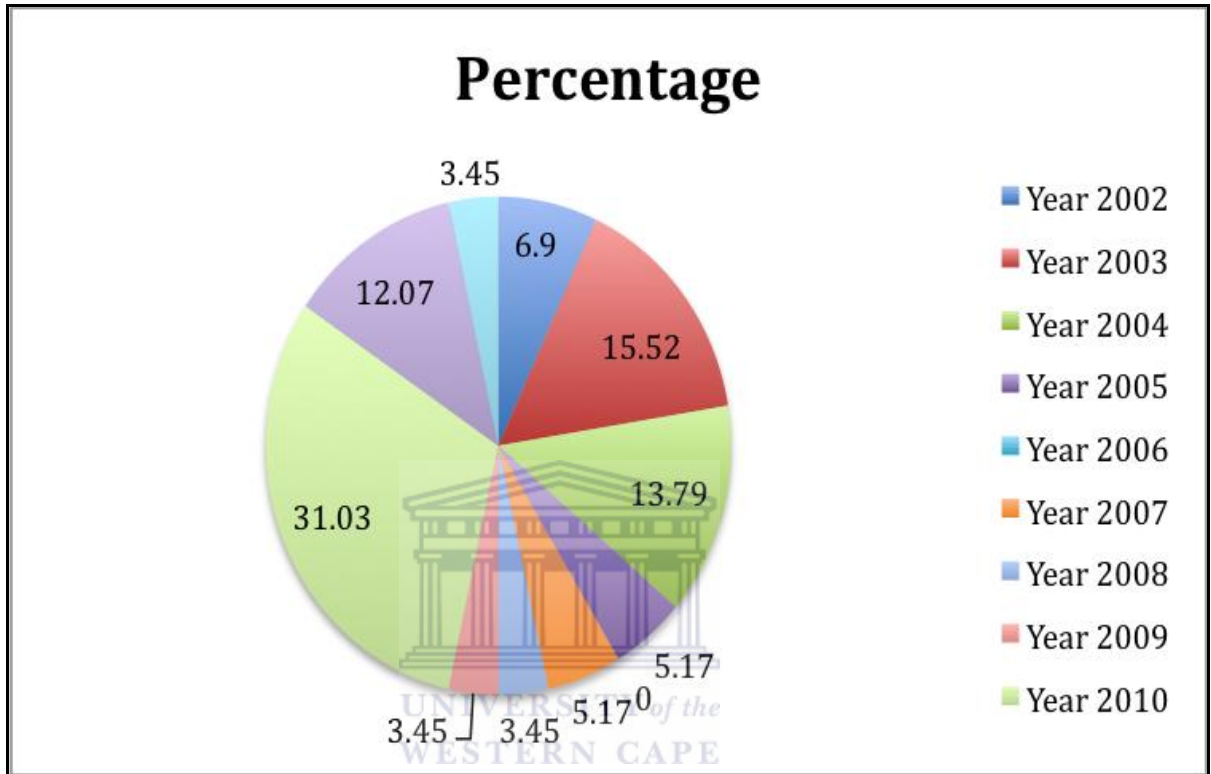
55 of the 58 cases had a lesion with an irregular border and 3 cases had lesions with regular borders. This gave a percentage of 94,83% of the lesions with irregular borders and 5,17% of lesions having regular borders.

When analysing the nature and content of the lesions, 50 cases were radiolucent, 7 cases were of a mixed radiolucent and radiopaque nature and only one case had showed no radiographic evidence of pathological change. This gave a percentage of 86,21%, 12,07% and 1,72% respectively.

When analysing the frequency of cases over the eleven year period 2002 showed 4 cases, 2003 had 9 cases, 2004 had 8 cases, 2005 had 3 cases, 2006 had no cases, 2007 had 3 cases, 2008 had 2 cases, 2009 had 2 cases, 2010 had 18 cases, 2011 had 7 cases and 2012 had 2 cases. (Table 3) The percentages for the frequency of cases over the

eleven year period in order is 6,90%, 15,52%, 13,79%, 5,17%, 0%, 5,17%, 3,45%, 3,45%, 31,03%, 12,07% and 3,45% respectively. (Fig. 3)

Figure 3. Pie graph indicating the percentage of lesions occurring in each year from 2002 to 2012.



In a cross-tabulation of diagnosis of lesions and the anatomical location in which they appeared, the Fisher exact test showed no statistically significance between the association as p-value 0; 767. (Table 2)

Table 2. Cross-tabulation between diagnosis and anatomical location

Diagnosis	Location				
	Mand Ant	Mand left	Mand right	Max left	Max right
Malignant ameloblastoma	0	1	0	0	0
Chondrosarcoma	0	0	1	0	0
Osteosarcoma	0	3	2	1	0
SCC	12	12	13	6	6

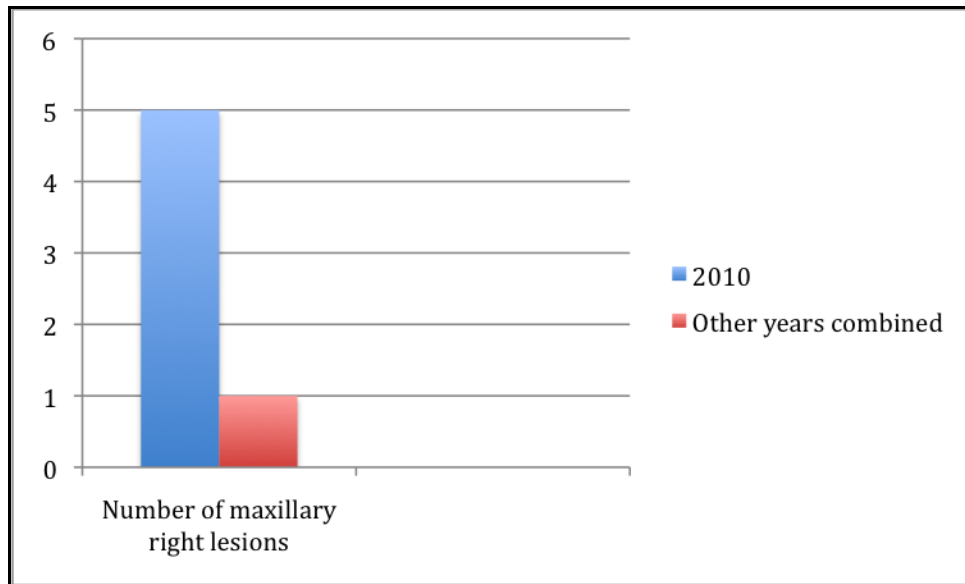
There is evidence of a statistically significant difference between the year 2010 and the other years.

Table 3. Frequency (%) of malignant lesions over a ten period between 2002 to 2012

%	Year										
	2002	2003	2004	2005	2006	2007	2008	2009	2010	2011	2012
	6,90	15,52	13,79	5,17	0	5,17	3,45	3,45	31,03	12,07	3,45

A cross-tabulation between malignancies occurring in the year 2010 and the anatomical location, proved to be statistically significant, with the Fisher p-value = 0,051. There were a high proportion of lesions occurring in 2010 that presented in the right maxilla. The proportion is  $5/8=0,278$  and for the rest of the years it was  $1/40=0,025$  and thus considerably smaller. (Fig. 4)

Figure 4. Bar graph indicating the number of cases that occurred in the right maxillary region for the year 2010 and the remaining years combined

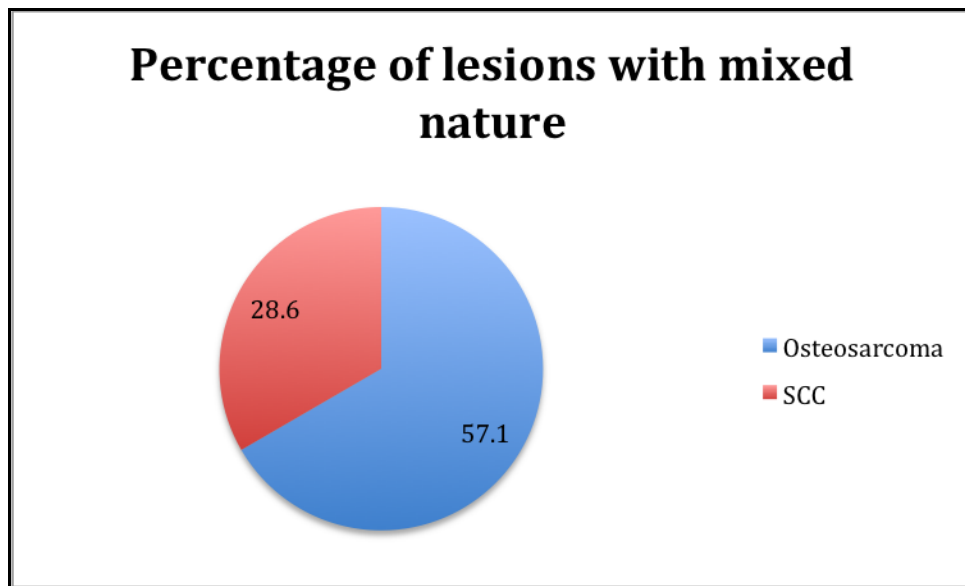


When cross-tabulations were done between the diagnosis of lesions and the nature and content of the lesions, statistically significant evidence was shown. The percentages of osteosarcomas versus SCC, when comparing the nature of the lesions are considerably different. (Table 4) The osteosarcomas presented with a higher percentage with mixed lesions (57,1%) , than SCC (28,6%). (Fig. 5) The percentage of radiolucent lesions is highest with SCC and this attributed to its high frequency.

Table 4. Comparison between radiographic changes and diagnoses of lesions

Nature of lesion	Diagnosis			
	Malignant ameloblastoma	Chondrosarcoma	Osteosarcoma	SCC
Radiolucent	2%	0%	4%	94%
Mixed	0%	14,3%	57,1%	28,6%
Normal	0%	0%	0%	100%

Figure 5. Pie graph representing the percentages of osteosarcomas vs OSCC that had a mixed radiographic appearance





## 6. DISCUSSION

The oral and maxillofacial region, with particular reference to the jaw bones are complex anatomical locations where numerous neoplastic conditions may arise. These tumours have a predilection for the entire facial region although odontogenic tumours tend to affect the mandible and maxilla more. A vast variety of disease processes affect these sites and determining a working diagnosis may be challenging to both the radiologist and the clinician. Today in modern medicine, although advanced imaging can greatly improve the diagnostic accuracy and treatment outcomes, routine conventional imaging still remains as the initial assessment tool for suspected pathology of the jaws. This holds particularly true in developing countries such as South Africa. When viewing radiographs it is important to recognize, to accurately identify the extent and the imaging features as well as to locate the anatomical regions involved. These factors can greatly influence the prognosis of the patient, as it aids in the treatment planning.

Tumours of the jaw bones are broadly classified based on their origin, as either odontogenic or non-odontogenic tumours (WHO). In malignant jaw lesions the non-odontogenic types predominate, as compared to the odontogenic types.

### 6.1 Frequency

Squamous cell carcinomas account for approximately 90% to 94% of malignant tumours of the oral cavity. Other types of malignant lesions, including melanoma, carcinomas of the salivary glands, sarcomas of soft and hard connective tissues, and metastatic cancers, are also encountered, although less commonly (Daley and Darling 2003). Worldwide, oral cancer is the 8<sup>th</sup> most common cancer. The frequency of SCC differs greatly between continents and they occur more frequently in South East Asia and Africa. This is due to a number of predisposing factors such as smoking, high alcohol consumption, betel nut chewing habit and the effects of the human papilloma virus.

In a five year study Riaz and Warriach (2011) studied tumours of the oro-facial region and found that malignant lesions from secondary origin predominated with 69% of cases being diagnosed as SCC. This is consistent with this study as SCC also

dominated. However this could be due to the fact that in this study metastases and malignancies where the primary origin from lymph nodes and bone marrow was excluded. (Riaz and Warriach 2011)

In a retrospective study of oral maxillofacial neoplasm's in East Africa over 10 years, Kamulegeya and Kalyanyama (2008) found that SCC was the third most common neoplasm overall. They found that Kaposi Sarcomas and Burkitts lymphoma were the most common neoplasms respectively. These findings differ to this study as well as other studies, as SCC usually predominated (Kamulegeya and Kalyanyama 2008). Another study in Nigeria by Amusa *et al.* in 2004 produced similar results in that Burkitts lymphoma was noted to be the most common tumour (70,1%). The second most common tumour was SCC (10,3%). Although this percentage is significantly less than the 86,21% seen in this study, the Nigerian study did not include malignancies of lymph node origin (Amusa *et al.* 2004). This may also largely be due to the high HIV and Epstein Barr virus incidence of the patients involved in the studies in Nigeria and elsewhere in Africa.

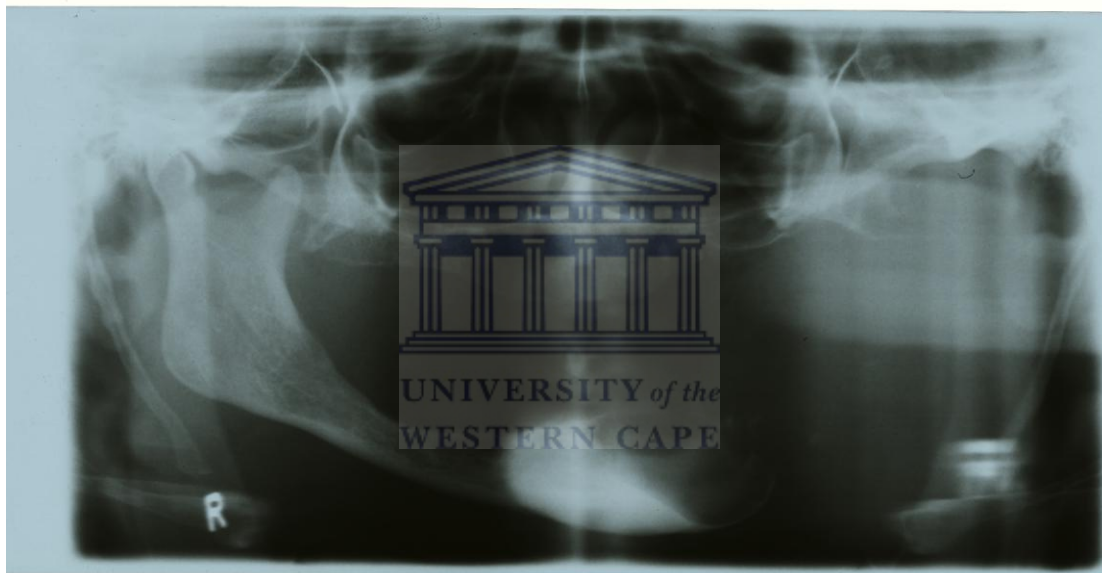
The present study also compared well to another epidemiological study of oral and perioral cancers in Isfahan, in that SCC's presented as the most common malignant neoplasm (62% of cases). Although SCC was the most common neoplasm, it is lower to the 86,21% seen in this study. This is due to the fact that the study in Isfahan included a broader category of lesions into their study (Razani and Sajadi 2007).

Another study in Libya is also consistent with this study as the research reported SCC to constitute 82% of cases, in their version of reviewing malignant neoplasms of the oro-facial region (Subhashraj *et al.* 2009).

Osteosarcoma is classified as a malignant primary bone tumour. It is seen as the most common primary sarcoma of the jaw bones, but occurs in less than 5% in the rest of the skeleton. On the other hand, chondrosarcomas are also primary sarcomas and although they rarely occur in the jawbones, they are said to be the most common malignant neoplasm of skeletal tissue (Theodorou *et al.* 2003). The findings of this study is consistent with that of Theodorou *et al.*, as after SCC, osteosarcoma was the most common (10,34%) with only one case of chondrosarcoma (1.72%).

The benign ameloblastoma commonly occurs in the black population of South African population, however the malignant transformation to ameloblastic carcinoma is rare (Dunfee *et al.* 2006). In this study only one case out of 58 cases was a primary malignant ameloblastoma. This case was histologically confirmed as a ameloblastic carcinoma. This particular case of malignant ameloblastoma showed extensive bone destruction (Figure 6).

Figure 6. Malignant ameloblastoma of the mandible, ramus, condylar head and coronoid process

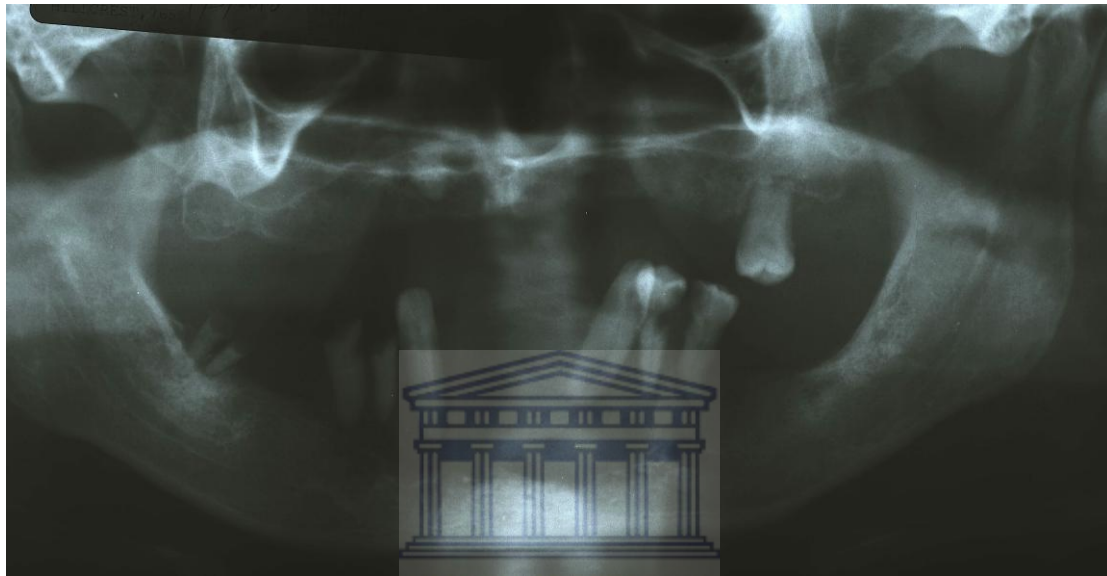


## 6.2 Location

Previous studies have shown that the osteosarcoma of the jaws occurred more frequently in the mandible than the maxilla (Bianchi and Boccardi 1999). Similarly in this study 5 out of 6 cases presented in the anatomical location designated as the mandibular body. No lesions presented in the anterior mandible and only one case was found in the maxilla. In a 30 year retrospective study of osteosarcoma of the jaws, their results found 25 cases and of those, 8 lesions were found in the maxilla and 17 in the mandible. Although similar findings regarding the most prevalent site was the mandible, the previously mentioned study by Bennet included a larger study

sample, whereas this study only included 6 cases (Bennet et al. 2000). In an 8 year study by Bianchi and Boccardi (1999) the radiological aspects of osteosarcoma, 9 cases were found, of these 5 were located within the mandible. This study corroborated the findings of Bianchi and Boccardi. Figure 7 shows a case of OSCC in the anterior mandible. (Figure7)

Figure 7. OSCC with bone invasion in the anterior mandible



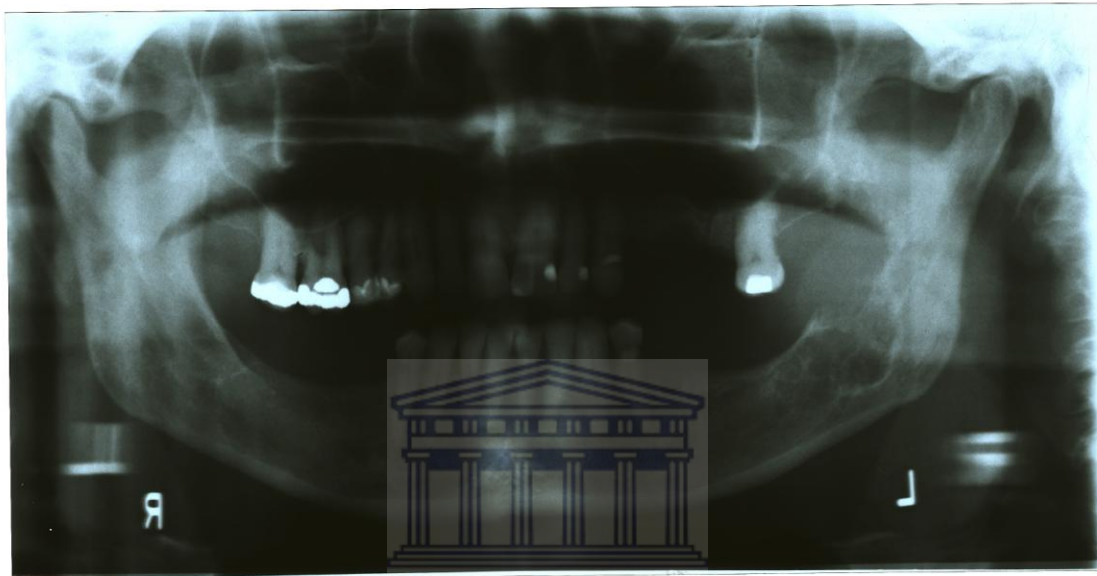
Many factors such as patient and tumour related factors might influence the prognosis and treatment planning of OSCC. It has been reported that the anatomical site of the tumour as well as the vascular and lymphatic network surrounding the tumour is thought to be cardinal in the prognosis of these tumours. Studies have shown that SCC found at the base of the tongue has increased metastatic rate, as compared to SCC of the lip (Mossano *et al.* 2006). The anatomical sites reported to be most commonly associated with OSCC is the tongue, floor of the mouth and the buccal mucosa (Razavi and Sajadi 2007). This was also found in a ten year retrospective study in an East-African population by Kamulegya and Kalyanyama (2008). They found more cases of SCC in the mandible than in the maxilla. (Kamulegya and Kalyanyama 2008) This finding is consistent with this study where 37 cases of SCC were found in the mandible and only 12 in the maxilla. One case of SCC had no particular anatomical radiographic site as there was no secondary bone invasion at the time the radiograph was taken.

However, the anatomical sites reviewed in the present study were radiographic anatomical locations and not the primary site within the oral cavity. The radiographic anatomical site is due to bone invasion from the tumour to the adjacent bone surface, and may be from SCC in the gingivolabial sulcus, floor of the mouth or buccal surface.

### 6.3 Borders and nature of the lesions

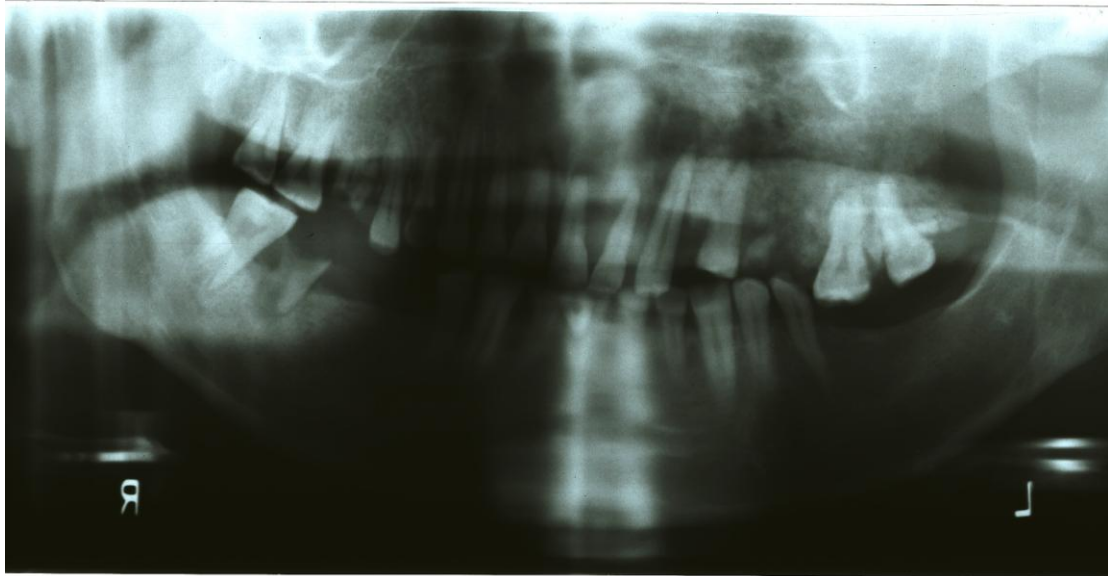
The radiographic presentation of osteosarcoma is important as the usual clinical symptoms of pain, swelling, paraesthesia, swelling and loose teeth are non specific. Although conventional radiography is an essential tool, it has been reported that it should be supplemented by computed tomography (Bianchi and Boccardi 1999). A study by Ojo and Nortje in 2001 carried out a study that compared the radiographic findings of osteosarcomas of the mandible, using conventional panoramic radiography, computed tomography (CT) and magnetic resonance imaging (MRI). Their findings showed that although panoramic radiography is a good diagnostic tool, Ct and MRI better evaluates the extent and tumour ossification in soft tissue. (Ojo and Nortje 2001) It is well documented that malignant lesions seen on a radiograph, do not have a well defined border, but rather an irregular border of bone destruction, bone deposition or a combination of both (Petrikowski *et al.* 1995). One of the earliest radiographic signs of an osteosarcoma is localised widening of the periodontal ligament and enlargement of the mandibular canal. In advanced cases there were poorly defined areas of bone destruction and bone deposition (Theodorou *et al.* 2003). This study did not depict any cases of widening of the periodontal ligament as all the lesions were already advanced at the time the radiographs were taken. In this study, all of the 6 cases had an irregular border that was ill defined which is consistent with findings in other studies. A study by August *et al.* (1997) found 30 cases of osteosarcoma of the jaws in which 11 of those lesions showed irregular bone destruction, 5 lesions showed a mixed radiolucent and radiopaque appearance and only 3 lesions showing only radiopaque bone deposition appearance (August *et al.* 1997). The latter findings differ slightly from this study in that 4 of the 6 lesions had a mixed radiopaque and radiolucent radiographic appearance (Figure 8). The remaining 2 lesions showed only radiolucent bone destruction (Figure 9). Previous authors have reported that the radiographic presentation of the osteosarcoma and other

cemento-osseous benign neoplasms may show similar pattern of mixed bone destruction and deposition (Nakayama *et al.* 2005). Radiographic assessment should not be the only tool used for diagnosis but should be supplemented by histopathology. Figure 8. Osteosarcoma of the left angle of the mandible (superior border) with a radiolucent appearance



UNIVERSITY of the  
WESTERN CAPE

Figure 9. Osteosarcoma of the left maxilla posteriorly with the classic mixed radiographic appearance



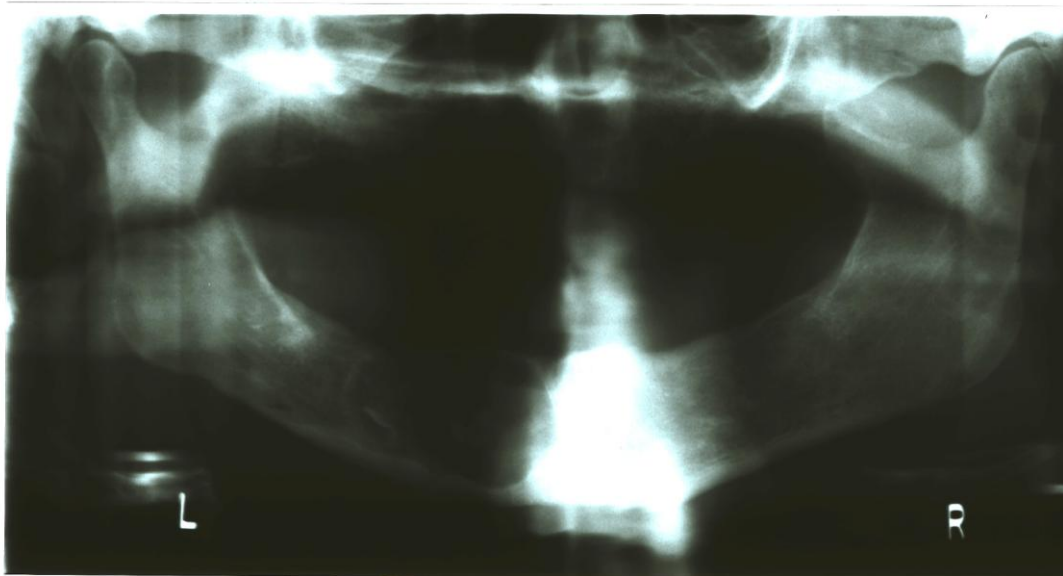
Chondrosarcomas of the jaws have a similar radiographic appearance to osteosarcomas. However the behaviour differs to the osteosarcoma in that the chondrosarcomas are slow growing and tend to displace their surrounding structures before invading them. Both chondrosarcomas and osteosarcomas show varying degrees of matrix calcification. In this study only one case of a chondrosarcoma was found. This finding was comparable to these of previous studies as it displayed a mixed internal structure radiographically (Gadwal *et al.* 2000). However this case of chondrosarcoma did not present with the usual irregular border but rather a regular border. It has been reported that the radiographic appearance of chondrosarcoma, osteosarcomas, fibrous dysplasia and ossifying fibroma may have similar features due to the radiopaque component. Computed tomography may therefore be useful in determining the degree of matrix calcification in cross section, when ever panoramic radiography is unable to do so.

A number of predisposing factors can determine patient survival as well as the treatment of choice. The more commonly used prognostic factor is the TNM classification, where tumour size, lymph node involvement and presence of metastases is used for cancer staging. Several studies, although not clear, suggest that the thickness of the tumour also plays a role, in that a thicker tumour size increase the rate of regional disease. In this study the patient's clinical history as well as tumour stage was unknown. Other than clinical and histopathological findings, the presence

and extent of bone invasion is also an important factor in treatment planning and prognosis and survival. The detection of bony invasion of SCC can be challenging, particularly in the early stages. In the 50 cases of SCC found in this study, 49 showed bone invasion as seen on the panoramic image. Only one case revealed normal bone with no bone invasion or bone change. One case did show bone invasion by the tumour but in an unusual regular fashion of bone destruction (Figure 10). The reports in the literature regarding the frequency of bone invasion of SCC are inconsistent and range from 22-100%. This is due to the different study samples and disease stages of various studies. It has been reported that the initial subtle changes seen in the bone are difficult to detect on panoramic imaging due to the fact that 30-60% density change is required to detect bone pathology. In such cases computed tomography (CT) or single photon emission computed tomography (SPECT) should be the imaging modality of choice as they are more accurate in detecting bone change (Genden *et al.* 2010). Bolzoni *et al.* (2004) carried out a study to determine the diagnostic accuracy of MRI for bone invasion by SCC and reported MRI to be superior to CT for the evaluation of soft tissue and in dentate patients with metal restorations that causes beam hardening (Bolzoni *et al.* 2004). Kushraj *et al.* (2011) compared the efficiency between panoramic radiographs, CT and SPECT in the detection of bone invasion in oral cancer. Their results showed that the panoramic radiography and CT not only showed acceptable levels of sensitivity but very good specificity as well (Kushraj *et al.* 2011).

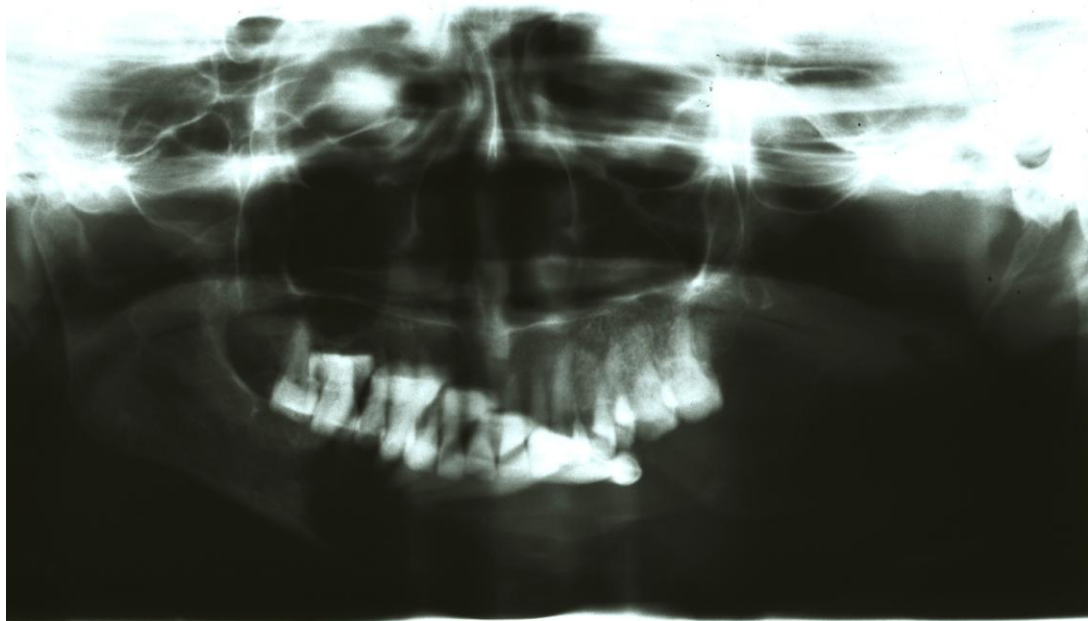
Figure 10. OSCC with an unusual regular well demarcated border in the left mandibular body.





OSCC of the buccal mucosa may spread to and invade the palate, parotid duct and masseter muscle. In these cases, MRI is ideal due to the soft tissue detail it offers particularly for the masseter muscle. (Figure 11 shows a case of OSCC from the buccal mucosa with extensive bone invasion into the mandible, ramus, condyle and coronoid process. Pre-operative imaging is necessary to detect if there is any invasion into the maxillary sinus, palatal bone and nasal vault for OSCC that presents in the maxilla or hard palate. Large OSCC lesions of the hard palate may spread via the palatine or trigeminal neurovascular bundle. It is reported that CT offers high resolution images to assess the spread in these regions (Bolzoni *et al.* 2004).

Figure 11. Extensive bone invasion to the mandible from the buccal mucosa.



The anatomy of the floor of the mouth is such that it lacks substantial fascial barrier particularly in edentulous jaws. For this reason, even early tumours can invade the underlying bone. This is consistent with findings of this study as the mandible was the most common site of bone invasion. The cortex of the mandible is invaded by OSCC either by adherence of the tumour or direct extension of the tumour. Imaging plays an important role in the assessment of the extent of SCC in the floor of the mouth, as it is a rich neurovascular site which facilitates metastases to the sublingual, submandibular and level II lymph node (Genden *et al.* 2010).

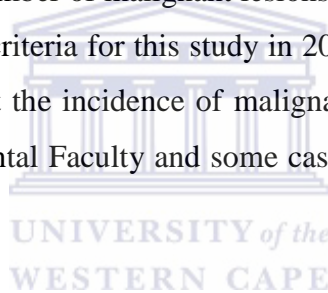
The management of an OSCC with bone erosion differs depending on the extent thereof. Larger deeply invading tumours are more likely to invade the bone, therefore decreasing the chance of a conservative rim resection. Most cases of OSCC with bone invasion are treated with surgical removal and post operative radiotherapy. The choice between either marginal or segmental resection can be aided by the extent of the bone invasion. It is reported that tumours that invade into the medullary canal will require a more drastic segmental resection (Brown *et al.* 2002). A study by Shaw *et al.* (2004) showed that although the extent and pattern of bone invasion is an important tool for treatment plan and prognosis, soft tissue factors remain the most important prognostic factors.

All the cases except one case of SCC found in this study showed bone invasion, which indicated that the patients presenting to Tygerberg Dental Faculty have

advanced lesions or that they are only referred when bone invasion is identified or queried.

#### 6.4. Trends over the ten year period

Worldwide, with more socio-political and socio-economical emphasis on the East and Africa, oral cancer has become a serious growing problem. It is reported that there is an annual increase in the number of cases reported of oral and oropharyngeal cancers (Warnakulasuriya, S. 2009). It is possible that despite attempts made at education patients and implementing screening tools, alcohol consumption and smoking is also increasing. The rising trends in oral cancer may be implicated by the increase in smoking habits and alcohol. This requires further studies as to why there is a rising trend in oral cancer. As opposed to this statement, no such trend was found in the present study. The largest number of malignant lesions was documented in 2010. No cases were found within the criteria for this study in 2006. However the results from this study do not truly reflect the incidence of malignant lesions as not all cases are referred to the Tygerberg Dental Faculty and some cases may not have been referred to the radiology department.



#### 6.5. Limitations and future recommendations

The results of this study show that there is a high frequency of OSCC associated with bone invasion, therefore efforts should be made for primary prevention in education on smoking, alcohol and other risk factors. Screening tools by private practitioners and hospitals should be reinforced to treat early cases of OSCC before the extent of bone invasion occurs as this negatively impacts on the prognosis.

A limitation of this study was that as it was a retrospective investigation with no possibility for standardisation with the quality and exposure factors of the panoramic radiographs. Although in almost all cases bone pathology was detected, panoramic radiographs are two dimensional images of three dimensional structures and this does not give an accurate account for changes in bone. Another limitation of this study was that no histological or clinical information was used as it was beyond the scope of

this study. With no clinical information obtained, the initial site of the tumours could not be correlated with the secondary bone invasion. It may be recommended that future studies be carried out using cone beam computed tomography (CBCT) prospectively as a tool for the detection of bone invasion by OSCC and correlated with clinical and histological information. The use of CBCT has not yet been compared to current imaging techniques for bone invasion of OSCC. Future studies can also be done on OSCC alone with an inclusion of tumours in the entire maxillofacial region, and not only the jaws.



## 7. CONCLUSION

From this study it can be concluded that non-odontogenic malignancies in the jaws are very common. The most common non odontogenic malignancy found at Tygerberg Dental hospital was the OSCC with secondary bone invasion. The second most common malignancy was osteosarcomas as a primary bone tumour of the jaw. Although panoramic imaging is a good screening tool for bone invasion from OSCC, it may not be as accurate as CT in early cases. Imaging alone cannot be used for the detection of bone invasion, but as an adjunct to clinical and tumour factors. It can be concluded that imaging may be diagnostic for primary jaw tumours such as osteosarcomas and chondrosarcomas, however in cases of OSCC it is more of a prognostic tool and useful in aiding in the treatment planning of the patient.



## 8. REFERENCES

Amusa, Y.B., Olabanji, J.K., Ogundipe, O.V., Olateju, S.O., Agbakwuru, E.A., Ndukwe, N, and Fatusi, O.A. 2004. Pattern of head and neck malignant tumours in a Nigerian teaching hospital – A ten year review. *WAJM*, 23 (4), 280-284.

August, M., Magennis, P., and Dewitt, D. 1997. Osteogenic sarcoma of the jaws: Factors influencing prognosis. *Int. J. Oral Maxillofac. Surg.* 26, 198-204.

Bennet, J.H., Thomas, G., Evans, A.W., and Speight, P.M. 2000. Osteosarcoma of the jaws: A 30 year retrospective review. *Oral Surg Oral Med Oral Pathol Oral Radiol Endod.* 90(3), 323-333

Bianchi, S.D and Boccardi, A. 1999. Radiological aspects of osteosarcoma of the jaws. *Dentomaxillofacial Radiology.* 28, 42-47.

Bolzoni, A., Cappiello, J., Piazza, C., Peretti, G., Moroldi, R., Farina, D., and Nicolai, P. 2004. Diagnostic Accuracy of Magnetic Resonance Imaging in the Assessment of Mandibular Involvement in Oro-Oropharyngeal Squamous Cell Carcinoma. *Arch Otolaryngol Head Neck Surg.* 130, 837-843.

Brown, J.S., Low, D., Kalavrezos, N., D'Souza, J., Megennis, P., and Woolgar, J. 2004. Patterns of invasion and routes of tumour entry into the mandible by oral squamous cell carcinoma. *Head and Neck.* 24(4), 370-383.

Choi, J.W. 2011. Assessment of panoramic radiography as a national oral examination tool: review of the literature. *Imaging Science in Dentistry*, 41, 1-6.

Daley, T and Darling, M. 2003. Non-squamous cell malignant tumours of the oral cavity: An overview. *J Can Dent Assoc*, 69(9), 577-82.

Dunfee, B.L., Sakai, O., Pistey, R., and Gohel, A. 2006. Radiologic and Pathologic Characteristics of Benign and Malignant Lesions of the Mandible. *RadioGraphics*, 26 (6) 1751-1769.

Gadwal, S.R., Fanburg-Smith, J.C., Gannon, F.H., and Thompson, L.D.R. 2000. Primary Chondrosarcoma of the Head and Neck in Pediatric Patients. *CANCER*. 88(9), 2181-2188.

Genden, E.M., Ferlito, A., Silver, C.E., Takes, R.P., Saurez, C., Owen, R.P., Haigentz Jr, M., Stoeckli, S.J., Shaha, A.R., Rapidis, A.D., Rodrigo, J.P., and Rinaldo, A. 2010. Contemporary management of cancer of the oral cavity. *Eur Arch Otorhinolaryngol*. 261, 1001-1017.

Kamulegeya, A and Kalyanyama, B.M. 2008. Oral maxillofacial neoplasm in an East African population a 10 year retrospective study of 1863 cases using histopathological reports. *BMC Oral Health*, 8 (19), 1-11

Kurubayashi, T and Sasaki, T. 2003. Accuracy of panoramic radiography in assessing the dimensions of radiolucent jaw lesions with distinct or indistinct borders. *Journal of Dentomaxillofacial Radiology*, 32 (3), 80-86.

Kushraj, T., Chatra, L., Shenai, P., and Rao, P.K. 2011. Bone invasion in oral cancer patients: A comparison between Orthopantomogram, conventional computed tomography, and single positron emission computed tomography. *Journal of Cancer Research and Therapeutics*, 7 (4), 438-441.

Larheim, T.A., Westesson, P.L. 2006. *Maxillofacial Imaging*. Berlin: Springer.

Lin, Y.L., Chen, C.H., Wang, W.C. Chen, Y.K. and Lin, L.M. 2005. Primary intraosseous carcinoma of the mandible. *Journal of Dentomaxillofacial Radiology*, 34, 112-116.

Lloyd, C and McHugh, K. 2010. The role of radiology in head and neck tumours in children. *Cancer Imaging*, 10, 46-61.

Mossano, J., Regateiro, F.S., and Januario, G. 2006. Oral Squamous Cell Carcinoma: Review of Prognostic and predictive factors. *Oral Surg Oral Med Oral Pathol Oral Radiol Endod.* 102, 67-76.

Nakayama, E. 2009. Imaging diagnosis for bone invasion by gingival carcinoma of the mandible: The value and the limitation. *Japanese Dental Science Review*, 45, 23-30.

Nakayama, E., Sugiura, K., Ishibashi, H., Oobu, K., Kobayashi, I., and Yoshiura, K. 2005. The clinical and diagnostic imaging findings of osteosarcoma of the jaw. *Dentomaxillofacial Radiology.* 34, 182-188.

Ojo, M.A. and Nortje, C.J. 2001. Osteosarcoma of the mandible, conventional panoramic, computed tomography (CT) and magnetic resonance imaging (MRI) findings. *Nigerian Journal of Clinical Practice.* 4(2), 96-99.

Petrikowski, C.G., Pharoah, M.J., and Grace, M.G.A. 1995. Radiographic differentiation of osteogenic sarcoma, osteomyelitis and fibrous dysplasia of the jaws. *Oral Surg Oral Med Oral Pathol Oral Radiol Endod.* 80(6), 744-750.

Razani, S.M. and Sajadi, S. 2007. Epidemiological study of oral and perioral cancers in Isfahan. *Dental Research Journal*, 4(1), 18-25.

Riaz, N and Warriach, R.A. 2011. Tumours and tumour-like lesions of the oro-facial region at Mayo Hospital, Lahore- A five year study. *ANNALS*, 17 (2), 123-129.

Shaw, R.J. Brown, J.S., Woolgar, J.A., Lowe, D., Rogers, S.N., and Vaughan, E.D. 2004. The influence of the pattern of mandibular invasion on recurrence and survival in oral squamous cell carcinoma. *Head and Neck.* 26, 861-869.

Subhashraj, K, Orafi, M, Nair, K.V., El-Gehani, R. and Elarbi, M. 2009. Primary malignant tumours of orofacial region at Benghazi, Libya: A 17 years review. *The International Journal of Cancer Epidemiology, Detection, and Prevention*, 33, 332-336.



Theodorou, D.J., Theodorou, S.J. and Sartonis, D.J. 2003. Primary non-odontogenic tumours of the jaw bones. An overview of essential radiographic findings. *Clinical Imaging*, 27 (1), 59-70.

Warnakulasuriya, S. 2009. Global epidemiology of oral and oropharyngeal cancer. *Oral Cancer*, 45, 309-316.



## 9. APPENDICES

### Appendix 9.1.

**Office of the Deputy Dean**  
**Postgraduate Studies and Research**  
Faculty of Dentistry & WHO Collaborating Centre for Oral Health

---

UNIVERSITY OF THE WESTERN CAPE  
Private Bag X1, Tygerberg 7505  
Cape Town  
SOUTH AFRICA

**Date: 23<sup>rd</sup> November 2012**

**For Attention: Dr Z Yakoob**  
**Diagnostic and Radiology**



Dear Dr Yakoob

**STUDY PROJECT: A retrospective analysis of the non-odontogenic malignancies of the jaws using panoramic radiography**

**PROJECT REGISTRATION NUMBER: 12/10/55**

**ETHICS:      **Approved****

At a meeting of the Senate Research Committee held on Friday 23<sup>rd</sup> November 2012 the above project was approved. This project is therefore now registered and you can proceed with the study. Please quote the above-mentioned project title and registration number in all further correspondence. Please carefully read the Standards and Guidance for Researchers below before carrying out your study.

Patients participating in a research project at the Tygerberg and Mitchells Plain Oral Health Centres will not be treated free of charge as the Provincial Administration of the Western Cape does not support research financially.

Due to the heavy workload auxiliary staff of the Oral Health Centres cannot offer assistance with research projects.

Yours sincerely



### Appendix 9.3. Data collection key

Bone changes 1 = yes

2 = no

#### Location

Indicate which of the anatomical locations the lesion occupies

Anterior Mandible

Mandibular left body

Mandibular right body

Left maxilla

Right maxilla



#### Border of the lesion

1 = regular

2 = irregular

#### Nature/content of the lesion

1 = radiolucent

2 = radiopaque

3 = mixed radiolucent radiopaque

4 = normal