

# Immediate versus Delayed Surgical Management of Septic Mandibular Fractures

Lindubuhle Mdlalose  
9825315



UNIVERSITY *of the*  
WESTERN CAPE

Supervisor:  
Prof JA Morkel

# TABLE OF CONTENTS

Acknowledgements.....	5
Declaration.....	6
List of Abbreviations.....	7
Key Words.....	7
Abstract.....	8
List of Tables.....	9
List of Figures.....	10
CHAPTER 1: Introduction .....	11
CHAPTER 2: Literature review.....	12
Protocol for treatment of mandibular fractures.....	12
Causes of sepsis.....	14
Effect of mobility on infection.....	15
Effect of infection on bone healing.....	15
Infection following osteosynthesis.....	16
Foreign-body effect of implant.....	17
Implants placed in clean wounds.....	17
Implants placed in contaminated wounds.....	17
Bacterial biofilm.....	18
Teeth in fracture line.....	19
Surgical management of septic mandibular fractures.....	20
Delayed approach.....	20

Immediate approach.....	21
Intermaxillary fixation.....	23
Bone debridement.....	24
Rigid internal fixation.....	24
Antibiotic prophylaxis.....	25
Septic markers.....	26
CHAPTER 3: Methodology.....	27
Study design.....	27
Aim.....	27
Objectives.....	27
Study population.....	27
Patients and methods.....	27
Inclusion criteria .....	28
Exclusion criteria.....	28
Method of randomization.....	28
Criteria to be evaluated.....	31
Data management and statistical analysis.....	32
Ethical statement.....	32
Conflict of Interest statement.....	32
Null hypothesis.....	32
CHAPTER 4: Results.....	33
Response rate.....	33
Demographic information.....	33
Surgical time.....	34
Hospital admission.....	35
Follow-up visits.....	35
Fracture Stability.....	35

Fracture union.....	35
Pain.....	36
Temperature.....	36
Pulse.....	37
CHAPTER 5: Discussion.....	38
Conclusion.....	40
References.....	41
Appendix 1: Informed consent.....	46
Appendix 2: Patient information letter.....	47
Appendix 3: Data capturing sheet.....	48

## **ACKNOWLEDGEMENTS**

I would like to thank my mother Nonhlanhla Dlamini for raising me even though odds were stacked against her. To my siblings Khulekani, Thobekani and Nomvula I would like to thank you for your prayers and encouraging words especially when the chips were down. My friends Mthobeli Vundla, Sandile Mpungose, Manqoba Mkhize, Mzwandile Chonco, Simo Mpungose and Maliviwe Dlamini, thank you guys for being there for me since 2010 when the project started.

I would also like to express my utmost gratitude to my full time consultants Profs J Morkel, G Kariem and Dr G Hein. A word of thanks is extended to my part-time consultants Drs B Berezowski, M Ostrofsky, S Singh, S Aniruth, F Otto and E Parker.

To my fellow registrars thank you very much for your support and camaraderie.

Last but not least I would like to thank the general staff at the Maxillo-Facial and Oral Surgical units at Groote Schuur and Tygerberg Academic Hospitals.

## **DECLARATION**

I declare that Immediate versus Delayed Surgical Management of Septic Mandibular Fractures is my own work, that it has not been submitted for any degree or examination at any other university, and that all the sources I have used or quoted have been indicated and acknowledged by complete references.

**Lindubuhle Mdlalose**

**Signature..... Date.....**

## **LIST OF ABBREVIATIONS**

MMF = MaxilloMandibular Fixation  
ORIF = Open Reduction and Internal Fixation  
IMF = Intermaxillary Fixation

## **KEY WORDS**

Septic, mandible, fracture, fixation, plates

## ABSTRACT

**Aim:** The aim of the study was to compare immediate and delayed surgical management of septic mandibular fractures.

**Introduction:** Infected mandible fractures can be treated via diverse protocols. Two recognized protocols are the so-called delayed approach and the immediate approach. In the delayed approach, sepsis is resolved first, followed by surgery. With the immediate approach, the sepsis is first drained, followed by open reduction and internal fixation of the jaw fracture in one continuous surgical procedure.

**Material and methods:** 20 clinical cases were included in the study.

Patients were randomly selected and assigned to the two treatment protocol groups. Pain, vital signs, fracture union, fracture stability, surgical time, hospital time, follow-up visits and patients' demographics were recorded.

**Results:** No statistically significant findings were made in the analysis of the demographic data and clinical parameters relating to the sepsis. The only significant data were related to the surgical time and hospital time. It was found that the advantages of the immediate approach versus the delayed approach related only to shorter surgical time and less days spent in hospital for the immediate approach.

**Conclusion:** Septic mandibular fractures can be managed either by an immediate or a delayed approach. The immediate surgical approach seems to have an advantage over the delayed approach regarding the surgical time and hospital admission days.



## **LIST OF TABLES**

Surgical wound classification

Table 1

Fracture stability and union

Table 2

## LIST OF FIGURES

AO Foundation management protocol	Figure 1
Screw position on plate	Figure 2
Left submandibular abscess	Figure 3
Post drainage of abscess	Figure 4
Pre-operative Orthopantomograph	Figure 5
Post-operative Orthopantomograph	Figure 6
Left sub-masseteric abscess	Figure 7
Draining sinus	Figure 8
Pre-operative angle fracture	Figure 9
Post-operative ORIF angle fracture	Figure 10
Graph depicting gender	Figure 11
Graph depicting age	Figure 12
Graph depicting mean surgical time	Figure 13
ORIF at 6 weeks post-op	Figure 14
ORIF at 3 months post-op	Figure 15
Pain score after surgery	Figure 16
Temperature after surgery	Figure 17
Pulse rate after surgery	Figure 18

## **CHAPTER 1: INTRODUCTION**

The management of septic mandibular fractures poses a challenge to maxillofacial and oral surgeons. This challenge relates to patients presenting to the health facility when sepsis has already set in, immuno-compromised patients and pre-existing bone pathology.

Infected mandible fractures can be treated with diverse protocols. Two recognized protocols are the so-called delayed approach and the immediate approach. In the delayed approach, sepsis is resolved first, followed by surgery (Hardman, 1982). With the immediate approach, the sepsis is first drained, followed by open reduction and internal fixation of the jaw fracture in one continuous surgical procedure (Kai Tu, 1985).

The delayed approach has been popular with surgical units in Cape Town. However, it involves extended hospitalization and treatment time and often requires multiple treatment procedures. The immediate approach reduces treatment time but optimal bone healing has been questioned by surgeons in the past although there is no scientific basis for this reservation. It would therefore be advantageous to test the efficacy of the different protocols in South African units where many patients with septic mandible fractures are managed. Reducing the treatment time and the number of surgical procedures required could also decrease the high patient admission and out-patient follow-up load at treatment centers in Cape Town.

## CHAPTER 2: LITERATURE REVIEW

Mandibular fractures are common facial injuries and are most frequently treated by oral and maxillofacial surgeons. The leading causes of mandibular fractures are motor vehicle accidents and assaults. Champy et al. (1978) and Cawood (1985) recommended that, to achieve low rates of wound dehiscence and infection, miniplate osteosynthesis must be performed soon after injury. Champy et al. (1978) recommended fixation within 12 hours, whereas Cawood (1985) extended this period to 24 hours after injury.

### 1.1 Protocol for treatment of mandibular fractures

There are multiple classifications of mandibular fractures noted in the scientific literature. The AO Foundation (Cienfuegos et al.) uses a simplified anatomical classification that leads into a five step management protocol involving Diagnosis, Decision, Surgical approach, Treatment and Aftercare as depicted in Figure 1.

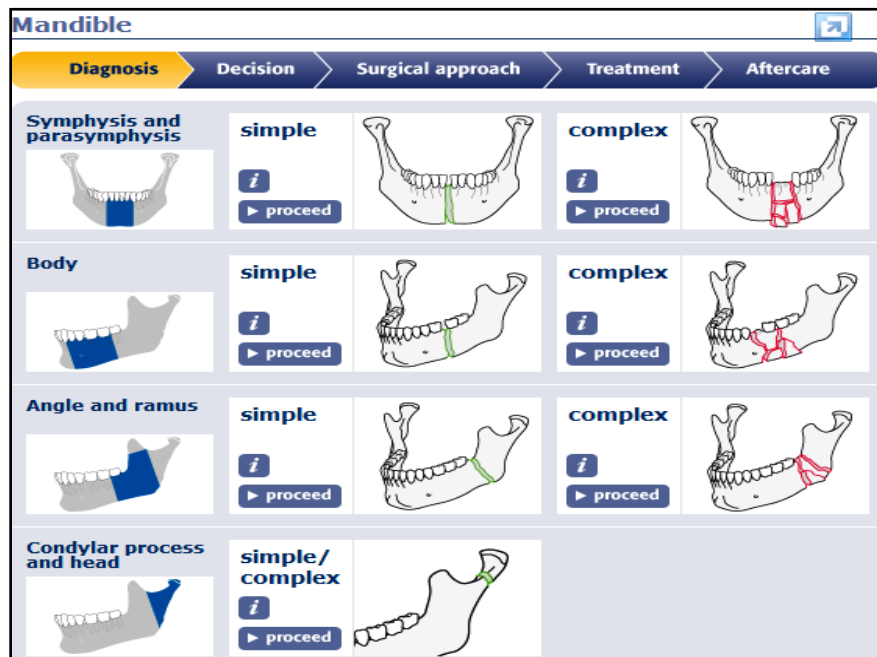


Figure 1. AO Foundation management protocol.

The AO Foundation suggests the following treatment principles for these anatomical regions and fracture combination:

Simple fractures of the symphysis and parasymphysis can be managed via closed treatment [Maxillo-Mandibular Fixation (MMF) for six weeks], or Open Reduction Internal Fixation (ORIF) which may involve, two lag screws, lag screw and a plate, one plate and MMF, or two plates. Complex fractures of these regions are mostly managed via ORIF.

Simple fractures of the body can be managed conservatively via observation, via closed treatment or ORIF (lag screws, one plate, two plates or large plates). Complex fractures are mostly managed via ORIF (two plates, reconstruction plate, external fixator).

Simple fracture of the angle and ramus of the mandible can be managed via observation, closed treatment or ORIF (wire, one miniplate, two miniplates, reconstruction plate). Complex fractures of the angle and ramus are mostly managed via ORIF (two plates, reconstruction plate, external fixator).

Fracture (simple and complex) of the condylar process and head of the mandible may be managed via diverse modalities which may include, closed treatment, ORIF with or without endoscopic assistance. Observation only is indicated for certain fractures.

The AO Foundation further suggests that special consideration should be given to cases involving multiple fractures, edentulous atrophic fractures, teeth in the line of fractures, fractures of the alveolar process, infected fractures with or without bone loss and coronoid process fractures.

The CDC Surgical Wound Classification (Garner, 1986) should be considered in the decision to prescribe prophylactic or therapeutic antibiotics. Wounds are classified as Clean, Clean Contaminated, Contaminated or Dirty-Infected as depicted in Table 1.

<b><i>Clean:</i></b>	An uninfected operative wound in which no inflammation is encountered and the respiratory, alimentary, genital, or uninfected urinary tract is not entered. In addition, clean wounds are primarily closed and, if necessary, drained with closed drainage. Operative incisional wounds that follow non-penetrating (blunt) trauma should be included in this category if they meet the criteria.
<b><i>Clean-Contaminated:</i></b>	An operative wound in which the respiratory, alimentary, genital, or urinary tracts are entered under controlled conditions and without unusual contamination. Specifically, operations involving the biliary tract, appendix, vagina, and oropharynx are included in this category, provided no evidence of infection or major break in technique is encountered.
<b><i>Contaminated:</i></b>	Open, fresh, accidental wounds. In addition, operations with major breaks in sterile technique (e.g., open cardiac massage) or gross spillage from the gastrointestinal tract, and incisions in which acute, non-purulent inflammation is encountered are included in this category.
<b><i>Dirty-Infected</i></b>	Old traumatic wounds with retained devitalized tissue and those that involve existing clinical infection or perforated

**Table 1:** Surgical Wound Classification

### **1.2 Causes of Sepsis**

The etiology of infected mandibular fractures is multifactorial. Instability, failed ORIF appliances (loose hardware), associated diseased teeth, medical compromise, patient non-compliance and delay in treatment have all been implicated (Benson et al., 2006).

Mucosal tears and fractures extending through the periodontal ligament produce contamination of the fracture via oral flora. Most fractures that occur through the tooth-bearing area can therefore be regarded as contaminated. In addition, surgical intervention through the poorly cleanable oral cavity further contaminates the wound (Benson et al., 2006)

### **1.3 Effect of Mobility on Infection**

Internal fixation has been called the superior treatment for infected mandibular fractures," partly because the biological reaction to mechanical influences plays an important role in local infection" (Beckers, 1979).

Schilli W et al. (1977) showed that instability promotes infection, and stability helps prevent it.

Friedrich and Klaue (1977), showed a correlation between the presence of osteitis and lack of rigidity in rabbit long-bone fractures by injecting staphylococcus aureus into rigidly or non-rigidly fixed sites. The group of mobile fractures without bacterial infection did not become infected, showing that even with mobility, contamination must occur to produce infection. With mandibular fractures, maxilla-facial and oral surgeons have made similar suggestions regarding the effect of mobility on the rate of infection (Kellman, 1984).

#### **1.4 Effect of Infection on Bone Healing**

Several authors have shown that bone union can take place in the face of infection both experimentally and clinically.

For instance, all of Macausland and Eaton's (1979) 14 postoperative septic long-bone fractures treated with intramedullary rods achieved bony union even though infection was present. He believed complete immobilization promoted osseous union.

Similarly, Souyris et al. (1980) reported 25 mandibular fracture cases treated with internal fixation that became infected in the early postoperative period. The plates were left in place for several weeks and, on removal, the bone was found to have healed.

Johansson et al. (1988) found primary bone healing in 76% of cases where infection was present.

Experimental verification of bone union in the face of infection was offered by Rittmann and Perren (1974). They conducted osteosynthesis on sheep femurs and infected the stable bone-plated fractures with staphylococci over a period of 8 weeks. All showed bony union over this period, some of which was primary, despite the clinical infections.

The study by Friedrich and Klaue (1977) of rabbit long-bone fractures stabilized internally and infected with *Staphylococcus aureus* also showed that primary bone union occurred in the face of infection as long as the osteosynthesis was stable.

Meyer et al. (1975) treated 214 cases of osteomyelitis after operative treatment of fractures. In this study, 45 of 49 fractures that had unstable fixation resulted in nonunion.

Nicol (1964) demonstrated that, in the presence of infection, nonsurgical treatment may not be effective because of the lack of rigidity. He treated 22 infected long-bone fractures nonsurgically, with a resulting 60% incidence of delayed union or nonunion.

### **1.5 Infection Following Osteosynthesis**

Here the question arises: Once an infection develops in a fracture stabilized with internal fixation, can complete resolution of the infection be obtained while the implant remains in place? Many clinicians in orthopedics and maxillofacial surgery have stated that implants must be removed to resolve infection under these circumstances (Dahl-Iverson, 1928).

Out of a total of 220 and 373 arthroplasties respectively, Insall et al. (1979) and Kaufer and Matthews (1981) each reported three deep infections that required implant removal for resolution. However, many orthopedic practitioners believe metal implants that provide stability should be left in place and only the unstable ones removed.

Hicks (1964) believed infection was easy to overcome with rigid internal fixation. Although several authors have stated that implants must be removed to resolve infection in the mandible, clinicians have shown resolution without removal as long as the fixation was stable.

Johansson et al. (1988) reported 42 infected mandibular fractures treated with miniplates. Twenty-four percent of the infections persisted postoperatively. Six of nine resolved, whereas in the remaining three, the fixation devices were removed because of instability.



## **1.6 Foreign-Body Effect of Implant**

In orthopedics and oral and maxillofacial surgery, many have emphasized the foreign-body effect of a metal implant (Strelzow, 1983). Difficulty exists in accurately determining the biological influence of a foreign body, because when an implant is placed, surgical trauma is inevitably inflicted. If an infection then develops, it is difficult to determine whether the implant or the surgical trauma and contamination caused the infection (Koury and Ellis, 1992).

## **1.7 Implants Placed Into Clean Wounds**

The closest approximation of the risk assumed solely by the addition of an implant to the body is seen when placement occurs with minimal soft tissue and vascular trauma during a sterile elective procedure. Such is the case with prosthetic joint replacement. Insall et al. reported three deep infections in 220 arthroplasties for total knee replacements in 1964. Similarly, Kaufer and Matthews reported three deep infections in 373 total knee replacements in 1981. Other orthopedic studies have yielded similar rates of infection when implants are placed into sterile atraumatic wounds, showing an extremely low incidence of infection under these conditions, in spite of the fact that these implants move under function (Sheehan, 1978).

In cases of closed long-bone fractures, the infection rate is not appreciably greater with internal fixation than with closed reduction (Sheehan, 1978).

## **1.8 Implants Placed Into Contaminated Wounds**

A difference in the rate of infection between implants placed in clean and in contaminated wounds was demonstrated by Rittmann et al. in 1974. Open and closed tibial fractures were treated with open reduction and internal fixation with compression plates. He found a 1.8% infection rate in the closed (uncontaminated) fractures and a 6.3% in the open (contaminated) fractures. Likewise, Burri (1975), in a study of 744 fractures, reported an infection rate of 0.18% in closed and 2.7% in open fractures treated with internal fixation. Towers also noted an

increased rate of infection in open (contaminated) fractures and believed fewer bacteria were needed to produce clinical infection with metal implant placement. The body may have difficulty with bacteria in the presence of implants because biomaterials are suitable substrata for their growth. Removal of fixation appliances from infected wounds unresponsive to antibiotics has revealed bacterial colonization on their surface (Nishioka, 1966).

## **1.9 Bacterial Biofilm**

A bacterial biofilm has also been shown on orthopedic implants. This surface slime, or glycocalyx, is made from carbohydrates of the bacterial cell wall and is believed to increase the incidence of infection, to provide a barrier to macrophage and antibiotic penetration, as well as to prohibit the culturability of these bacteria (Gristina, 1983). Also, spread of bacteria down nonreactive biomaterials into uncolonised areas has been shown. In effect, biomaterials alter the body's defense system and provide a surface for bacterial adherence and colonization (Koury and Ellis, 1992).

The oral and maxillofacial surgeon uses a variety of biomaterials. Many of these are exposed to intraoral flora when initially placed. It is well known that the oral flora is a diverse polymicrobial population that contains a large number of bacteria capable of producing a glycocalyx that facilitates adherence (Nishioka et al., 1988).

There is thus a difference in the rates of infection between placing implants in closed (clean) and in open (contaminated) fractures. A comparison must be made, however, between the use of internal fixation devices and not using them when treating contaminated (open) fractures. In other words, when a contaminated fracture requires open reduction, does the use of implants alter the rate of infection? Answering this question allows one to weigh the risk of the foreign body versus the benefit of stabilization of the bony fragments and the soft-tissue bed in the presence of bacteria (Koury and Ellis, 1992).

Soft-tissue injury has been shown to be a primary factor in infection rates with internal fixation of contaminated fractures. Maloney (2001) showed a 1.9% infection rate with mild soft-tissue

trauma, 8% with moderate trauma, and 41% in severe soft-tissue trauma of open fractures. Edwards in 1965 similarly demonstrated this point and showed the infection rate of internally fixed fractures could be greatly reduced by not extending the wound when placing the fixation.

In dogs, he also found a decrease in the incidence of osteomyelitis when no soft-tissue damage was produced when similar bony fractures were created (Koury and Ellis, 1992).

### **1.10 Teeth in fracture line**

Injury to teeth in the fracture line may complicate the fracture even more if the injury involves the periodontium (Ellis, 2003). Injury to such teeth can result in their avulsion, subluxation, root fracture, non-vitality, and varied pathology, all of which may interfere with or complicate healing.

The influence on infection of teeth in a fracture line is not easy to determine due to interaction with other factors. Root fractures, periodontal pathology near the fracture line, functionless teeth, and vertical tooth fracture are all recommended for extraction (Ajmal et al., 2007).

Correct repositioning of fractured fragments is quicker and easier if the tooth in the line of fracture is conservatively managed (Samson et al., 2010). The teeth provide occlusal reference and posterior stop. They have a stabilising effect and do not impede bone healing. If extracted, there is an increase in the risk of fracture contamination and the wounds may sometimes be difficult to suture. Pulp changes like pulp fibrosis and acute pulpitis may be noted in teeth that respond to an electronic pulp tester (Samson et al., 2010).

A tooth that shows no response on pulp vitality testing should be advised for extraction to avoid further complications in patients presenting with mandibular fracture (Samson et al., 2010).

A study by Malanchuk et al. (2007) concluded that a tooth in the fracture line could not be considered as a predisposing factor in the development of infection, providing that antibiotics are administered. They found that the infection rate for fractures, located in edentulous parts of the

tooth-bearing area, was practically the same, supporting the fact that bacteria can easily penetrate into the fracture zone via lacerations and mucosal ruptures.

### **1.11 Surgical Management of Septic mandibular fractures**

The treatment of infected mandible fractures remains controversial. Clinical management goals include restoration of pre-trauma function, form, and occlusion; limitation of pain and disability; elimination of infection; preservation of teeth and bone; and restoration of motor and sensory nerve function (Mehra, 2009).

Literature alludes to the terminology of conventional or delayed approach for infected mandibular fractures and the new or immediate approach (Beckers, 1979, Benson et al., 2006, Koury and Ellis, 1992). Primary infected fractures are defined as fractures that were not previously treated with plates and screws. Secondary infected fractures are defined as fractures that were treated with plates and screws where the plates and screws have loosened.

#### **1.11A Delayed Approach**

Historically, infected mandibular fractures were managed with closed techniques in the form of intermaxillary fixation (IMF), dental devices, and external fixators; drainage and sequestration was promoted while the occlusion was controlled. Associated teeth were removed. The process was allowed to run its course, usually several months (Alpert and Kuchner, 2008).

Prior to the advent of rigid internal fixation (RIF) for mandibular fractures, treatment consisted of antibiotics, drainage, removal of associated teeth, and intermaxillary fixation and/or skeletal pins. Debridement was done when there was x-ray evidence of sequestrum formation (Alpert and Kuchner, 2008). It was often many weeks before drainage ceased and then months before union occurred or reconstruction with bone grafts was permitted. Thus, infected mandibular fractures were subject to a course of treatment over many months during which time the patient was immobilized.

The period of intermaxillary fixation predicted to achieve union (6 to 8 weeks) began only after cessation of drainage. Usually the fracture healed within 3 to 4 months of intermaxillary fixation and/or other fixation devices, but occasionally a non-union (as evidenced by ebonated bone ends) ensued (Alpert and Kuchner, 2008). This situation required a bone graft and an additional 2 months of intermaxillary fixation. There were further problems if control of the proximal fragment was an issue. To prevent the proximal fragment from riding up, external fixation was necessary. If teeth were inadequate for stable intermaxillary fixation, splints were used with the attendant morbidity of their retaining wires (Alpert and Kuchner, 2008).

### **1.11B Immediate Approach**

Over the years, several authors recognized that moving fragments promoted the infection (Spiessl, 1989). With the advent of rigid internal fixation (RIF) with plates and screws, stable internal fixation of the fragments was possible.

A few bold surgeons rigidly fixed these infected fractures and achieved successful outcomes, going against the prevailing principle of never placing hardware in an infected area (Koury et al., 1994). They theorized that RIF would allow resolution of the process by eliminating movement and allowing the body's defenses to eliminate the infection, converting the infected fracture site to a healing one.

This treatment proved successful unless there was dead bone or sequestrum in the fracture site. This had to be resorbed, exfoliated, or surgically removed (Alpert et al., 2008). The next advance combined RIF with debridement of the fracture site (creating a defect fracture) and primary bone grafting, an approach noted by several authors (Beckers, 1979, Prein, 1990, Alpert et al., 2008).

In 2006 Benson et al. reported the effectiveness of this immediate approach with outcomes as favourable as those for non-infected mandibular fractures. This shortened the course of treatment and simplified the convalescence by allowing function. Twenty-one infected mandibular fractures in 19 patients were managed with RIF, debridement, and primary bone grafts, with 20 of the 21 achieving union. Both transoral and transfacial approaches were used in this series.

Using these approaches, the course of treatment was dramatically shortened. Convalescent function is allowed, and a favorable outcome is most likely to occur. If it does not work, one has lost only a minor graft, but the RIF device is still in place and the patient is still functional.

Internal fixation has been labeled the superior treatment for infected mandibular fractures, "partly because the biological reaction to mechanical influences plays an important role in local infection" (Beckers, 1979). Schilli W et al. (1977) showed that instability promotes infection, and stability helps prevent it.

Friedrich and Klaue (1977), showed a correlation between the presence of osteitis and lack of rigidity in rabbit long-bone fractures by injecting staphylococcus aureus into rigidly and non-rigidly fixed sites. The group of mobile fractures without bacterial infection did not become infected, showing that even with mobility contamination must occur to produce an infection. With mandibular fractures, surgeons have made similar suggestions regarding the effect of mobility on the rate of infection (Alpert et al., 2008).

Several authors have shown that bone union can take place in the face of infection both experimentally and clinically. For instance, in a study by Macausland and Eaton (1979), all 14 postoperative septic long-bone fractures treated with intramedullary rods achieved bony union even though infection was present. They believed complete immobilization promoted osseous union. Similarly, Souyris et al. (1980) reported 25 cases of mandibular fracture treated with internal fixation that became infected in the early postoperative period. The plates were left in place for several weeks and, on removal, the bone was found to have healed. Johansson et al 1988 found primary bone healing in 76% of cases where infection was present. Experimental verification of bone union in the face of infection was offered by Rittmann and Perren (1974). They conducted osteosynthesis on sheep femurs and infected the stable bone-plated fractures with staphylococci over a period of 8 weeks. Despite the clinical infections, all fractures showed bony union over this period, some of which was primary. As already mentioned before, the study by Friedrich and Klaue (1977) of rabbit long-bone fractures stabilized internally and infected with *Staphylococcus aureus* also showed that primary bone union occurred in the face of infection as long as the osteosynthesis was stable.

Meyer et al. (1975) treated 214 cases of osteomyelitis after surgical treatment of fractures; 45 of 49 fractures that had unstable fixation resulted in nonunion. Furthermore, in the presence of infection, nonsurgical treatment may not be effective because of the lack of rigidity, as demonstrated by Nicol (1964). He treated 22 infected long-bone fractures non-surgically, with a resulting 60% incidence of either delayed union or nonunion.

Once an infection develops in a fracture stabilized with internal fixation, is complete resolution of the infection possible while the implant remains in place? Some orthopedic and maxillofacial surgeons have stated that implants must be removed to resolve infection under these circumstances. Insall et al. (1979) and Kaufer and Matthews (1981), each reported three deep infections out of 220 and 373 arthroplasties which required implant removal for resolution. However, many in orthopedics believe metal implants that provide stability should be left in place and only the unstable implants removed. Hicks (1964) believed infection was easy to overcome with rigid internal fixation. Although several authors have stated that implants must be removed to resolve infection in the mandible, clinicians have shown resolution without removal as long as the fixation was stable. Johansson et al. (1988) reported 42 infected mandibular fractures treated with miniplates. Twenty-four percent of the infections persisted postoperatively. Six of nine resolved, whereas in the remaining three the fixation devices were removed because of instability. Beckers (1979) showed resolution of all 19 infected mandibular fractures he treated with internal fixation.

### **1.12 Intermaxillary Fixation (MaxilloMandibular Fixation)**

Intermaxillary fixation is the wiring together of the upper and lower jaw. It can be used as a form of reduction during the surgical procedure or as definitive treatment in simple mandibular fractures. The purpose of the one-week postoperative IMF is threefold as described by Mehra in 2009. Firstly, it helps maintain primary closure of the surgical site until formation of an oral seal at the extraction sites. Secondly, it reinforces patient compliance with a soft diet in the initial postoperative period until appropriate dietary habits have been established. Thirdly, it motivates patients to return for postoperative examinations. However, the aspect of quality of life in regard

to eating/nutrition, speaking and airway management has become a major issue as relative contraindication to this modality.

### **1.13 Bone Debridement**

Bone debridement is accomplished to bleeding margins, with an effort to maintain the lingual cortex, unless it is grossly infected or necrotic. This lingual cortical preservation eliminates a continuity defect which would obligate the surgeon and patient to future bone reconstruction (Mehra, 2009).

Once the fracture site is exposed, drained, and debridement accomplished with a rotary instrument, rigid internal fixation is placed with two screws per side and a minimal distance of 10 mm between the fracture site and the first screw (Mehra, 2009).

### **1.14 Rigid Internal Fixation**

The basic concept of rigid fixation is the achievement of absolute stability and a variety of techniques are advocated to achieve this goal.

Champy et al. (1978) suggest that engaging a single cortex is sufficient for rigid osteosynthesis.

In contrast, other authors believe that rigid osseous fixation cannot be obtained without bicortical engagement of the screws. Prein and Kellman (1987) and Spiessl (1989) stressed two fundamental principles required to obtain adequate rigid internal fixation for comminuted mandibular fractures. First, the fixation needs to support the full functional load (load-bearing osteosynthesis). Second, absolute stability of the fracture construct must be achieved. This is the prerequisite for sound bone healing and a low rate of infection.

The advantages of titanium plates for rigid fixation of mandibular fractures are that they allow the patient to have mandibular function and to achieve a normal diet earlier than those patients



treated with closed reduction and a period of inter-maxillary fixation. This avoids hypomobility secondary to prolonged intermaxillary fixation (Gabriella et al., 2003).

Rigid fixation is believed to result in faster bone repair due to compression of the fracture segments and lack of mobility between the fracture segments (Kamboozia and Punnia-Moorthy, 1993).

The published data Laskin in 2003 have recommended three to four screws should be placed on each side of a fracture to secure a plate (Figure 2).

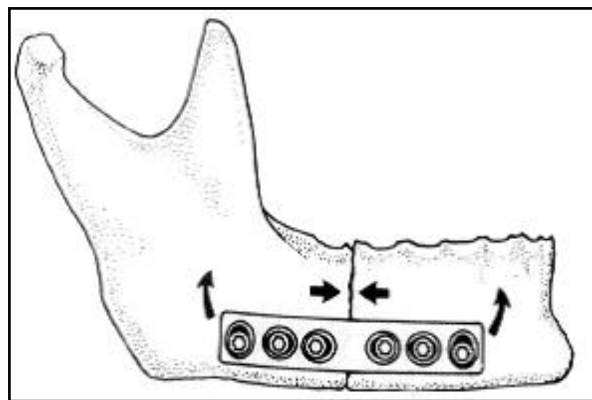


Figure 2. Screw position on plate

However, placing this many screws requires more extensive periosteal stripping, and, two screws per side have been sufficient to secure plates, especially if no continuity defect is present and one week of postoperative intermaxillary fixation is used (Mehra, 2009).

### 1.15 Antibiotic Prophylaxis

Patients with condylar process fractures treated by either open or closed reduction require no prophylactic antibiotics. The same is true for fractures in other non-tooth-bearing areas that are not in communication with the mouth, because these are all clean wounds. However, compound mandibular fractures are by nature contaminated wounds and here studies have shown that the use of antibiotics is effective in reducing postoperative infections. In most of these studies,

however, the antibiotics are given not only preoperatively but also for a long period postoperatively (Chole and Yee, 1987). More recent investigations have shown that prophylactic antibiotics given preoperatively and for no longer than 12 hours postoperatively are just as effective as long-term antibiotic use in preventing postoperative infections (Laskin, 2003). These findings apply only to fractures that are treated shortly after the injury has occurred. Fractures for which there is delayed treatment should be considered dirty wounds, and such patients should receive therapeutic antibiotics postoperatively (Laskin, 2003).

### **1.16 Septic Markers**

Classically, the individual with sepsis presents with fever and often shaking chills or rigors. Nausea, emesis and diarrhea may occur. Occasionally these symptoms may have their onset one to two hours after manipulation. On physical examination of the patient with sepsis, the blood pressure is found to be maintained in the patient's normal or near-normal range. The patient may have a high fever or a normal temperature. Occasionally the patient may be hypothermic with temperature in the less than 36 °C range. The patient is tachycardic (elevated heart rate) with a rapid bounding pulse. The respiratory rate is usually elevated. The skin may be warm and flushed. The white cell count ( $4-11 \times 10^9$ ) may be elevated or may be strikingly low. Measurement of clotting parameters may show prolongation of the prothrombin time and a decrease in platelets. The blood lactate may be measurably elevated but usually is at low levels (Lizuka et al., 1991).

## **CHAPTER 4: METHODOLOGY**

### **Study design**

Analytical prospective, randomized case series of selected patients for management of septic mandibular fractures at the Maxillo-Facial and Oral Surgery clinics of UWC at Tygerberg and Groote Schuur hospitals.

### **Aim of study:**

The aim of the study was to compare immediate and delayed surgical management of septic mandibular fractures.

### **Objectives:**

To compare:

- Fracture union
- Fixation stability
- Pre- and post-operative septic parameters
- Pre- and post-operative pain
- Surgical theatre time
- Hospital admission time
- Number of follow-up visits

### **Study population**

The study population comprised of patients who presented with septic mandibular fractures at the Maxillo-Facial and Oral Surgery units of UWC at Tygerberg and Groote Schuur hospitals.

### **Patients and methods**

The sample size was 20 patients. Twenty standardized cases were used, 10 undergoing an immediate approach and 10 undergoing a delayed approach.

**Inclusion criteria:**

- Any sex or race
- Completed mandibular growth, > 18 years of age
- Unilateral mandibular fractures, not older than three weeks, with the presence of pus in the fracture site

**Exclusion criteria:**

- Patients with history of immune compromise/deficiency
- Presence of pathological fractures
- Severe facial cellulitis
- Severe infection with airway compromise
- Multiple mandibular fractures
- Comminution or bone loss which does not allow bony contact
- Previous radiotherapy or carcinomas in the site
- Sepsis in fracture site more than three weeks old.

**Method of randomization**

A flip of a coin determined which treatment modality would be chosen for the first case. Then alternate treatment options were employed with each subsequent case.

All surgery was performed under standardized general anaesthesia. Patients had an intravenous line inserted and at induction they received propofol and fentanyl. Rocuronium bromide was administered as a muscle relaxant. Laryngoscopic nasotracheal intubation was performed and a gauze throat pack placed. During the surgical procedure, the patient was kept anaesthetized with sevoflurane or isoflurane.

At the conclusion of surgery, the action of the muscle relaxant was reversed with neostigmine and glycopyrolate. Patients were extubated once airway protective reflexes had returned.

The surgical procedures were performed by a single operator. Local anaesthesia with vasoconstrictor was administered to reduce bleeding in the operative field.

For the delayed group, a skin or mucosal incision was made followed by blunt dissection using an artery forceps. Pus was drained and a pus swab for microbial culture and sensitivity was taken and copious irrigation with normal saline was done. Drains were placed and secured with 3/0 silk sutures and where applicable, dry gauze dressing were placed. Medical treatment was carried out until sepsis had resolved. Open reduction and internal fixation with semi-rigid fixation, using 2 Synthes Matrix Mandible® 1.25mm plates, and a minimum of 4 screws per plate, was carried out within the three week post-injury period. Procedures are depicted in Figures 3-6.

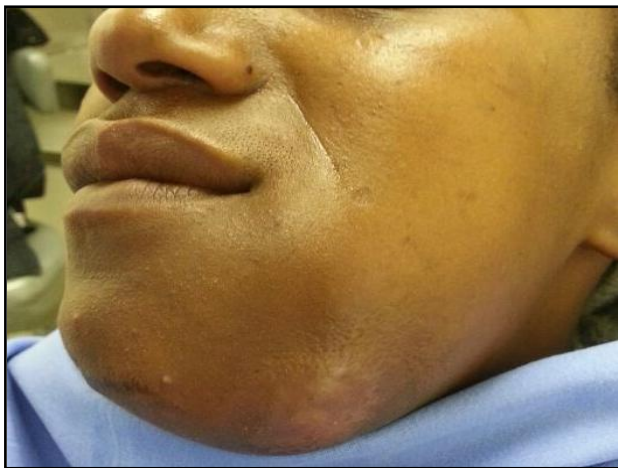

Figure 3. Left submandibular abscess

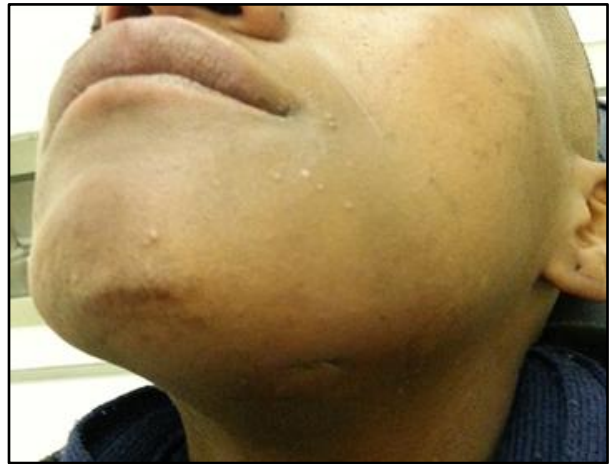

Figure 4. Post drainage of abscess

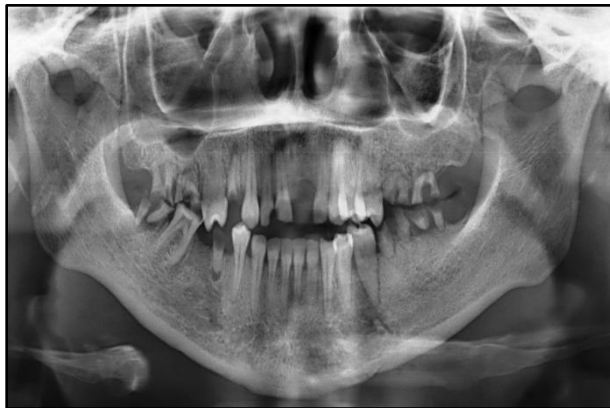

Figure 5. Pre-operative Orthopantomograph

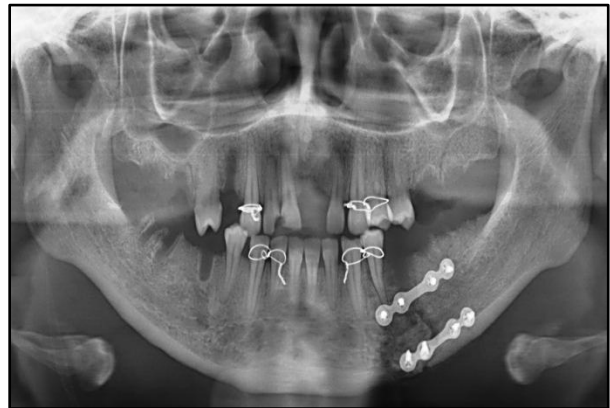

Figure 6. Post-operative Orthopantomograph

For the immediate group, incision and drainage was done as in the delayed group. Corrugated drain/s were placed and grossly carious teeth were extracted. A full mucoperiosteal flap was raised at the fracture site, exposing the fracture ends. Thereafter followed fracture debridement, where small bone and tooth fragments were removed using a universal scaler and an artery forceps. Irrigation with normal saline followed. Reduction of the fractured ends was done and where applicable, intermaxillary fixation used. Rigid fixation was employed using a Synthes Matrix Mandible<sup>®</sup> 1.5mm and 1.25mm plates, with a minimum of 4 screws per plate. No post-operative intermaxillary fixation was employed. Closure of the wound was done using 3/0 chromic sutures. Procedures are depicted in figures 7-10.



Figure 7. Left submasseteric abscess

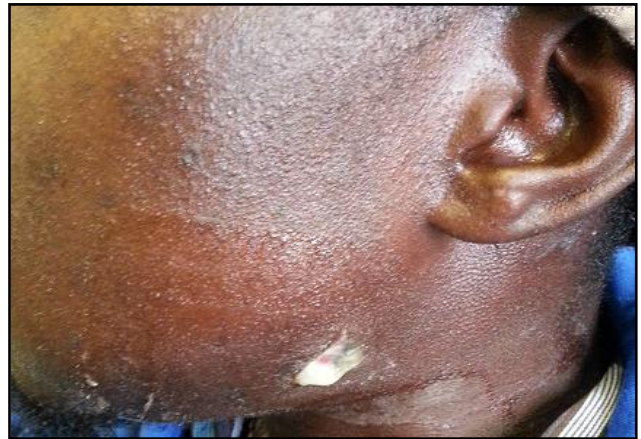

Figure 8. Draining sinus

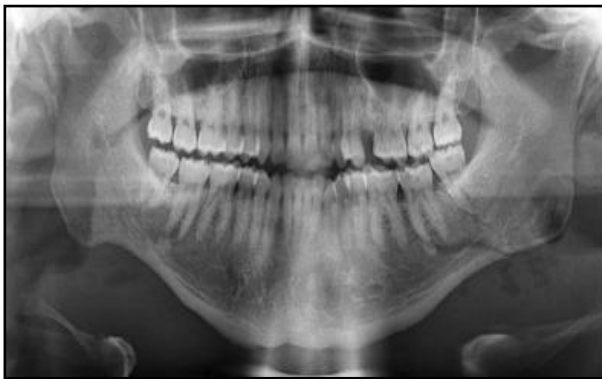

Figure 9. Pre-operative angle fracture

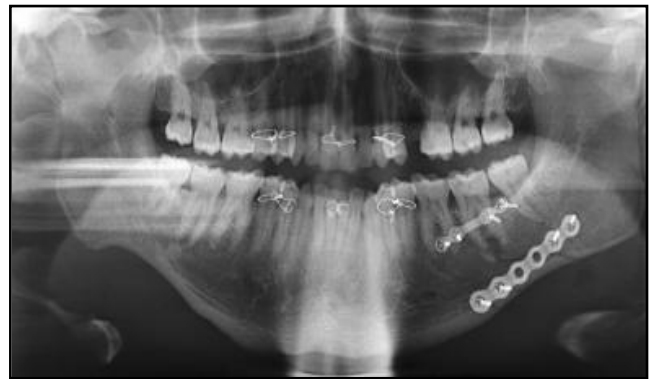

Figure 10. Post-operative ORIF angle fracture

The clinical parameters, e.g. temperature, blood pressure and pulse rate were measured at stipulated intervals pre- and post-operatively. The white cell count was assessed pre- and post-operatively. Both groups were assessed for pain both pre- and post-operatively. Fracture stability and fracture union were assessed clinically and radiographically post-operatively. The number of follow-up visits, surgical theatre time and hospital admission time was recorded.

The medical treatment involved analgesia and empiric antibiotic treatment:

- 1 g paracetamol orally 6-hourly for 5 days
- 400 mg Ibuprofen orally 6-hourly for 5 days
- 10 mg morphine IMI 6-hourly post-operatively
- 0.2% chlorhexidine gluconate mouth rinse - 15 ml rinse after meals
- Penicillin G 2.4-5 MU IVI and then oral 500 mg 8-hourly
- Metronidazole 500 mg IVI and then oral 400 mg 8-hourly
- If penicillin allergy - 300 mg clindamycin 6-hourly
- Antibiotic therapy was adjusted according to the culture and sensitivity of the pus swab

### **Criteria evaluated**

- Pain was measured using a visual analogue scale. Both groups were assessed for pain pre-operatively and then post-operatively on a daily basis while hospitalised. This assessment was performed 24 hours, 48 hours, 7 days and 3 weeks post-operatively.
- Temperature was recorded for each group. For each patient, body temperature was recorded 6-hourly.
- Blood pressure was recorded for each group. For each patient, blood pressure was recorded 6-hourly.
- Pulse rate was recorded for each group. For each patient, pulse rate was recorded at 6-hourly intervals.
- Post-operative fracture union was assessed clinically and radiographically. (Radiographic criteria were assessed by the researcher and these findings were then calibrated by a specialist radiologist.)
- Union and non-union was recorded as being present or not.

- Number of hospital follow-up visits was recorded
- Surgical time was recorded for each patient.
- Length of hospital admission was measured for each patient.

### **Data management and statistical analysis**

All data were collected and analysed statistically. The following tests were performed: Paired t-tests, Wilcoxon signed rank tests and Regression analysis.

### **Ethical statement**

The research protocol was presented to the Research Committee of the Faculty of Dentistry, UWC, for consideration for registration as an approved research project.

Patient participation in the project was on a voluntary basis. Each patient had the right to withdraw from the study at any stage and the latter would not prejudice the patient regarding further treatment at the facility in any way. Every patient was informed about the project and handed a formal information form. All patients were asked to give informed consent or refusal for the research project through a formal written consent procedure. Patient confidentiality was protected at all times. All information was stored in password protected computers and written information was stored in a locked office. All personal identifiers will be changed when the data is published.

Photographs were used with informed consent and eyes hidden.

### **Conflict of Interest Statement**

The investigator declares no conflict of interest.

### **Null Hypothesis**

There is no difference in mandibular fracture healing between the immediate and delayed surgical management of septic mandibular fractures.



## CHAPTER 5: RESULTS

This is a report of the findings of the comparative study between immediate and delayed surgical management of septic mandibular fractures. Comparison was made on surgical time, length of hospital admission, number of follow up visits, white cell count, fracture stability and fracture union.

### Response Rate

Twenty patients were divided into two groups, namely an immediate and a delayed group. These patients were selected randomly.

### Demographic Information

Gender: The sample was made up of 45% males and 55% and females with the gender distribution depicted in Graph 11.

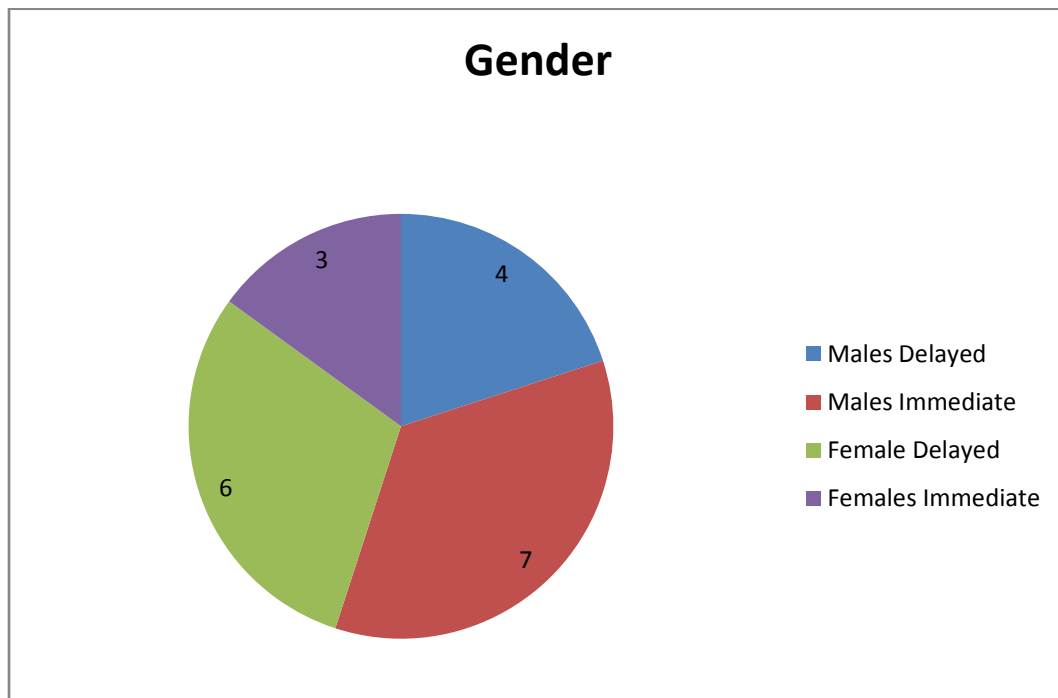


Figure 11. Graph depicting gender

Age (Graph 12): The mean age was 35.8 years (SD = 1.5). The mean age for the male sample was 34.78 years and 36.54 years for the females. Two thirds of the sample was forty years and younger.

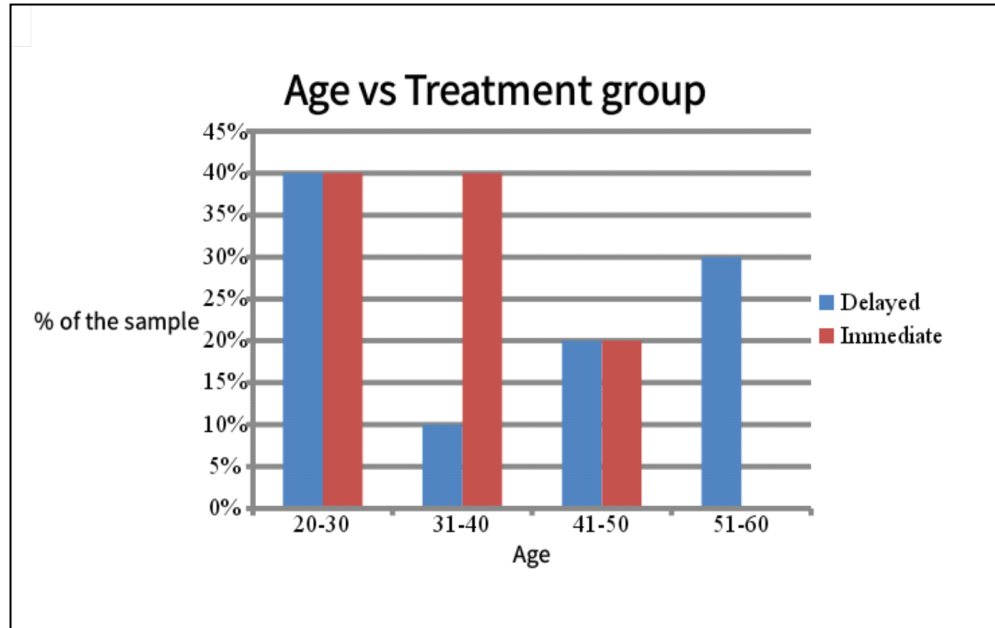


Figure 12. Graph depicting age

### Surgical time

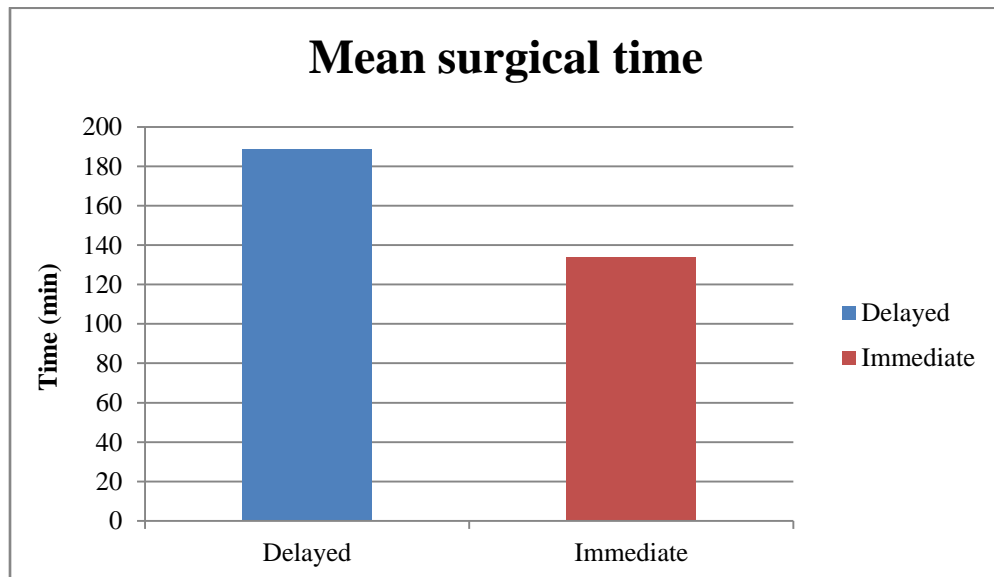


Figure 13. Graph depicting mean surgical time

In the delayed group the mean surgical time was significantly longer compared to the patients in the immediate group as depicted in Graph 13. For patients treated in the delayed group the mean surgical time was 188.5 minutes (SD = 2.1) whereas in the immediate group the mean surgical time was 134.0 minutes (SD = 20.6). The difference in the surgical time between the two groups was statistically significant (p-value = 0.0008).

**Length of Hospital Admission**

Days spent in hospital were recorded and the mean hospital admission period for the sample was 7.3 days. In the immediate group patients spent 5.3 days (SD 0.67) in hospital compared to 9.3 days (SD = 1.06) for those in the delayed group. There was thus a significant difference in the duration of hospital admission (P – value 0.0001) between the two groups.

**Follow-up Visits**

All patients involved in the study had three follow-up visits at three weeks, six weeks and three months. There was no difference in the number of follow up visits for the two respective groups.

**Fracture Stability**

All participants in both groups recorded fracture stability at 6 weeks and 3 months. Therefore there was no difference in fracture stability between the two treatment approaches depicted in Table 1.

**Fracture union**

All participants in both groups recorded fracture union at 6 weeks and 3 months (Figures 14 &15). Therefore there was no association between fracture union and treatment approach. Therefore there was no difference in fracture union between the two treatment approaches as depicted in Table 2.

**Table 2**

	<b>Treatment Group</b>	
	<b>Delayed</b>	<b>Immediate</b>
Fracture union 6 weeks	100%	100%
Fracture union 3 months	100%	100%
Fracture stability 6 weeks	100%	100%
Fracture stability 3 months	100%	100%

Figure 14. ORIF at 6 weeks post-op

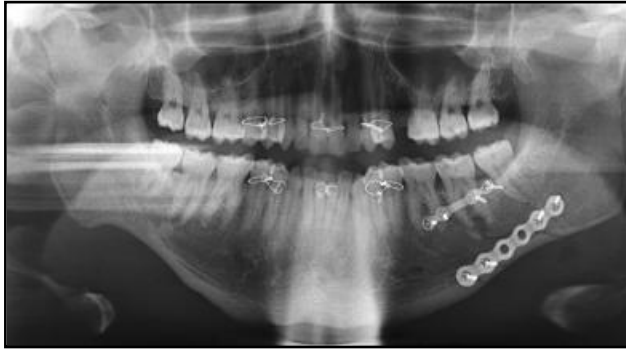

Figure 15. ORIF at 3 months post-op

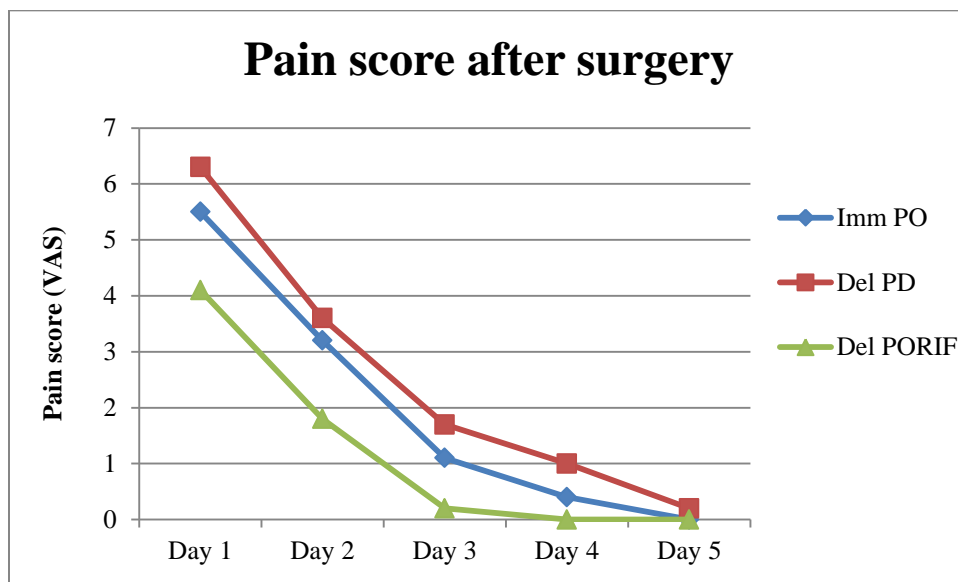
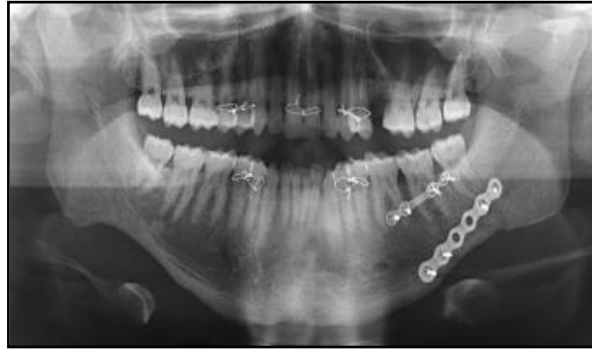

Figure 16. Pain score after surgery

### Pain

There was no statistically significant difference in post-operative pain between the two groups as depicted in Figure 16.

### Temperature

Body temperature gradually came down post-operatively in both groups as depicted in Figure 17. Temperature normalized quicker in the immediate group (post-operatively) compared to the delayed group (post-incision and drainage).

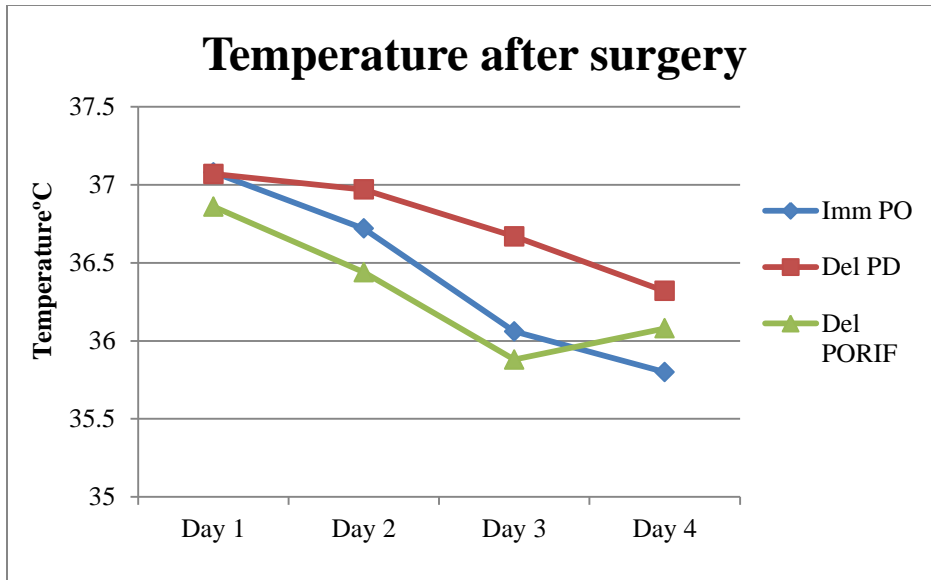


Figure 17. Temperature after surgery

### Pulse

Pulse differences between the two groups were not statistically different from day one to day four post-operatively (Figure 18).

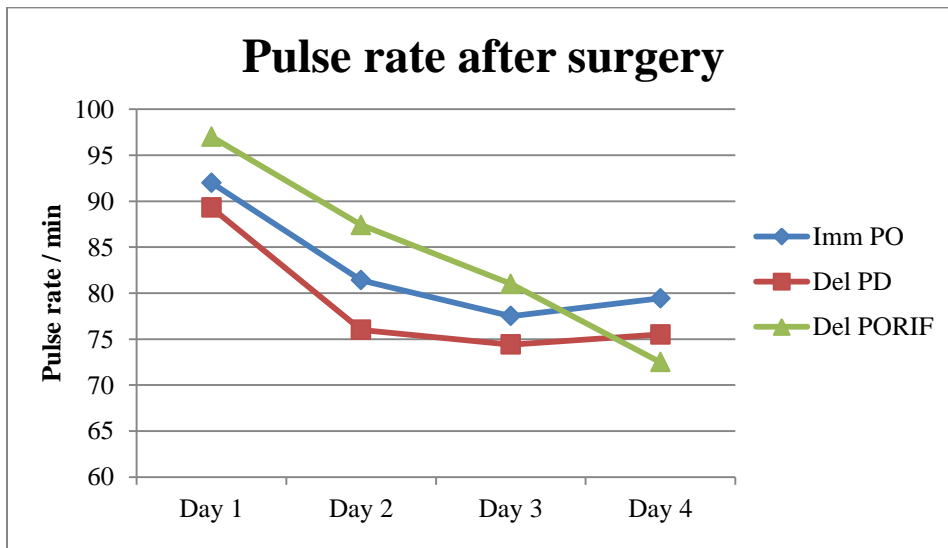


Figure 18. Pulse rate after surgery

## CHAPTER 6: DISCUSSION

Placement of hardware in septic fractures has been done by orthopaedic and oral and maxillo-facial surgeons in the past. There are, however, surgeons who still believe that hardware should not be placed in septic mandibular fractures. This study proved that rigid internal fixation with plates and screws is a viable alternative to the conventional delayed approach as there were no difference found between fracture union and stability in the two treatment groups.

Findings in this study represent differences between immediate and delayed surgical management of septic mandibular fractures. No statistically significant findings were made in the analysis of the demographic data and clinical parameters relating to the sepsis. The only significant data were related to the surgical time and hospital time. It was found that the advantages of the immediate approach versus the delayed approach related only to shorter surgical time and less days spent in hospital for the immediate approach.

Alternative to the classical delayed approach, an immediate approach can be followed. The following treatment protocol for the management of septic mandibular fractures is proposed as follows:

- obtaining patient medical history
- physical examination
- employing diagnostic aids such as orthopantomograph, posterior-anterior mandible and CT scan
- diagnosis
- where possible to do MCS before commencement of antibiotics
- commencement of empirical intravenous antibiotics
- incision and drainage, with MCS
- debridement and immediate open reduction and rigid internal fixation
- administering post-operative empirical intravenous antibiotics and adjust accordingly to sensitivity.

- diet, oral hygiene and physiotherapy instructions

The hardware of choice for the immediate approach would be 2 plates, with at least one being a 1.5 mm Matrix<sup>®</sup> (Synthes<sup>®</sup>) mandible plate. A Minimum of 4 screws per plate is advised. Similar hardware can be used as long as it provides rigid fixation of the mandible.

The empiric antibiotics of choice are penicillin and metronidazole. For penicillin-allergic patients, clindamycin is recommended. Cloxacillin is empirically added if staphylococci infection or contamination that produces beta-lactamase is suspected.

Post-operative empirical antibiotics should be continued. The antibiotic regimen is subsequently modified according to the clinical response and results of culture and sensitivity testing.

Drains should be removed after 48 hours or as soon as there is no clinical evidence of pus. If pus drainage persists, reassess and consider a contrasted CT scan to the incision and drainage and re-fix the fracture emphasizing thorough debridement of the fracture site.

Patients should be re-evaluated post-operatively at 3 weeks, 6 weeks and 3 months. This evaluation should be done through clinical examination of the fracture site for fracture stability and union. Union should be confirmed by radiographs or imaging.

The delayed surgical management of a septic mandibular fracture remains a viable option. This approach is useful especially if a theatre is not available, incision and drainage can be done under local anaesthetic and fixation can be accomplished at a later stage when an operating theatre is available. Rigid or semi-rigid fixation can then be employed with or without intermaxillary fixation.

One of the critical factors in the study was that the plates used in the immediate group involved one 1.5mm and one 1.25mm plate and not a reconstruction plate. Optimal stability and union was achieved with this protocol.

Although no patient in the study required bone grafting, the literature would indicate the immediate autogenous particulate marrow bone grafting of infected mandibular fractures, when used in conjunction with rigid internal fixation and appropriate intraoperative debridement, is an effective treatment modality with predictable, favorable outcomes in patients who are not immuno-compromised. Such protocols are advocated by the AO Foundation. Such a single surgical procedure would then dramatically shorten the course of treatment both in terms of surgical time and hospital admission days.

## **CHAPTER 7: CONCLUSION**

Septic mandibular fractures can be managed either by an immediate or a delayed approach. The immediate surgical approach seems to have an advantage over the delayed approach regarding the surgical time and hospital admission days.

Although the study had limited clinical cases, the results supports the scientific literature in that fracture union and fracture stability can be achieved by both approaches as long as adequate debridement of the fracture site is performed and antibiotic cover is given.

Future studies might explore the option to used only two miniplates vs. a reconstruction plate in the immediate approach.



## REFERENCES

Ajmal, S., Khan, M.A., Jadoon, H., Malik, S.A. 2007. Management protocol of mandibular fractures at Pakistan Institute of Medical Sciences, Islamabad, Pakistan. *J Ayub Med Coll Abbottabad*, 19(3):51-5.

Alpert, B., Kushner, G. 2008. Contemporary Management of Infected Mandibular Fractures, *Craniofacial Trauma Reconstruction*, 1:25–30.

Cienfuegos, R., Cornelius, C., Ellis, E., Kushner, G. AO Foundation - Official Site, AOCMF, <https://www.aofoundation.org>

Beckers, L. 1979. Treatment of initially infected mandibular fractures with bone plates. *J Oral Surg*, 37:310–313.

Benson, P., Marshall, M., Engelstaad, M. 2006. The use of immediate bone grafting in reconstruction of clinically infected mandibular fractures: Bone grafts in the presence of pus. *J Oral Maxillofac Surg*, 1:122.

Burri, C. 1975. *Post-Traumatic Osteomyelitis*. Bern, Hans Huber, 19-125.

Cawood, J. 1985. Small plate osteosynthesis of mandibular fractures. *Br J Oral Maxillofac Surg*, 23:77.

Champy, M., Lodde, J.H., Must, D. 1978. Mandibular osteosynthesis by miniature screwed plates via buccal approach. *J Oral Maxillofac Surg*, 6:14-21.

Chole, R.A., Yee, J. 1987. Antibiotic prophylaxis for facial fractures. *Arch Otolaryngol*, 113:1055.

Dahl-Iverson, E. 1928. On the frequency and the duration of osteitis after osteosynthesis illustrated by 274 cases and re-examination of 66 cases of operatively treated fractures. *Acta Chir Scand*, 63:41.

Ellis, E. 2003. Treatment considerations for comminuted mandibular fractures. *J Oral Maxillofac Surg*, 61:861-870.

Friedrich, B., Klaue, P. 1977. Mechanical stability and post-traumatic osteitis: An experimental evaluation of the relation between infection and internal fixation. *Injury*, 9: 23–29.

Gabrielli, M.A., Marcantonio, E., Hochuli-Vieira, E. 2003. Fixation of mandibular fractures with 2.0-mm miniplates: review of 191 cases. *J Oral Maxillofac Surg*, 61:430–436.

Garner, J.S. 1986. CDC guideline for prevention of surgical wound infections, 1985. Supersedes guideline for prevention of surgical wound infections published in 1982. *Infect Control*, 7(3):193-200.

Gristina, A. 1983. Current concepts review-Total joint replacement and sepsis. *J Bone Joint Surg[Am]*, 65:128.

Hardman, F. 1982. The treatment of maxillofacial injuries in Great Britain in 1980. *Int. J. Oral Surg*, 11:145.

Hicks, H.I. 1964. Amputations in fractures of the tibia. *J Bone Joint Surg Br*, 46:388.

Insall, J., Scott, W.N., Ranawat, C.S. 1979. The total condylar knee prosthesis. *J Bone Joint Surg Am*, 61:173.

Jimson, S. 2010. Teeth in the line of fracture: To retain or remove? *Craniomaxillofac Trauma Reconstruction*, 3:177–184.

Johansson, B., Krekmanov, L., Thomsson, M. 1988. Miniplate Osteosynthesis of Infected Mandibular Fractures. *J Cranio-Max-Fac Surg*, 16:22-27.

Kai Tu, H. 1985. Compression osteosynthesis of mandibular fractures: A retrospective study. *J Oral Maxillofac Surg*, 43:585.

Kamboozia, A.H., Punnia-Moorthy, A. 1993. The fate of teeth in mandibular fracture lines. A clinical and radiographic followup study. *Int J Oral Maxillofac Surg*, 22:97–101.

Kaufer, H., Matthews, L.S. 1981. Sphero-centric arthroplasty of the knee. *J Bone Joint Surg Am*, 63:545.

Kellman, R. 1984. Repair of mandibular fractures via compression plating and more traditional techniques: A comparison of results. *Laryngoscope*, 94:1560.

Koury, E., Perrott, H., Kaban, B. 1994. The use of rigid internal fixation in mandibular fractures complicated by osteomyelitis. *J Oral Maxillofac Surg*, 52:1114–1119.

Koury, M., Ellis, E. 1992. Rigid internal fixation for the treatment of infected mandibular fractures. *J Oral Maxillofac Surg*, 50:434–443.

Laskin, D. 2003. The use of prophylactic antibiotics for the prevention of postoperative infections. *Oral Maxillofacial Surg Clin N Am*, 15:155–160.

Lizuka, T., Lindqvist, C., Hallikainen, D. 1991. Infection after rigid internal fixation of mandibular fractures: a clinical and radiographic study. *J Oral Maxillofac Surg*, 49:585– 593.

Macausland, W.R., Eaton, R.G.1979. The management of sepsis following intramedullary fixation for fracture of the femur. *J Bone Joint Surg Am*, 45:1643.

Maloney, L., Lincoln, E., Coyne, P. 2001. A protocol for the management of compound mandibular fractures based on the time from injury to treatment. *J Oral Maxillofac Surg*, 59:879–884.

Malanchuk, V. 2007. Risk factors for development of infection in patients with mandibular fractures located in the tooth-bearing area. *Journal of Cranio-Maxillofacial Surgery*, 35:57–62.

Mehra, P., Van Heukelom, E. 2009. Rigid internal fixation of infected mandibular fractures. *American Association of Oral and Maxillofacial Surgeons. J Oral Maxillofac Surg*, 67:1046-1051.

Meyer, S., Weiland, AJ., Willenegger, H. 1975. The treatment of infected non-union of fractures of long bones. *J Bone Joint Surg*, 57:836.

Nicoll, E.A. 1964. Fracture of the tibial shaft. *J Bone Joint Surg*, 46:373.

Nishioka, G. 1966. The Role of bacterial-laden biofilms in infections of maxillofacial biomaterials. *J Oral Maxillofac Surg*, 46:19-E.

Prein, J., Beyer, M. 1990. Management of infection and nonunion in mandibular fractures. *Oral Maxillofac Surg Clin North Am*, 2:187–194.

Rittmann, W.W., Perren, S.M. 1974. Cortical Bone Healing after Internal Fixation and Infection. New York, NY, SpringerVerlag.

Samson, J. 2010. Teeth in the Line of Fracture: To Retain or Remove? *Craniofacial Trauma Reconstruction*, 3:177–184.

Schilli, W. 1977. Compression osteosynthesis. *J Oral Surg*, 35:802.

Sheehan, J. 1978. Arthroplasty of the knee. *J Bone Joint Surg [Br]*, 60:333.

Souyris, F., Lamarche, J.P., Mirfakhra, A.M. 1980. Treatment of mandible fractures by intraoral placement of bone plates. *J Oral Surg*, 38:33.

Spiessl, B. 1989. Internal Fixation of the Mandible: A Manual of AO/ASIF Principles, Berlin: Springer-Verlag, p246, 284–289, 617.

Strelzow, V., Strelzow, A. 1983. Osteosynthesis of mandible fractures in the angle region. *Arch Otolaryngol*, 109:403.

**Annexure 1: Consent form**

**Consent form**



**Department of Maxillo-Facial and Oral Surgery  
Faculty of Dentistry and WHO Oral Health Collaborating Centre  
University of the Western Cape  
Cape Town**

I, Mr/Mrs/Miss .....

Date of Birth: ..... File no./Hosp. Sticker

Am willing to participate in the study as describe to me in the patient information letter by Dr L Mdlalose. I understand that participation in the study is voluntary.

The study is approved by the Ethical and Research Committee of the University of the Western Cape and participation in this study is on a voluntary basis. I have been adequately informed about the objectives of the study.

I also know that I have the right to withdraw from the study at any stage which will not prejudice me in any way regarding future treatments. My rights will be protected and all my details will be kept confidential. No personal information will be published.

I hereby consent to be part of the research/study.

Patient's/patient's parent or guardian's name: .....

Patient's/patient's parent or guardian signature: .....

Witness name: .....

Witness signature: .....

Researcher's signature: .....

Dr L. Mdlalose

Date: .....

**Annexure 2: Patient information letter**

**Patient Information Letter**



UNIVERSITY of the  
WESTERN CAPE

**Department of Maxillo-Facial and Oral Surgery  
Faculty of Dentistry and WHO Oral Health Collaborating Centre  
University of the Western Cape  
Cape Town**

I, Dr L. Mdlalose (currently a qualified dentist enrolled in a specialist training program), plan to conduct a clinical study comparing delayed and immediate management of infected mandibular fracture. In South Africa we normally treat infected jaw fractures, where possible, with drainage of pus and wiring of together of the jaws for 6 weeks. Using another treatment method, we can place 2 plates over the infected fracture, the plating operation will obviously then take longer and might be more difficult, but additional wiring of the jaws will not be necessary. Currently both these methods are acceptable surgical management for infected jaw fractures. We would like your help to compare these two methods by comparing body temperature, heart rate, blood pressure, pain, presence of pus, fracture stability and fracture union.

All patients will undergo clinical examination, X-ray examination and operation which are normal procedure. Operation will include extraction of rotten teeth, plating of the fracture(s) and jaw wiring for one group and the other group will receive two plates over the infected fracture without any jaw wiring. None of these procedures are experimental and both options are routinely used. The patients will be divided randomly into two equal groups: so you will not be able to choose which operation you will receive. Participating in the study is on a voluntary basis. You may withdraw from the study at any time. Participating in the study or refusing to participate will not harm or prejudice you in any way. Participating in the study will definitely benefit future patients. All information will be kept strictly confidential.

Thanking you in anticipation.

Dr L Mdlalose (Researcher)

Registrar (Maxillo-Facial and Oral Surgery)

Department of Maxillo-Facial and Oral Surgery

Oral Health Centre Tygerberg

Contact details: Tel: (021) 9373119

Mobile: 0789044214

I, (Patient name) ....., fully understand the information supplied to me by Dr L Mdlalose in the above information letter.

Signature: .....Date: .....If you want any more information, you are welcome to contact my supervisor, Prof Morkel, at: jamorkel@uwc.ac.za or 021 9373087

### Annexure 3: Data capturing sheet

#### Delayed Group

Patient Name/ sticker

#### Pre-Operative (Admission)

	Day 1	Day 2	Day 3	Day 4	Day 5	Day 6	Day 7	3 weeks
Date								
Temperature								
Pulse								
BP								
White cell count								
Pain								
Pus Y/N								
Hosp. admission								
Surgical time								

#### Post-drainage

	Day 1	Day 2	Day 3	Day 4	Day 5	Day 6	Day 7	Day 8
Date								
Temperature								
Pulse								
BP								
White cell count								
Pain								
Pus Y/N								
Hosp. admission								
Surgical time								

#### Post-ORIF

	Day 1	Day 2	Day 3	Day 4	Day 5	Day 6	Day 7	3 week	6 weeks	3 month
Date										
Temperature										
Pulse										
BP										
White cell count										
Pain										
Pus Y/N										
Hosp. admission										
Surgical time										

Fracture Union	6 week	3 months
Yes		
No		
Fract stability	6 week	3 months
Yes		
No		

Total Hospital Admission time in days =

Total Surgical theatre time in hours =

Total follow-up visits / per visit =

Other comments: