

# Post-operative computed tomography scans in severe cervicofacial infections

Yanga Ngcwama  
9508272



UNIVERSITY *of the*  
WESTERN CAPE

Supervisor:  
Prof JA Morkel

# CONTENTS

Title	3
Declaration	4
Acknowledgements	5
Dedication	6
List of abbreviations	7
Key words	7
Abstract	8
List of tables	9
List of figures	10
<b>1. Introduction</b>	<b>11</b>
<b>2. Literature review</b>	<b>12</b>
<b>3. Aims and objectives</b>	<b>24</b>
<b>4. Materials and methods</b>	<b>25</b>
<b>5. Results</b>	<b>28</b>
<b>6. Discussion</b>	<b>34</b>
<b>7. Conclusion</b>	<b>37</b>
<b>8. References</b>	<b>38</b>
<b>9. Annexures</b>	
Annexure 1: Patient Information Letter	41
Annexure 2: Consent Form	42
Annexure 3: Patient Consent to Clinical Photography	43
Annexure 4: Data Capturing Sheet	44



**TITLE**

**Post-operative computed tomography scans in severe  
cervicofacial infections**

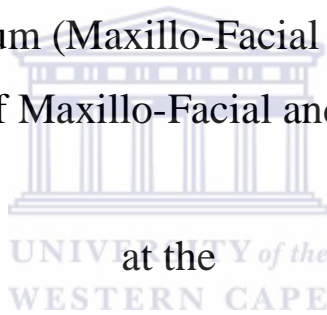
By

**Yanga Ngcwama**

Submitted in partial fulfillment (mini-thesis) for the Magister

Chirurgiae Dentium (Maxillo-Facial and Oral Surgery)

Department of Maxillo-Facial and Oral Surgery



Faculty of Dentistry

University of the Western Cape

June 2015

# DECLARATION

I, **Yanga Ngcwama**, declare that this mini-thesis is my own work, that all sources I have quoted have been indicated and acknowledged by means of references, and that it has not been presented for any other degree at any university:

The logo of the University of the Western Cape, featuring a classical building with columns and a pediment, is positioned to the left of a handwritten signature in black ink. The signature is written over a light-colored rectangular background.  
**Signed:**  
UNIVERSITY *of the*  
WESTERN CAPE

**Date: 08 October 2015.**

Department of Maxillo-Facial and Oral Surgery

Faculty of Dentistry


University of the Western Cape

South Africa

## ACKNOWLEDGEMENTS

I wish to acknowledge my sincere gratitude to the following individuals for their assistance in this research project.

- (1) Professor J.A. Morkel, for going more than an extra mile in assisting his registrars with their training and their research projects. Long Live.
- (2) Professor G. Kariem and Dr G.J. Hein, for their support with the project.
- (3) Dr D. Smit, for his assistance with the processing of the data and the statistics. A great colleague and a gentleman.
- (4) Ms C. Marlow, for her invaluable assistance in accessing hospital records.
- (5) Mrs J. de Wet, for her proficient assistance with word processing.
- (6) All my consultants and fellow registrars for their advice and constant support.
- (7) The nursing and supporting staff at both Tygerberg and Groote Schuur Hospitals for their constant support and encouragement.
- (8) The many patients who made my training and this study possible.
- (9) A special expression of gratitude to all those individuals whom I have omitted. Your contribution to my training is invaluable.



## DEDICATION

To my family and friends, for their unconditional love and support throughout my training.



*Non nobis Domine, non nobis, sed nomini tua da gloriam* (Not unto us O Lord,  
not unto us, but unto thy Name give glory)  
Motto of the Knight Templars

## **LIST OF ABBREVIATIONS**

CECT: contrast enhanced computer tomogram

CT: computer tomogram

MCS; microscopy, culture and sensitivity

MRI: magnetic resonance imaging

MU: mega units

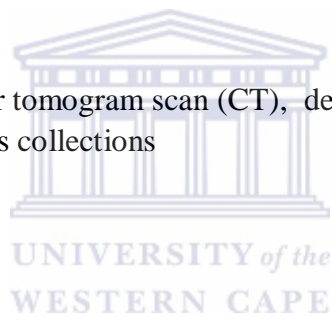
RVD: retroviral disease

U&E: urea and electrolytes

US: ultrasonography

## **KEY WORDS**

cervicofacial infections, computer tomogram scan (CT), deep neck abscesses, contrast enhanced CT, surgical drains, pus collections



# ABSTRACT

## Purpose

To assess the value of postoperative CT scans in the management of severe cervicofacial infections or deep neck abscesses.

## Patients and Methods

Thirteen patients underwent post-operative contrast enhanced CT scans after initial incision and drainage followed by a tracheostomy. As per surgical protocol, the CT scans were taken with radiopaque surgical drains in situ from the brain down to the mediastinum and chest/lungs. Data were collected on the presence of abscesses, their location, the location of surgical drains and presence of other pathology.

## Results

The most common initially affected space was the submandibular space (69%), followed by the submental space (62%). Almost half of the cases studied had two spaces affected and slightly less than a third had three spaces affected. Slightly more than half (54%) of the patients were in good health generally. More than a third (38.5%) of the patients were HIV positive, and thus immuno-compromised. The mean time lapse between the CT and surgery was 2.61 days (SD = 1.56). In the majority (69.23%) of post-operative scans a residual pus collection was found. In just over a quarter (30.8 %) of the patients no residual pus collection was detected on the postoperative CT scan, while in seven patients (53.8%) affected fascial spaces were missed by the surgeon. These spaces included the submasseteric, anterior mediastinum and parotid spaces. Almost half (44.15%) of the patients required a repeat incision and drainage.

## Conclusion

This study demonstrates clinical value of post-operative CT scans in severe cervicofacial infections. This study also advances the argument for acquisition of preoperative CECT scans for all patients with severe cervicofacial infection.



## LIST OF TABLES

Table 1. Demographic information and clinical diagnosis

Table 2. Fascial spaces affected on admission

Table 3. Mean values of laboratory results

Table 4. Comparison of clinical pre-operative pus collections and post-operative pus collections as viewed on CT scans.

Table 5. Surgical drains in situ compared to pus collection detected on postoperative CT scans



## LIST OF FIGURES

Figure 1. Fascial layers of the retropharyngeal space

Figure 2. Four-Step Interpretive Approach to retropharyngeal Space Collection on Multiplanar Imaging

Figure 3. Greyscale US showing an abscess as a no-colour signal and facial artery shown as a colour flow signal

Figure 4: Clinical diagnosis of sample on admission (in percentages)

Figure 5: Anatomical locations of pre-operative pus collections as a percentage of total number of patients

Figure 6: A post-operative CT scan image showing buccal a space pus collection



# CHAPTER 1

## INTRODUCTION

Advanced imaging studies, such as contrast enhanced computed tomography scans (CT), are routinely used in the pre-surgical diagnosis of severe cervicofacial infections, especially those that have spread to deep fascial spaces of the neck. Often, associated upper airway compromise would necessitate immediate surgery before advanced imaging can be employed. Localised infections confined to the oral cavity do not usually require special imaging, however, in patients where infection has not resolved following incision, drainage and antibiotic therapy, a contrast enhanced CT scan is indicated.

The researcher reviewed the post-operative CT scans of patients with severe cervicofacial infections to assess if pus drainage was optimal and whether any residual pus collections were present with a view to critically comment on the value and use of post-operative CT scans in severe cervicofacial infections.

## CHAPTER 2

### LITERATURE REVIEW

Deep neck abscesses develop within deep neck spaces. Deep neck spaces are regions of loose connective tissue between layers of deep cervical fascia. Although the fascial layers separate one area from another, the spaces of the neck communicate with one another forming pathways by which infections may spread between spaces (Boscolo-Rizzo et al., 2006). Deep neck abscesses can arise from various head and neck areas, including the teeth, salivary glands, nasal cavity, paranasal sinuses, pharynx and adenotonsillar tissues. The most common cases are of dental or tonsillar origin (Wang, 2003).

### FASCIAL PLANES OF THE NECK

Fascial planes both direct and confine the spread of sepsis (Fagan and Morkel, 2014). It is therefore important to have an understanding of the fascial planes and fascial spaces of the head and neck region. The cervical fascia is classified into superficial and deep cervical fascia. This is further broken down as follows:

- 1) Superficial cervical fascia
  
- 2) Deep cervical fascia
  - *Superficial (investing) layer*
  - *Middle layer*
    - Muscular layer
    - Visceral layer
  - *Deep layer :*
    - Alar fascia
    - Prevertebral fascia

## **Superficial Cervical Fascia**

The superficial cervical fascia is very thin and delicate fascia and is located just deep to the skin. It envelops the muscles of the head and neck including the platysma, and the muscles of facial expression. It is so thin that it can be difficult to identify when incising the neck. It extends from the epicranium above to the axillae and upper chest below and includes the superficial musculo-aponeurotic system (SMAS). The space deep to the superficial cervical fascia contains fat, blood vessels, nerves and lymphatics. Abscesses located either superficial to or within the tissue space immediately deep to the superficial cervical fascia are treated by simple incision and drainage.

## **Deep Cervical Fascia**

The deep cervical fascia envelops the deep neck spaces and an understanding of its anatomy is key to managing deep neck sepsis. It comprises of three layers namely a superficial, middle, and a deep layer.

The superficial layer, also known as the investing layer, surrounds the neck and envelops the muscles of mastication i.e. the masseter, buccinator, digastric and mylohyoid.

The middle layer of deep cervical fascia extends superiorly from the skull base along the carotid sheath to the pericardium. It has muscular and visceral layers. The muscular layer envelops the infrahyoid strap muscles (sternohyoid, sternothyroid, omohyoid, and thyrohyoid), the carotid artery and internal jugular vein (carotid sheath). The visceral layer lies deep to the infrahyoid muscles, and splits to enclose the thyroid, trachea, pharynx and oesophagus.

The deep layer encircles the prevertebral and paraspinal muscles, and also contributes to the carotid sheath. It is divided into prevertebral and alar fasciae. The prevertebral fascia attaches to the vertebral bodies in the midline, and extends laterally over the prevertebral muscles to attach to the transverse processes of the vertebrae, and then envelops the paraspinal muscles to meet with the superficial layer of deep cervical fascia at the ligamentum nuchae in the midline posteriorly. It extends from the base of the skull to third thoracic vertebra. It covers the floor of the posterior triangle of the neck. Inferiorly it constitutes the fascial covering over the brachial plexus from where it extends laterally as the axillary sheath to encase the axillary vessels and brachial plexus.

The alar fascia is interposed between the prevertebral and visceral fasciae and forms the posterior wall of the retropharyngeal space. It extends between the transverse processes from the skull base to the superior mediastinum where it merges with the visceral layer of deep fascia on the posterior surface of the oesophagus at the level of the second thoracic vertebra, thereby terminating the retropharyngeal space inferiorly.

## **DEEP SPACES OF THE NECK**

The deep fasciae create clinically relevant deep neck spaces, some of which interconnect with one another. Some are potential spaces and become apparent only when distended by pus (abscess) or air (surgical emphysema). The terminology and classifications of deep neck spaces used in the literature are not entirely consistent.

Fagan and Morkel (2014) presented the following classification (working from cephalad to caudad):

### **I. Facial region**

- a. Buccal space
- b. Canine space
- c. Masticator space
  - i. Masseter space
  - ii. Pterygoid space
  - iii. Temporal space
- d. Parotid space



### **II. Suprahyoid region**

- a. Sublingual space
- b. Submental space
- c. Submandibular space
- d. Parapharyngeal space
- e. Peritonsillar space

Ludwig's Angina is the involvement of the sublingual, submental and submandibular spaces.

### III. Infrahyoid region: Pretracheal space

### IV. Entire Neck

- a. Retropharyngeal space
- b. Danger Space
- c. Carotid Space
- d. Prevertebral Space

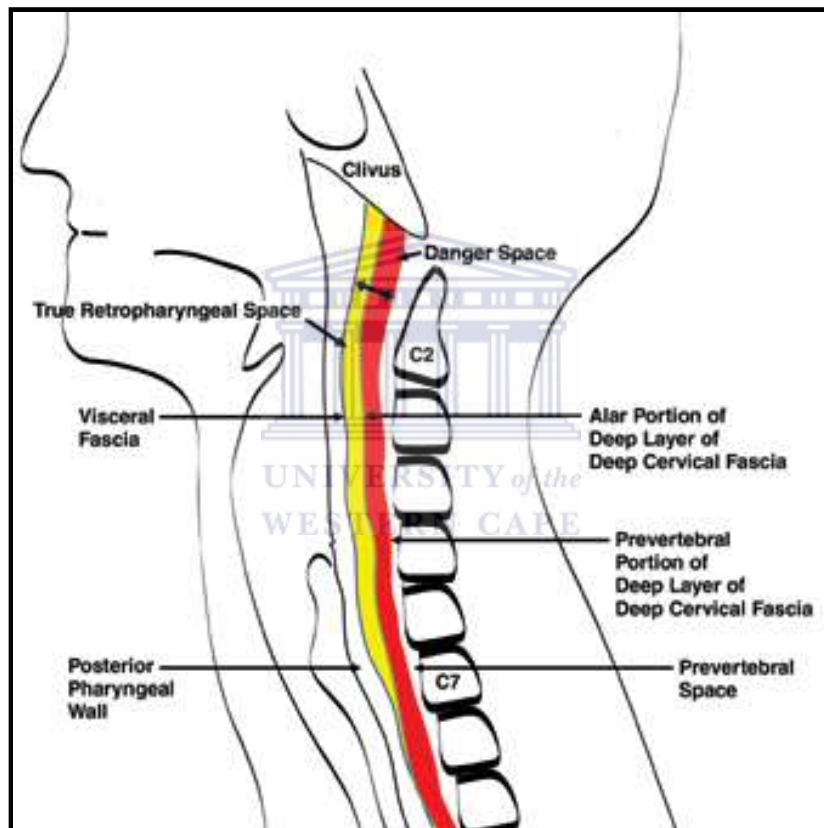


Figure 1. Fascial layers of the retropharyngeal space (Hoang et al., 2011)

It is difficult to clinically distinguish infection of the danger space from infection of the retropharyngeal space. Contrast-enhanced CT scans may also not adequately differentiate between infection of the retropharyngeal and danger spaces, but extension below T4 suggests involvement of the danger space. The accurate diagnosis of retropharyngeal abscesses will help triage patients for treatment. Hoang et al. (2011) recommend a four step approach to multiplanar imaging assessment, as illustrated below.

Step	Retropharyngeal Edema	Suppurative Retropharyngeal Node	Retropharyngeal Abscess
Fluid distribution	Fills the retropharyngeal space from side to side	Unilateral	Fills the retropharyngeal space from side to side
Configuration and mass effect	Axial images show ovoid, rectangular, or "bow-tie" configuration; sagittal images show diffuse configuration with tapered inferior and superior margins; mild mass effect	Rounded or ovoid configuration; mass effect varies	Rounded or ovoid configuration; moderate-to-marked mass effect
Thick enhancing wall	No	Can have an enhancing wall	Most have an enhancing wall
Ancillary findings	Neck infection adjacent to the retropharyngeal space or suppurative retropharyngeal node; internal jugular vein thrombosis; focal calcification anterior to C1–C2; other inflammatory signs of radiotherapy	Primary infectious source such as otitis media or tonsillitis; retropharyngeal edema is a common associated finding	Primary infectious source such as otitis media or tonsillitis; presence of a foreign body in traumatic causes; complications in the airway, mediastinum, or vessels

Figure 2. Four Step Interpretive Approach to retropharyngeal Space Collection on Multiplanar Imaging (Hoang et al., 2011)

## DIAGNOSIS OF DEEP NECK ABSCESSSES

Deep neck space abscesses, in contrast to superficial neck abscesses, are difficult to diagnose early (Larawin et al., 2006). A delay in diagnosis and treatment can result in life-threatening complications, such as, airway compromise, jugular vein thrombosis, mediastinal involvement, pericarditis, pneumonia, emphysema, arterial erosion, and extracranial and intracranial extensions (Larawin et al., 2006). Other potential complications are adult respiratory distress syndrome (ARDS), septic shock, and disseminated intravascular coagulopathy (DIC) (Huang, 2004). Complications are likely to occur in older patients with systemic diseases, and immuno-compromised patients (Huang, 2004).

Topazian et al. (2002) state that a CT is probably the most widely used advanced imaging modality in the evaluation of deep fascial space infections. It can provide information about the extent of soft tissue involvement, the extent of the inflammatory process and its probable epicentre, differentiate between myositis-fasciitis (cellulitis) and abscess formation, and demonstrate the status of the airway and involvement of the lymph nodes. The differentiation between an abscess and cellulitis is important because an abscess requires immediate surgical drainage, whereas cellulitis may respond to appropriate antibiotic therapy only. The CT scan



can also provide valuable information about the status of adjacent osseous structures and may demonstrate early signs of osteomyelitis.

Fagan and Morkel (2014) further state that more advanced imaging techniques such as contrast enhanced CT (CECT) or magnetic resonance imaging (MRI) scans may be useful in the diagnosis and management of more complex cases of cervicofacial sepsis. Topazian et al. (2002) recommended that axial CECT should be performed in the axial plane in 5 mm increments through all involved fascial spaces and the major lymph node chains receiving drainage from the head and neck. If there is suspicion of mediastinal involvement, then the mediastinum must be covered in the area to be scanned.

CT scanning utilizes the same ionising x-rays as plain film radiography, except that the x-ray is a thin, collimated linear beam, single but more often multiple (Lee et al., 2003). In plain film, a single beam which disperses outward is used. In CT the beam attenuated by the object being studied is detected by a crystal detector and converted to electrical energy. The final picture is a reconstructed computer simulation. In plain film the beam strikes a photo-emulsion silver-based film, causing a chemical reaction, which can then be processed into a picture. The CT is therefore not a real image of a real object, whereas the plain film x-ray is. Despite this, the CT still accurately reflects the real anatomy of the object being studied. CT takes thousands of small images in contrast to the one shot in plain film, but the amount of radiation exposure is about equal to or less than that of plain film x-rays, because the CT beam is very thin.

The advent of contrast-enhanced CT has made a critical contribution to the identification of an abscess, to differentiation of a deep neck abscess from cellulitis, to delineation of involved spaces, and to the diagnosis of complications (Boscolo-Rizzo et al., 2006). CT imaging could provide the greatest amount of specific information relating to the anatomic location, and the extent of head and neck infections and the spread of odontogenic infections (Nortje and Van Rensburg, 1997). Hegde et al. (2012) states that infections of the head and neck vary in their clinical course and outcome because of the diversity of organs and anatomic compartments involved.

As the retropharyngeal, danger (between alar and prevertebral fascia) and perivertebral spaces extend into the mediastinum, it is imperative to include the upper sections of the

mediastinum in the CT scan coverage. The retropharyngeal and danger spaces extend from the base of the skull into to the mediastinum (up to T2 thoracic vertebral level) and diaphragm respectively, separated from one another by the alar fascia. The infections of the danger space are secondary to spread from retropharyngeal and prevertebral spaces and are difficult to distinguish from those of the retropharyngeal space on CT imaging. Imaging also assists in planning the drainage of abscesses.

According to Flynn (2004), CT imaging is one of the best modalities for post-operative re-evaluation of cervicofacial infection. It can confirm adequate surgical drainage of the involved anatomical spaces by the visualization of the radiopaque drains in the involved spaces can show spread of infection into previously undrained spaces and continued airway swelling. CECT is the radiology examination of choice in the evaluation of deep neck infection. Lateral soft-tissue radiographs of the neck may be helpful in the diagnosis of retropharyngeal abscesses, but they are not beneficial in the workup of patients strongly suspected of having a deep neck infection (Wang, 2003). CECT has a high sensitivity but low specificity, which may lead to an unnecessary operation for some patients if CECT is used in isolation. Therefore, clinical examination and CECT together yield the most accurate result in defining the location, severity, and size of the deep neck abscess. An advantage of CECT is that it can differentiate an abscess from solid mass or cellulitis, which will influence the methods of therapy. Under CECT, an abscess could be identified with the presence of an air-fluid level, subcutaneous air or rim enhancement of the cavity (Wang, 2003).

The CT scan can show both the presence of infection as well as help in finding the cause of the infection. It can also show the presence of foreign bodies, which can be the cause of persistent infections and pus drainage. Examples of common foreign bodies are plates and screws, dental or cosmetic facial implants, knife blades, bullets and shrapnel. Other pathology such as tumours and cysts can become secondarily infected and show abscesses on CT. The CT scan can also show infection of the salivary glands, as well as other glandular pathology. Pathology of the nodes of the head and neck can also be visualised.

Although CECT plays an important role in the diagnosis and management of deep neck abscesses, Smith et al. (2006) note that, despite careful selection criteria a negative exploration rate of nearly 25% can be expected. Wang (2006) states that hypodensities of less than 2 ml in volume with no ring enhancement were less likely to yield pus at the time of

surgery. Al-Noury and Lotfy (2010) state that if an abscess is clearly present, a CT scan usually shows a central, low attenuation region surrounded by an enhanced rim, but a low attenuation centre does not necessarily imply the presence of actual pus. Al-Noury and Lotfy (2010) further note that lymph nodes undergoing early liquefaction and those that have undergone complete liquefactive necrosis can appear as a low attenuation centre on CT.

The treatment of deep neck infection consists of securing the airways, using antimicrobial therapy, and surgical drainage of the abscesses. Early open surgical drainage remains the most appropriate method of treating a deep neck abscess (Huang, 2004). CT guidance can also be used in various interventional procedures e.g. needle aspiration of fluids for microbial analysis, abscess drainage and drain placement (Topazian et al., 2002).

Ultrasonography (US) and MRI are other modalities that can be used in the diagnosis of cervicofacial sepsis. According to Pandey et al. (2011) US is a quick, easily accessible, relatively cheap and painless procedure that can be repeated as often as necessary with no risk to the patient, as it does not use ionizing radiation. It is very effective in detecting the spread of infection to the superficial fascial spaces of the head and neck region as well as in detecting the stage of infection. However, it falls short in detecting the spread of infection to the deep fascial spaces (Bassiony et al., 2009).

Although traditional US cannot distinguish an abscess from surrounding blood vessels, colour Doppler ultrasonography has solved this problem (Yusa et al., 2002) Also, since bone and air act as barriers to the ultrasound beam, US cannot be used to assess the retropharyngeal region and the paranasal sinuses (Pandey et al., 2011). However, the ability of US to show the exact location and dimensions of abscesses in the orofacial area which are unobstructed by bony structures, helps avoid large, unsightly, post-operative facial scars and can often even eliminate the need for hospitalization (Baumash, 1999). Yusa et al. (2002) further support the aforementioned point by stating that the relatively blind surgical incision and drainage of abscesses based on diagnosis by physical examination only, may result in excessive tissue trauma, unnecessarily extensive incisions, additional operating time, pain, and even failure to locate and evacuate the abscess cavity. To avoid such complications, grey-scale US combined with colour Doppler US has been reported to be a useful diagnostic tool for delineating the location and extent of abscess formation (Yusa et al., 2002). Al-Belasy (2005) asserts that

experience has shown that US often eliminates the need for drainage, which would require that the patient undergoes general anaesthesia.

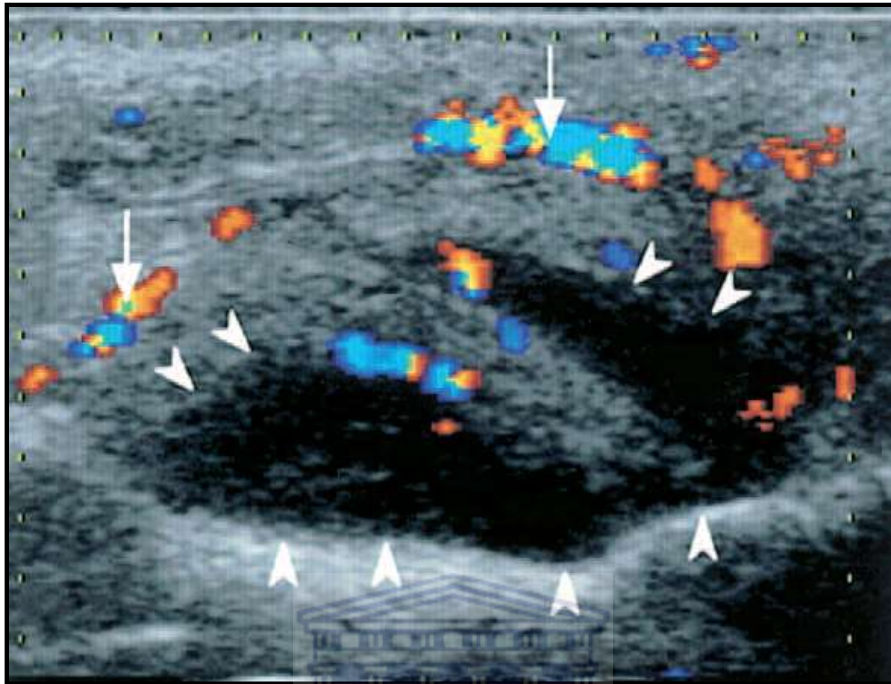


Figure 3. Greyscale US showing an abscess (arrowheads). Facial artery shown by arrows as a colour flow signal (Yusa et al., 2002)

MRI has been used extensively in the evaluation of conditions of the head and neck, but its use has been limited in the evaluation of deep fascial space infections. The major advantages of MRI include the ability to obtain direct images in the coronal and sagittal planes, in addition to the axial plane (Topazian et al., 2002). Topazian et al. (2002) further assert that the ability to get images in the sagittal and parasagittal planes makes it possible to show retropharyngeal and superior mediastinal abscesses in the region of the thoracic inlet, an area that is difficult to show on routine axial CT scans because of artefacts from adjacent bones. The images are also less susceptible to artefacts caused by dental restorations. In addition, the intravenous contrast material used in MRI is less toxic than that used in CT scanning.

MRI has major disadvantages, such as long imaging time and the similar appearance of abscesses and cellulitis on T2 weighted scans which can make distinguishing between the two difficult. Schuknecht et al. (2008), in a study of submasseteric abscesses, showed that when signs of infection are not as prominent, MRI may aid in narrowing the differential diagnosis. MRI may also help to exclude the following lesions that may cause facial swelling:

benign masseteric hypertrophy, venous intramuscular haemangioma, superficial tumour or chronic osteomyelitis.

## **SURGICAL DRAINAGE OF DEEP NECK ABSCESSSES**

Fagan and Morkel (2014) state that neck abscesses can be difficult to drain and have fatal consequences if not timeously diagnosed, accurately localised and promptly incised and drained. With improved diagnostic techniques, widespread availability of antibiotics, and early surgical intervention, the mortality rate has decreased significantly (Huang, 2004).

### **Sublingual space**

This space is drained via an intraoral incision parallel to the submandibular gland duct and lingual cortex, as close as possible to the lingual cortical bone (within 1 cm) in order to avoid injury to the sublingual gland and submandibular duct (Abubaker and Benson, 2001).

### **Submental space**

The submental space is drained extraorally by a transverse incision midway between the symphysis and hyoid bone (Abubaker and Benson, 2001).

### **Submandibular space**

This space is drained through an extraoral incision parallel to the inferior border of the mandible, keeping at least 2 cm below the lower border. This is done in order to avoid injury to the marginal mandibular nerve, facial artery, submandibular gland and lingual nerve (Abubaker and Benson, 2001).

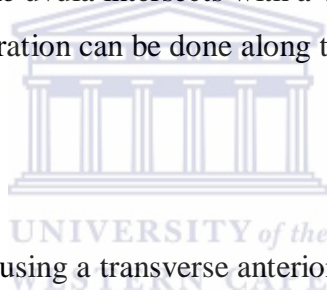
### **Parapharyngeal space**

A prestyloid parapharyngeal abscess can be drained intraorally by incising the lateral pharyngeal wall. An incision is made through the mucosa and dissection directed medially and posteriorly along the medial surface of the medial pterygoid muscle (Abubaker and Benson, 2001). This space can also be drained via a suprahyoid approach (Fagan and Morkel, 2014).

The retrostyloid parapharyngeal space is best approached transcervically at the level of the hyoid bone. A transverse cervical skin incision is made just anterior to the sternocleidomastoid muscle, and subplatysmal flaps elevated to expose the anterior border of the sternocleidomastoid. The investing layer of deep cervical fascia is divided along the anterior border of the sternocleidomastoid, and a finger is passed deep to the posterior belly of the digastric, dissecting bluntly along the carotid sheath up to the tip of the styloid. The parapharyngeal space can also be drained with through-and-through drainage (Abubaker and Benson, 2001).

### **Peritonsillar space**

This is the most commonly involved space of the deep neck spaces with regards to abscesses. These abscesses occur as a result of tonsillar infection and can be treated by needle aspiration, incision and drainage or quinsy tonsillectomy. The aspiration begins where a horizontal line from the base of the uvula intersects with a vertical line through the molar teeth. If this is unsuccessful, aspiration can be done along the vertical line (Fagan and Morkel, 2014)



### **Pretracheal space**

Pretracheal abscesses are drained using a transverse anterior skin crease cervical incision (Fagan and Morkel, 2014).

### **Retropharyngeal space**

This space can be drained transorally or transcervically. Transoral drainage involves an incision through the posterior pharyngeal wall mucosa, and opening the abscess with blunt dissection. The transcervical approach is via an incision parallel to and along the anterior border of the sternocleidomastoid muscle below the level of the hyoid bone. The muscle and the carotid sheath are retracted laterally, and a finger is inserted posterior to the inferior constrictor (Abubaker and Benson, 2001).

### **Danger space**

Drainage of the danger space is achieved by a transcervical approach along the anterior border of the sternocleidomastoid muscle, dissecting between the larynx and the carotid sheath. The superior thyroid artery may have to be divided in order to improve access (Fagan and Morkel, 2014).

### **Carotid space**

Drainage is via a transverse cervical skin crease incision with elevation of subplatysmal flaps superiorly and inferiorly for exposure. Anticoagulant drugs must be used in order to prevent clot propagation and pulmonary emboli (Fagan and Morkel, 2014).

### **Prevertebral space**

Drainage may be done via transoral or transcervical approaches. The transcervical incision is made along the anterior border of sternocleidomastoid, dissecting between the larynx and the carotid sheath. The superior thyroid artery may have to be divided in this case as well in order to improve access (Fagan and Morkel, 2014).



## **CHAPTER 3**

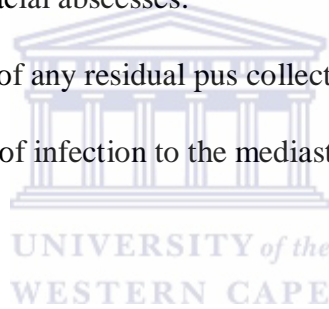
### **AIMS AND OBJECTIVES**

#### **AIM**

The aim of this study was to correlate radiological findings with fascial space drainage in the management of severe cervico-facial infection.

#### **OBJECTIVES**

1. To assess the correct anatomical placement of surgical drains during incision and drainage of deep cervicofacial abscesses.
2. To ascertain the presence of any residual pus collection in the cervicofacial region.
3. To assess possible spread of infection to the mediastinum or deep neck.



#### **NULL HYPOTHESIS**

Postoperative CT scan imaging has no value in the management of severe cervicofacial infections.



## CHAPTER 4

### MATERIALS AND METHODS

#### STUDY DESIGN

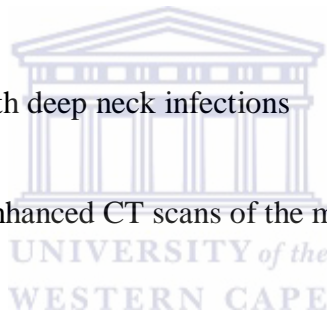
This is an analytical retrospective case series of post-operative CT scans taken during the management of cervicofacial abscesses at Tygerberg Academic Hospital.

#### STUDY POPULATION

The following inclusion and exclusion criteria were used in case selection:

##### Inclusion criteria

- (a) Post-operative patients with deep neck infections
- (b) Surgical drains in situ
- (c) Availability of contrast enhanced CT scans of the maxillofacial region, including the neck and chest



##### Exclusion criteria

- (a) Uncontrasted CT scans
- (b) No surgical drains in situ
- (c) Radiolucent surgical drains

#### STUDY SIZE

A total of thirteen patients were included in the study after consideration of the inclusion and exclusion criteria.

#### STUDY INSTRUMENTS

Informed consent for the contrast enhanced CT scan and surgical procedures was obtained from each patient.

All the patients included in the study were managed according to the deep fascial space surgical protocol. All patients were clinically assessed and documented using the standard maxillo-facial and oral surgical examination form. Routine special examinations were performed which included full blood count, urea and electrolytes (U&E), blood sugar and HIV testing using standard hospital informed consent protocols for each procedure. A pantomograph was taken of each patient. Clinical diagnoses were made and affected fascial spaces were noted. An intravenous catheter was placed and each patient began an empiric antibiotic protocol i.e. penicillin G, 5 MU and 500 mg of metronidazole IVI. Patients allergic to penicillin were given 600 mg of clindamycin with metronidazole IVI.

### **Anaesthetic and surgical protocol**

The airway was assessed by the operating surgeon and specialist anaesthetist. The patient was intubated transnasally with or without a tracheostomy or an awake tracheostomy was performed where required. Affected fascial spaces were drained and radio-opaque surgical drains were placed as per surgical protocol. Pus was sent for microscopy, culture and sensitivity (MCS).

### **Post-operative protocol**

All patients had an intravenous catheter placed for the administration of the contrast medium and the surgical drains remained in situ. The CT scans were taken using a Siemens 40 slice multidetector CT scanner (Siemens, Erlangen, Germany), starting from the brain down to the mediastinum and chest/lungs. The contrast medium was Ultravist 300 Iopromide (Bayer, Whippany, New Jersey, USA).

All information was entered onto the data capture sheet (Annexure 4).

### **DATA COLLECTION AND ANALYSIS**

Data were collected regarding the presence of abscesses, their location, the location of surgical drains and the presence of other pathology (Annexure 4). The data were entered onto an Excel spreadsheet and analyzed using the EPI-INFO statistical computer package. Frequency distribution of all the variables was assessed as well as association between different variables. The relevant data are represented by means of pie charts or frequency bar graphs or in the form of tables.

## **ETHICS**

An information sheet was provided to all participants (Annexure 1). Consent was also obtained from prospective participants (Annexure 2). Confidentiality was ensured and steps taken to ensure that the names and contact details of the participants would not be divulged. The participants were allowed to opt out of the study at any time. It was guaranteed that the consent or refusal of patients to participate would not affect their future treatment needs at the Tygerberg Maxillo-Facial and Oral Surgery Department. The participants bore no costs relating to the study. Since CT scans are a necessary part of the routine treatment of severe cervicofacial infections, patients were not being exposed to extra or unnecessary radiation. The radiation exposure was also within safe limits as per Department of Health guidelines. Permission to conduct the research was obtained from the Ethics Committee of the University of the Western Cape.

## **DECLARATION OF INTEREST**

The researcher has no commercial or associative interest that represents a conflict of interest in connection with the study or materials used.



## CHAPTER 5

### RESULTS

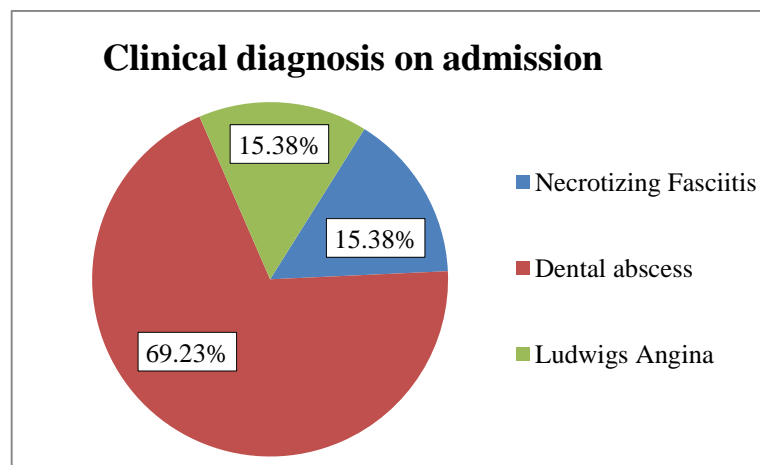
#### Demographic information

The study sample contained 13 patients with ages ranging from 23-56 years, with an average age of 37.3 years. Of the 13 patients, six were male and seven female. Details are depicted in Table 1.

Patient	Age	Sex	Clinical Diagnosis
1	56	F	Necrotizing Fasciitis
2	30	F	Ludwig's Angina
3	51	M	Necrotizing Fasciitis
4	45	M	Dental abscess
5	47	F	Dental abscess
6	23	M	Dental abscess
7	30	F	Dental abscess
8	24	M	Dental abscess
9	34	F	Dental abscess
10	36	F	Ludwig's Angina
11	38	M	Dental abscess
12	28	M	Dental abscess
13	43	F	Dental abscess

**Table 1: Demographic information and clinical diagnosis**

Clinical diagnoses are depicted in Figure 4.



**Figure 4: Clinical diagnosis of sample on admission**

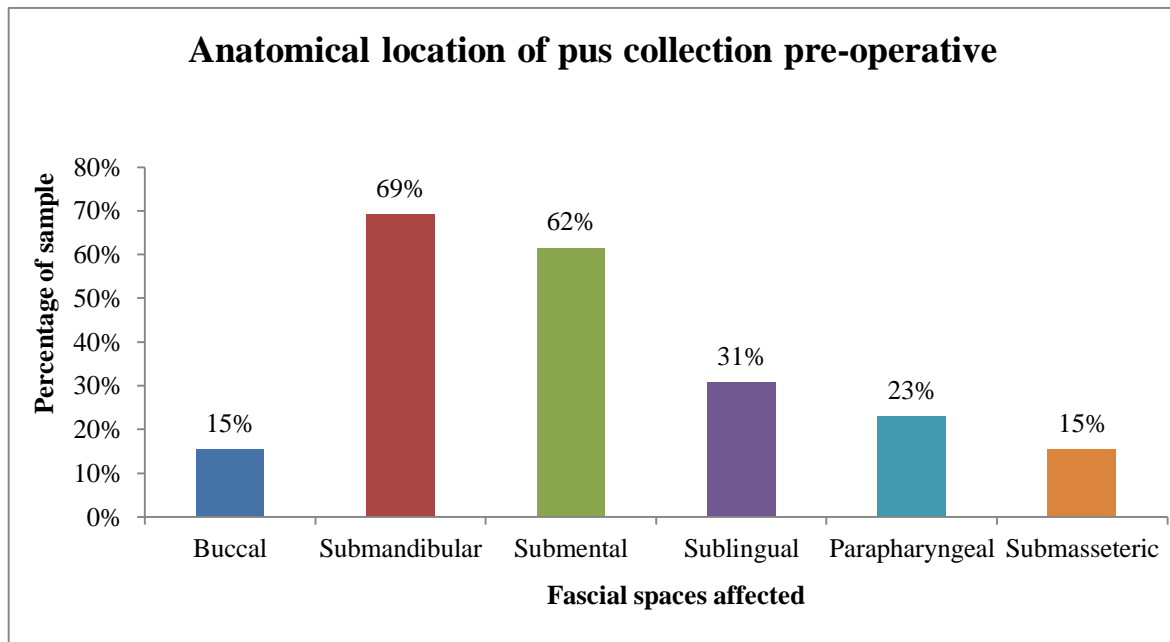
### **Fascial Spaces affected on admission**

The fascial spaces that were clinically affected before imaging was performed are depicted in Table 2. The anatomical locations of pre-operative pus collections as a percentage of total number of patients are depicted in Figure 5.

<b>Patient</b>	<b>Spaces Affected</b>
1	Submental, Submandibular, Buccal
2	Submental, Submandibular, Sublingual
3	Submental, Submandibular, Parapharyngeal
4	Parapharyngeal
5	Submasseteric, Parapharyngeal
6	Submandibular
7	Buccal
8	Sublingual, Submental
9	Submental, Submandibular
10	Sublingual, Submental, Submandibular
11	Sublingual, Submandibular
12	Submental, Submandibular, Submasseteric, Canine
13	Submental, Submandibular, Submasseteric, Temporal

**Table 2: Fascial spaces affected on admission**

Almost a quarter of the patients had only one space affected at the initial clinical examination. Almost half had two spaces affected and slightly less than a third had three spaces affected. Almost half had both submandibular and submental spaces affected. The submandibular space was the most common (69%) and the submental space second most common (62%) initially affected space.



**Figure 5: Anatomical locations of pre-operative pus collections as a percentage of total number of patients**



### **Medical history**

A patient was regarded as healthy in the absence of any pre-existing medical condition. Slightly more than half (54%) of the patients were healthy. Almost a third (31%) disclosed that they were HIV positive (RVD) on admission. From the entire sample, 10 patients gave consent for a HIV test from which half tested positive. One patient suffered from diabetes and two patients had hypertension.

### **Laboratory results**

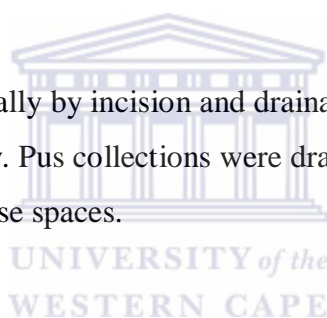
A full blood count and urea, creatinine and electrolyte laboratory tests were conducted on all the patients prior to surgery.

Test	Mean (Standard Deviation)	Normal range
White blood cell count	19.29 (9.06)	4 - 10
Hb	12.42 (1.94)	17 - 17.5
Red blood cell count	3.98 (0.55)	4.5 - 5.8
Platelets	389.58 (196.45)	137 - 373
K	4.48 (0.93)	3.5 - 5.0
Na	138.5 (4.15)	135 - 147
HGT	7.56 (3.54)	4.0 - 5.9
Creatinine	57.55 (24.39)	64 - 104

**Table 3: Mean values of laboratory results**

### **Surgical treatment**

All patients were managed surgically by incision and drainage. Furthermore, the majority (84.62%) required a tracheostomy. Pus collections were drained from the affected spaces and surgical drains were placed in those spaces.



### **Post-operative CT scans and surgical drains placed in situ**

All the patients had a post-operative CT scan after surgery and the mean time lapse between the CT and surgery was 2.61 days (SD = 1.56). In the majority (69.23%) of post-operative scans residual pus collections were detected.

In slightly more than a quarter of the patients, no residual pus collection could be detected on the postoperative CT scan while in half of the patients; affected fascial spaces were missed by the surgeon. These spaces included the submasseteric, anterior mediastinum and parotid spaces. Spaces where surgical drains were placed in situ but which still showed pus collection on the post-op CT scans were the buccal, parapharyngeal and sublingual spaces. Spaces which were completely drained of pus were the submental and submandibular spaces.

<b>Patient</b>	<b>Spaces Affected</b>	<b>Location (spaces) of collections on post-operative scan</b>
1	Submental, Submandibular, Buccal	
2	Submental, Submandibular, Sublingual	Sublingual, Masticator, Parapharyngeal
3	Submental, Submandibular, Parapharyngeal	Anterior Mediastinum
4	Parapharyngeal	Retropharyngeal
5	Submasseteric, Parapharyngeal	Submasseteric
6	Submandibular	No collection
7	Buccal	Buccal
8	Sublingual, Submental	Sublingual
9	Submental, Submandibular	
10	Sublingual, Submental, Submandibular	Parapharyngeal
11	Sublingual, Submandibular	Masticator, Parotid
12	Submental, Submandibular, Submasseteric, Canine	Buccal
13	Submental, Submandibular, Submasseteric, Temporal	No collection

**Table 4: Comparison of clinical pre-operative pus collections and post-operative pus collections as viewed on CT scan**



### **Repeat incision and drainage**

Almost half (44.15%) the patients required a repeat incision and drainage.

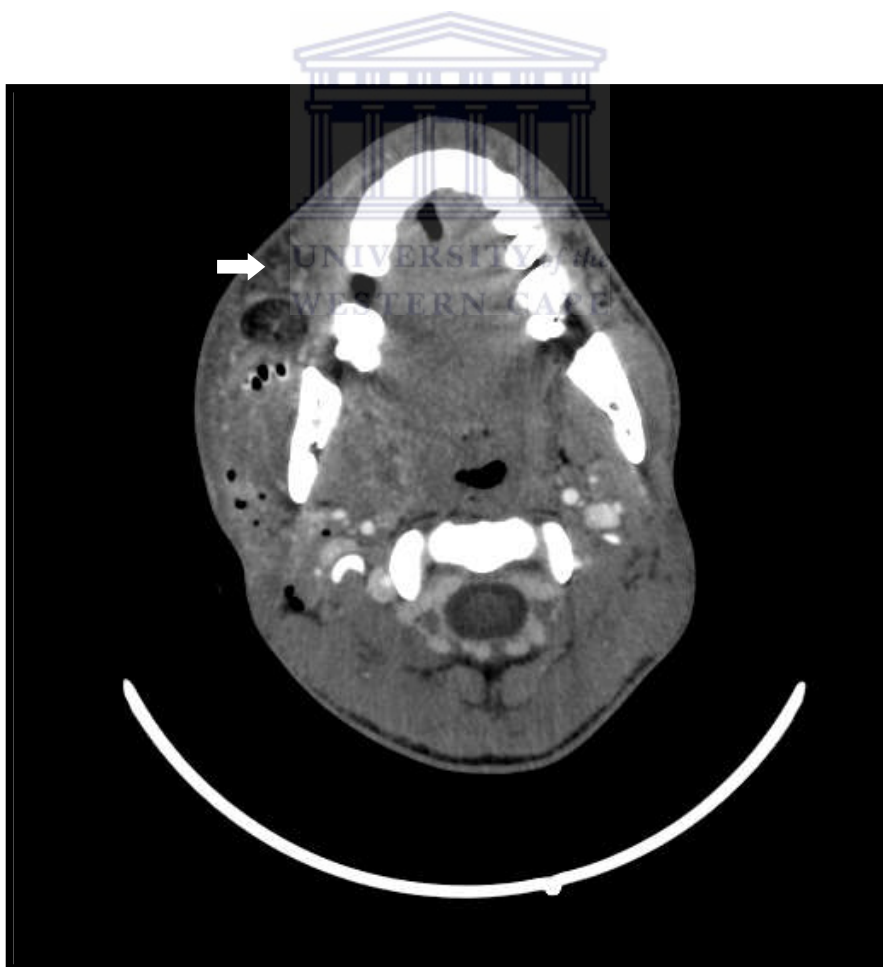
### **Drains in situ vs. location of collections on post-operative CT scans**

<b>Nr</b>	<b>Anatomical location</b>		
	<b>Surgical drain in situ</b>	<b>Pus collection on post-op CT</b>	<b>Spaces missed</b>
1	Submental, Submandibular, Buccal	No collection	
2	Submental, Submandibular	Sublingual, Masticator, Parapharyngeal	Masticator, Parapharyngeal
3	Submental, submandibular, Parapharyngeal	Anterior Mediastinum	Anterior Mediastinum



4	Parapharyngeal	Retropharyngeal	Retropharyngeal
5	Parapharyngeal	Submasseteric	Submasseteric
6	Submandibular	No collection	
7	Buccal	Buccal	
8	Submental, sublingual	Sublingual	
9	Submental, Submandibular		
10	Submental, Submandibular, Sublingual	Parapharyngeal	Parapharyngeal
11	Submandibular, Sublingual	Masticator, Parotid	Masticator, Parotid
12	Submandibular, Sublingual, Submasseteric, Canine	Buccal	Buccal
13	Submental, Submandibular	No collection	

**Table 5: Surgical drains in situ compared to pus collection detected on postoperative CT scans**



**Figure 6: A post-operative CT scan image showing a buccal space pus collection (arrow)**

## CHAPTER 6

### DISCUSSION

In this study, young to middle aged adults were the most commonly affected by cervicofacial infection, and there was no significant gender predilection. The majority of the patients were from low socioeconomic groups. A study by Agarwal et al. (2007) found that socioeconomic factors, particularly ignorance, illiteracy, and poverty, are important contributory factors towards the high incidence of deep neck abscess in developing countries. Larawin et al. (2006) also found that low socioeconomic conditions, which lead to poor orodental hygiene, were responsible for the high incidence of odontogenic causes of deep neck space infections in their patients.

In the current study, the most common clinical diagnosis noted on admission was a dental abscess involving the fascial spaces of the neck. This is consistent with the finding that all the patients in this study had at least one carious tooth on presentation; with the latter diagnosed as the etiological factor in all cases. This finding is supported by observations by Sethi and Stanley published in 1994. It was further noted that after the introduction of antibiotics into clinical medicine, and routine management of throat infections by antimicrobial therapy, dental infections and regional trauma were now seen as the most common causes of deep neck infections (Sethi and Stanley, 1994). A study by Huang (2004) reiterated the finding that odontogenic infection was the most common cause of deep neck infections. It is interesting to note that the majority of the deep neck infections before the advent of antibiotics originated in the pharynx and tonsils and not from odontogenic origin (Sethi and Stanley, 1994).

In the current study, the most commonly affected space was the submandibular space (69%) and in most patients, the offending tooth was a lower mandibular molar. The scientific literature would support this finding that the lower molars were the most likely source of infection in submandibular space infection (Abubaker and Benson, 2001). The second most commonly affected space was the submental space. The aforementioned finding can be attributed to the anatomical connection between the two spaces and that infections can easily spread between the two spaces i.e. from the submandibular space to the submental space, and

vice versa. The sublingual space, which was the third most commonly affected space, also communicates with the submental and submandibular spaces. Ten of the patients (76.9%) had more than one space affected. The latter can be explained by the often late presentation of the cases and the tendency of abscesses to spread to adjacent anatomical fascial spaces.

More than a third (38.5%) of the patients in the current study were HIV positive, and potentially immunocompromised. One patient had uncontrolled diabetes, which compromised the immune system. The patient presented with necrotizing fasciitis involving three fascial spaces. Chang et al. in 2013 also found that the prognosis of diabetic patients are poorer than that of non-diabetic patients in deep neck infections since they have greater incidence rates of involved fascial spaces, abnormal haematologic findings and post-surgical complications. These patients often required an additional procedure, such as tracheostomy. A consistent finding in the study was an elevated leukocyte count, with a mean of 19.29 cells per microliter.

A majority of the patients had tracheostomies performed at the initial surgery. The indications for the tracheostomies were airway compromise in most cases and in some as a precautionary measure due to limited access to ICU beds. The establishment of airway security followed by aggressive surgical drainage of all anatomical spaces affected by sepsis, together with antibiotic therapy and medical supportive care, are the cornerstones of reducing mortality in cervicofacial sepsis (Flynn, 2004).

In just more than half (7/13) of the patients, some of the affected fascial spaces were clinically missed and these spaces were therefore not drained during the initial surgical procedure. These findings were made on post-operative CECT. Most of these patients underwent a follow-up surgical drainage procedure. Pre-operative CECT scans were not possible due to the long waiting time associated to emergency CECT scans at Tygerberg Academic Hospital; the latter waiting time could not be accommodated in patients with critical airway compromise. Several authors, Flynn (2004), Fagan and Morkel (2014), Topazian et al. (2002), have unequivocally stated the value of CT scans in the detection of deep neck space infection.

It was interesting that some spaces (44%) with drains in situ still showed some pus collection on the CECT scans. This was probably due to continuous pus production as a result of

persistent infection, or a result of inadequate postoperative wound irrigation. The causes of treatment failure in the management of odontogenic infections are inadequate surgical drainage, depressed host defenses, presence of foreign bodies, and antibiotic-related problems such as patient non-compliance, incorrect antibiotic prescription and low antibiotic dosage (Flynn, 2004).



## CHAPTER 7

### CONCLUSION

The majority of studies in the scientific literature analyses and discusses the use of preoperative CT scans in odontogenic infections involving the fascial spaces of the deep neck. This study, though small, does demonstrate the value of postoperative CT scans in the management of cervicofacial infections, especially in cases where pre-operative CT scans were not possible due to logistical reasons. This study further advances the argument for acquisition of preoperative CECT scans for all patients with severe cervicofacial infections.



## REFERENCES

- Abubaker, A.O. and Benson K.J. (2001). *Oral and Maxillofacial Secrets*. 1<sup>st</sup> ed. Philadelphia: Hanley and Belfus Inc.
- Agarwal, A.K., Sethi, A., Sethi, D., Mrig S. and Chopra S. (2007). Role of socioeconomic factors in deep neck abscess: A prospective study of 120 patients. *British J of Oral and Maxillofac Surg*, 45: 553–555.
- Al-Belasy, F.A. Ultrasound-Guided Drainage of Submasseteric Space Abscesses. (2005). *J Oral Maxillofac Surg*, 63:36-41.
- Al-Noury, K. and Lotfy A. (2010). Deep neck spaces radiology and review of deep neck infections at King Abdulaziz University Hospital. *Egyptian J Ear Nose Throat and Allied Sciences*, 11: 69-74.
- Bassiony, M., Yang J., Abdel-Monem, T.M., Elmogy, S. and Elnagdy, M. (2009). Exploration of ultrasonography in assessment of fascial space spread of odontogenic infections. *Oral Surg Oral Med Oral Pathol Oral Radiol Endod*, 107(6): 861 - 869.
- Baurmash, H.D. (1999). Ultrasonography in the diagnosis and treatment of facial abscesses. *J Oral Maxillofac Surg*, 57:635-636.
- Boscolo-Rizzo, P., Marchiori, C., Zanetti, F., Vaglia, A., and Da Mosto, M.C. (2006). Conservative management of deep neck abscesses in adults: The importance of CECT findings. *Otolaryngology -- Head and Neck Surgery*, 135: 894-899.
- Chang, J-S., Yoo, K-H., Yoon, S.H., Ha, J., Jung, S., Kook, M-S., Park, H-J., Ryu, S-Y. and Oh, H-K. (2013). Odontogenic infection involving the secondary fascial space in diabetic and non-diabetic patients: a clinical comparative study. *J Korean Assoc Oral Maxillofac Surg*, 39:175-181.

Fagan, J. and Morkel, J.A. (2014). Surgical drainage of deep neck abscesses. In *Open Atlas of Otolaryngology, Head and Neck Operative Surgery*. Available from:

<https://vula.uct.ac.za/access/content/group/ba5fb1bd-be95-48e5-81be586fbaeba29d/Surgical%20drainage%20of%20deep%20neck%20abscesses.pdf>

[Accessed 13 June 2014]

Flynn, T.R. (2004). In: M. Miloro, ed. *Peterson's Principles of Oral and Maxillofacial Surgery*. 2<sup>nd</sup> Edition. London: BC Decker Inc., 277-293.

Hegde, A.N., Mohan, S., Pandya, A. and Shah, G.V. (2012). Imaging in Infections of the Head and Neck. *Neuroimag Clin N Am*, 22: 727–754.

Hoang, J.K., Branstetter, B.F., Eastwood, J.D. and Glastonbury, C.M. (2011). Multiplanar CT and MRI of Collections in the Retropharyngeal Space: Is It an Abscess? *Am J Radiol*, 196: 426-432.

Huang, T-T., Liu, T-C., Chen, P-R., Tseng, F-Y., Yeh, T-H., and Chen, Y-S. (2004). Deep neck infection: Analysis of 185 cases. *Head Neck*, 26: 854–860.

Larawin, V., Naipao, J. and Dubey, S.P. (2006). Head and neck space infections. *Otolaryngology–Head and Neck Surgery*, 135: 889-893

Lee, C., Fattahi, T. and Caldwell, G. (2003). Neuroimaging of neck pathology. *Atlas Oral Maxillofac Surg Clin N Am*, 11: 55-72.

Nortje, C.J. and Van Rensburg, L.J. (1997). Practical insights into the imaging of odontogenic lesions. *Advances in Maxillofacial Imaging*, IADMFR/CM: 27-34.

Pandey, P.K., Umarani, M., Kotrashetti, S. and Baliga, S. (2011). Evaluation of ultrasonography as a diagnostic tool in maxillofacial space infections. *J Oral Maxillofac Res*, 2(4): e4.


Schuknecht, B., Stergiou, G. and Graetz, K. (2008). Masticator space abscess derived from odontogenic infection: imaging manifestation and pathways of extension depicted by CT and MR in 30 patients. *Eur Radiol*, 18: 1972-1979.

Sethi, S.D. and Stanley, R.E. (1994). Deep neck abscesses - changing trends.

*The Journal of Laryngology and Otology*, 108: 138-143.

Smith, J.L., Hsu, J.M. and Chang, J. (2006). Predicting deep neck space abscess using computed tomography. *American Journal of Otolaryngology – Head and Neck Medicine and Surgery*, 27: 244–247.

Topazian, R.G., Goldberg, M.H. and Hupp, J.R. (2002). *Oral and Maxillofacial Infections: Diagnostic Imaging of Maxillofacial and Fascial Space Infections*. 4<sup>th</sup> Edition. Philadelphia: W.B. Saunders Company.



Wang, L.F., Kuo, W.R., Tsai, S.M. and Huang, K.J. (2003). Characterizations of Life-Threatening Deep Cervical Space Infections: A Review of One Hundred Ninety-Six Cases. *American Journal of Otolaryngology*, 24(2): 111-117.

Yusa, H., Yoshida, H., Ueno, E., Onizawa, K. and Yanagawa, T. (2002). Ultrasound-guided surgical drainage of face and neck abscesses. *Int J Oral Maxillofac Surg*, 31: 328-330.



**ANNEXURE 1**



UNIVERSITY of the  
WESTERN CAPE

**Department of Maxillo-Facial and Oral Surgery  
Faculty of Dentistry and WHO Oral Health Collaborating Centre  
University of the Western Cape  
Cape Town**

**Patient Information Letter**

I, Dr Y Ngcwama (currently a qualified dentist enrolled in a specialist training program), plan to conduct a clinical study in order to ascertain the value of CT scans (this is a type of advanced and computerised X-ray) taken after the initial drainage of severe abscesses of the face and neck. These scans are part of the routine treatment of severe face and neck abscesses in order to assess the adequacy of treatment and are common practice. You will not be exposed to extra or unnecessary radiation.

All patients will undergo a clinical examination, radiographic examination and surgery as per normal procedure. Surgery will include drainage of the abscess, placement of surgical drains and securing of the airway.

Your help with the study will assist all South African hospitals to make better treatment decisions in the future and decrease the length of hospital stay.

Participating in the study is on a voluntary basis. You may withdraw from the study at any time. Refusing to participate will not harm or prejudice you in any way. All information will be kept strictly confidential and will be stored safely.

Thanking you in anticipation.

Dr Y Ngcwama (Researcher)  
Registrar (Maxillo-Facial and Oral Surgery)  
Department of Maxillo-Facial and Oral Surgery  
Oral Health Centre Tygerberg  
Contact details: Tel: (021) 9373119  
Mobile: 0827852736

If you want any more information, you are welcome to contact my supervisor, Prof Morkel, at: [jamorkel@uwc.ac.za](mailto:jamorkel@uwc.ac.za) or 021 9373087

I, (patient name)....., fully understand the information supplied to me by Dr Yanga Ngcwama in the above information letter.

Signature: .....

Date.....

**ANNEXURE 2**



UNIVERSITY of the  
WESTERN CAPE

**Department of Maxillo-Facial and Oral Surgery  
Faculty of Dentistry and WHO Oral Health Collaborating Centre  
University of the Western Cape  
Cape Town**

**Consent form**

I, Mr/Mrs/Miss .....Date of Birth: .....  
File no./Hosp. Sticker

am willing to participate in the study as described to me in the patient information letter by Dr Y Ngcwama. I understand that participation in the study is voluntary.

The study is approved by the Ethical and Research Committee of the University of the Western Cape and participation in this study is on a voluntary basis. I have been adequately informed about the objectives of the study. I also know that I have the right to withdraw from the study at any stage which will not prejudice me in any way regarding future treatments. My rights will be protected and all my details will be kept confidential. No personal information will be published.

I hereby consent to be part of the research/study.

Patient's/patient's parent or guardian's name: .....

Patient's/patient's parent or guardian signature: .....

Witness name:.....

Witness signature:.....

Researcher's signature: .....Dr Yanga Ngcwama

Date: .....

### ANNEXURE 3



UNIVERSITY OF THE WESTERN CAPE

FACULTY OF DENTISTRY

**PATIENT CONSENT TO CLINICAL PHOTOGRAPHY  
AND VIDEO RECORDINGS**



Surname:	Date of Birth:
Name:	Gender:

I, ..... hereby consent to photographs or video recordings being taken of me/my child as requested, I understand that these photographs and recordings will be stored appropriately, treated with the utmost confidentiality and be part of my dental record. I hereby give consent for the images or recordings to be used ONLY for the boxes I have indicated with a tick (✓):

- Record purposes and for my/my child's future management**  
The photographic images and recordings will form part of the information collected for you or your child's care and treatment. This information is handled in accordance with the HPCSA Booklet 14: Guidelines on the keeping of patient records.
  - Education and training purposes**  
The photographic images and recordings may be used for teaching purposes and viewed by health professionals outside of the UWC Faculty of Dentistry. The images may be used for example, in talks, conference presentations, posters or on the Internet to help train other health professionals in the management of dental and oral diseases
  - Approved research purposes & publication**  
This may involve the photographic images and recordings being used for example in medical or dental publications, journals, textbooks, conference material, e-publications and on the Internet. Images will be seen by health professionals and researchers who use the publications in their professional education. The images may be seen by the general public. Images will not be used with identifying information such as name, however, full confidentiality is not guaranteed.
  - Other purposes (please specify):** .....
- I understand that all efforts will be made to conceal my/my child's identity but that full confidentiality cannot be guaranteed.
  - I understand that my consent or refusal will in no way affect my /my child's dental care.

Patient Signature: ..... Date: .....

Parent/Guardian (if patient under 18 years) Name: .....

Signature..... Date: .....

Child assent (7-17 years): ..... Date: .....

Witness Name & Signature..... Date: .....

**ANNEXURE 4**

**RECORD NUMBER:**

**DATA CAPTURING SHEET**

**PATIENTS NAME:**

**HOSPITAL STICKER:**

**HOSPITAL NUMBER:**

**AGE:**

**GENDER:**

**MEDICAL HISTORY AND EXAMINATION:**

**Immuno-compromised (circle): Yes or No**

**Clinical diagnosis and spaces affected:**

**FBC:**

**U&E:**

**HGT:**

**HIV:**

**PAN:**

**Other applicable information:**

.....  
.....

**DATE OF SURGICAL PROCEDURE:**

**Type of surgical procedure done:**

**Location of spaces drained (list):**

**Location of surgical drains placed (list):**

**Surgeon felt all spaces were drained (circle): Yes or No**

**Comments:**

.....  
.....

**POSTOPERATIVE CT SCAN DATE:**

**Presence of pus collections (circle): Yes or No**

**Location of pus collections (list):**

**Location of surgical drains (list):**

**Comments:**

.....  
.....

**Other pathology (list):**

**Radiology report:**